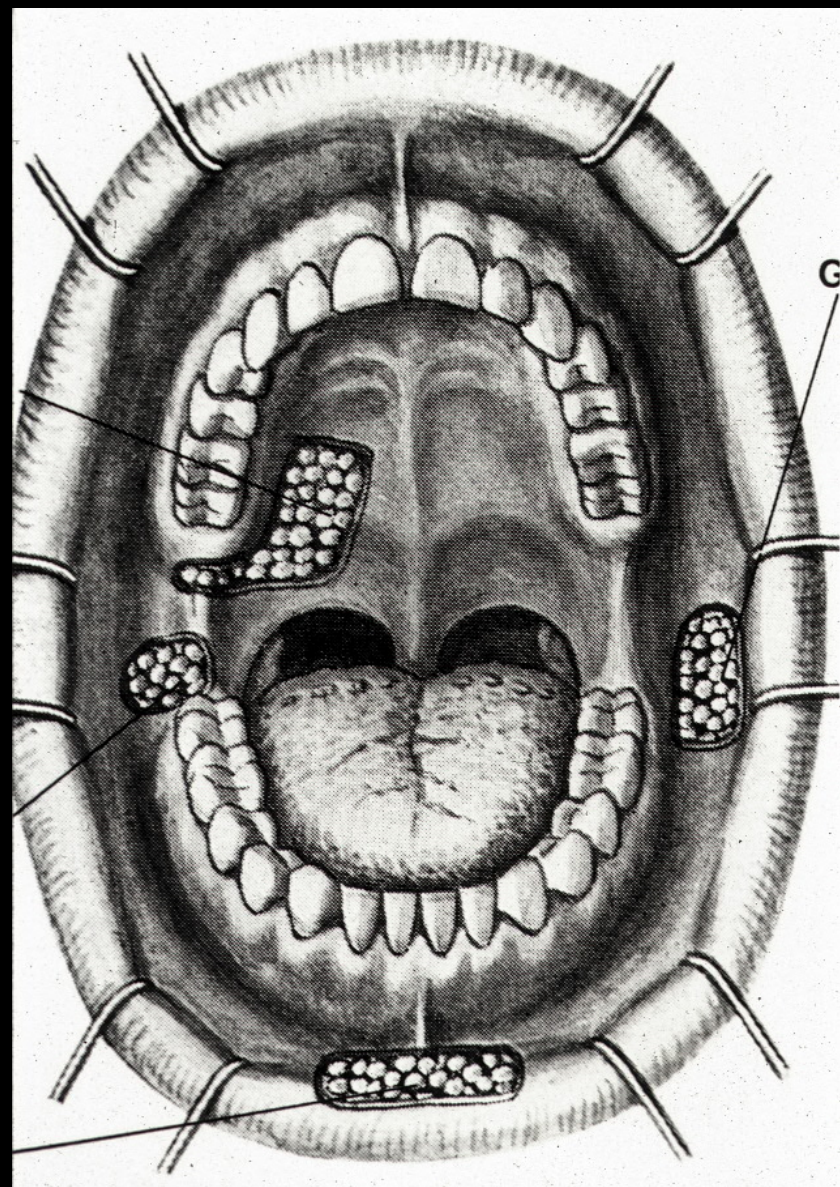
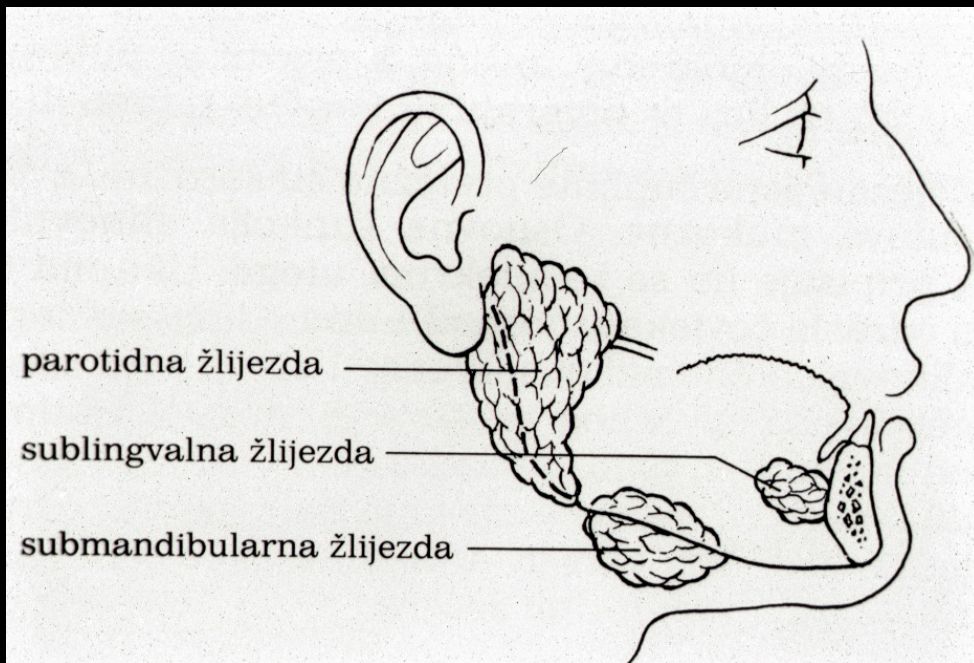


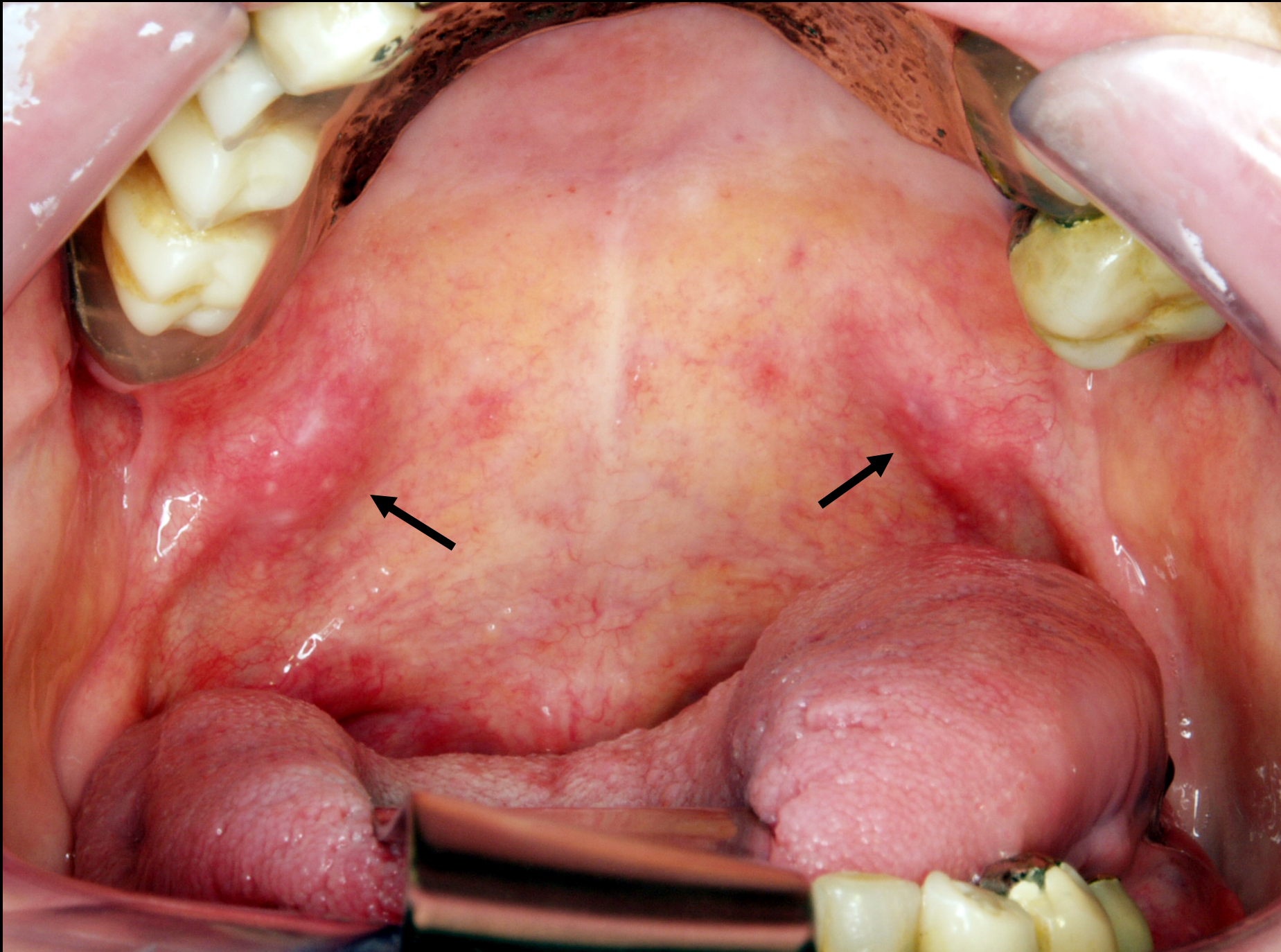
# KIRURŠKA PATOLOGIJA ŽLIJEZDA SLINOVNICA

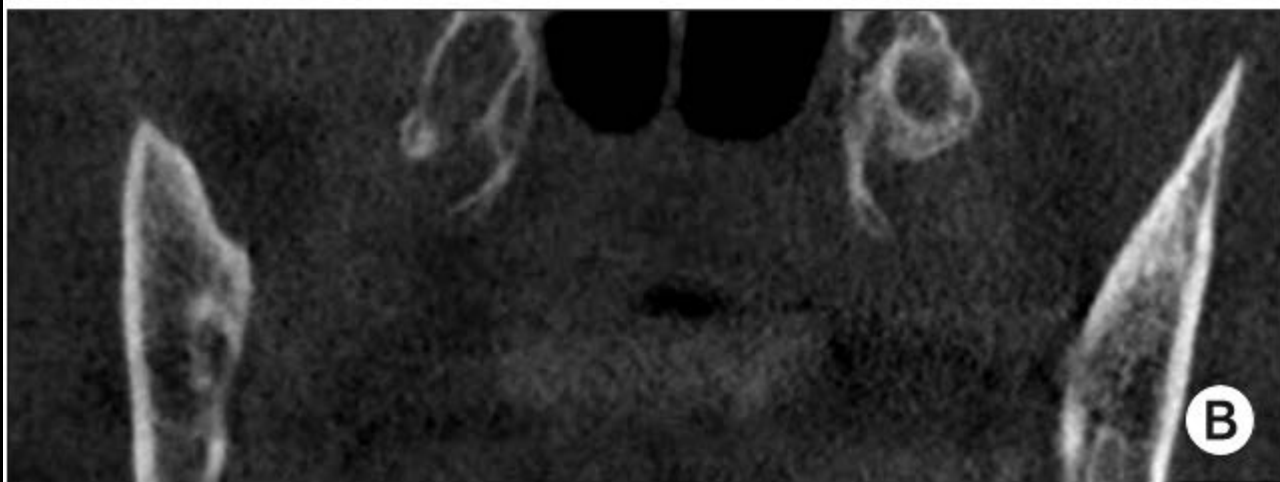
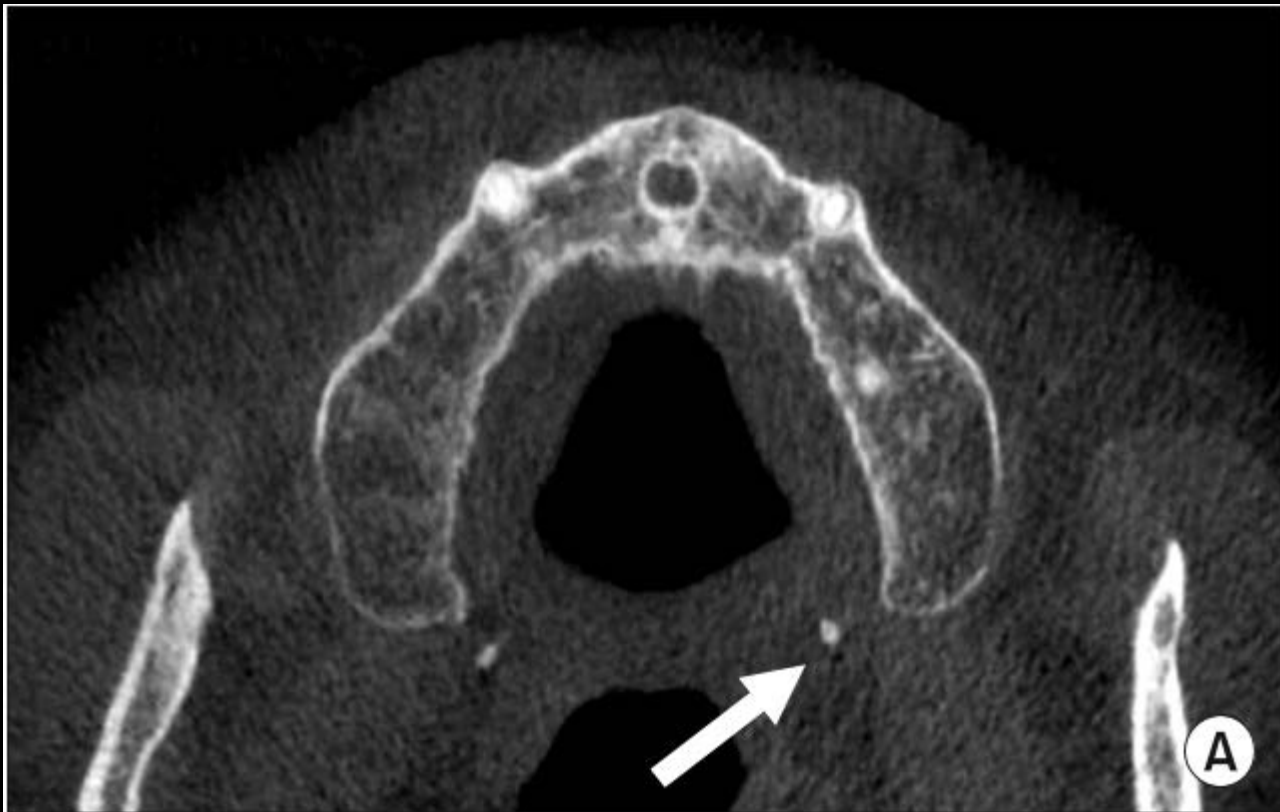Darko Macan

Klinika za kirurgiju lica, čeljusti i usta  
Stomatološkog fakulteta, Klinička bolnica Dubrava

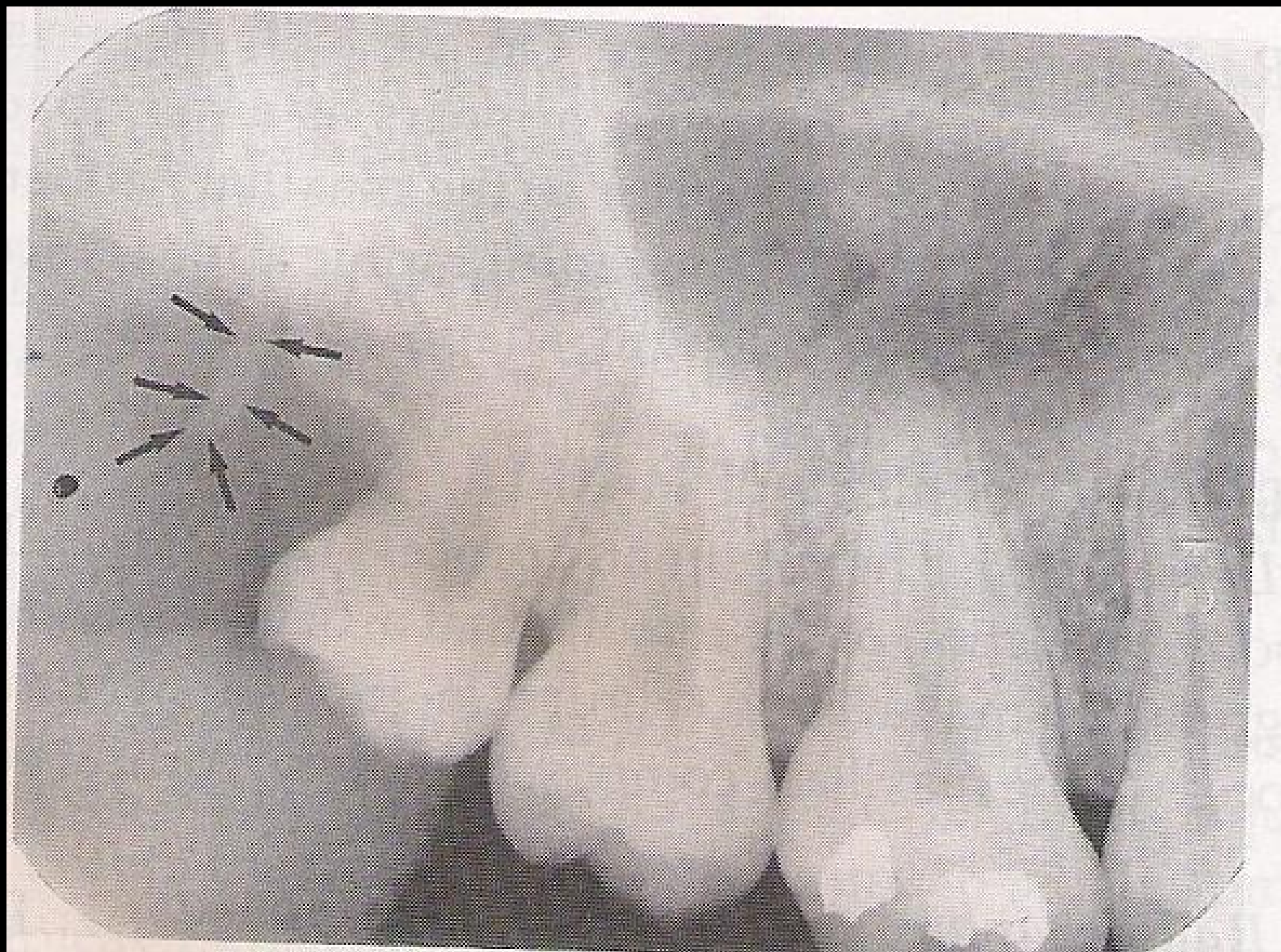






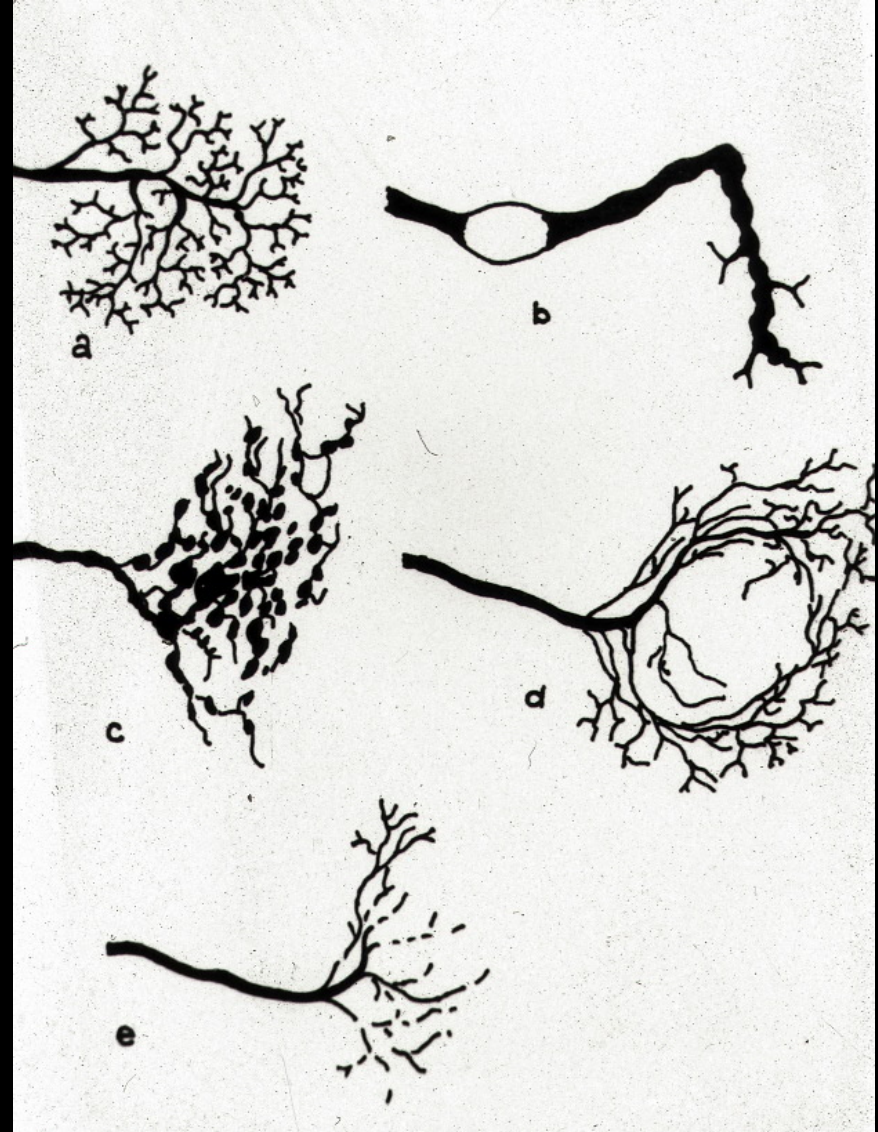


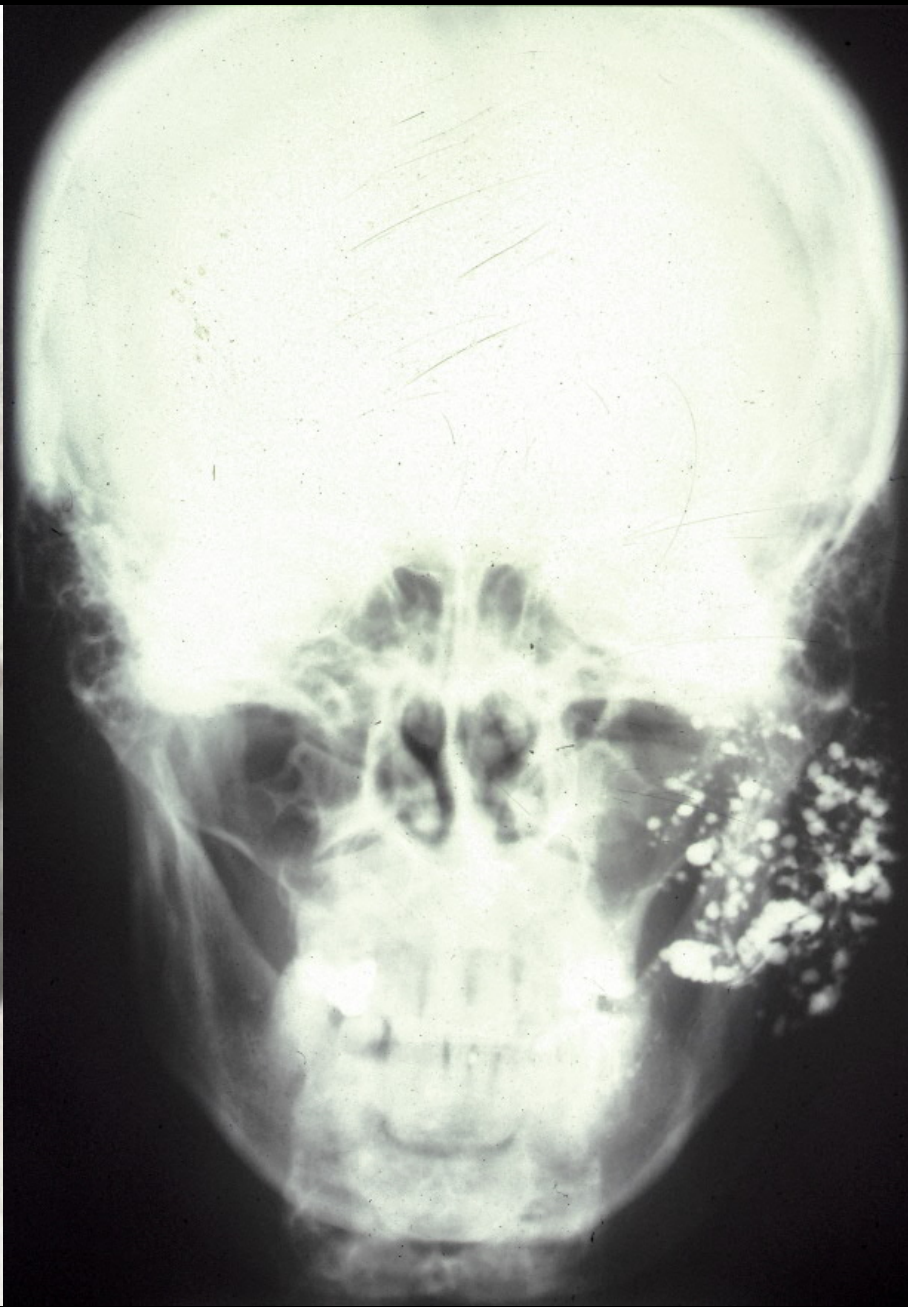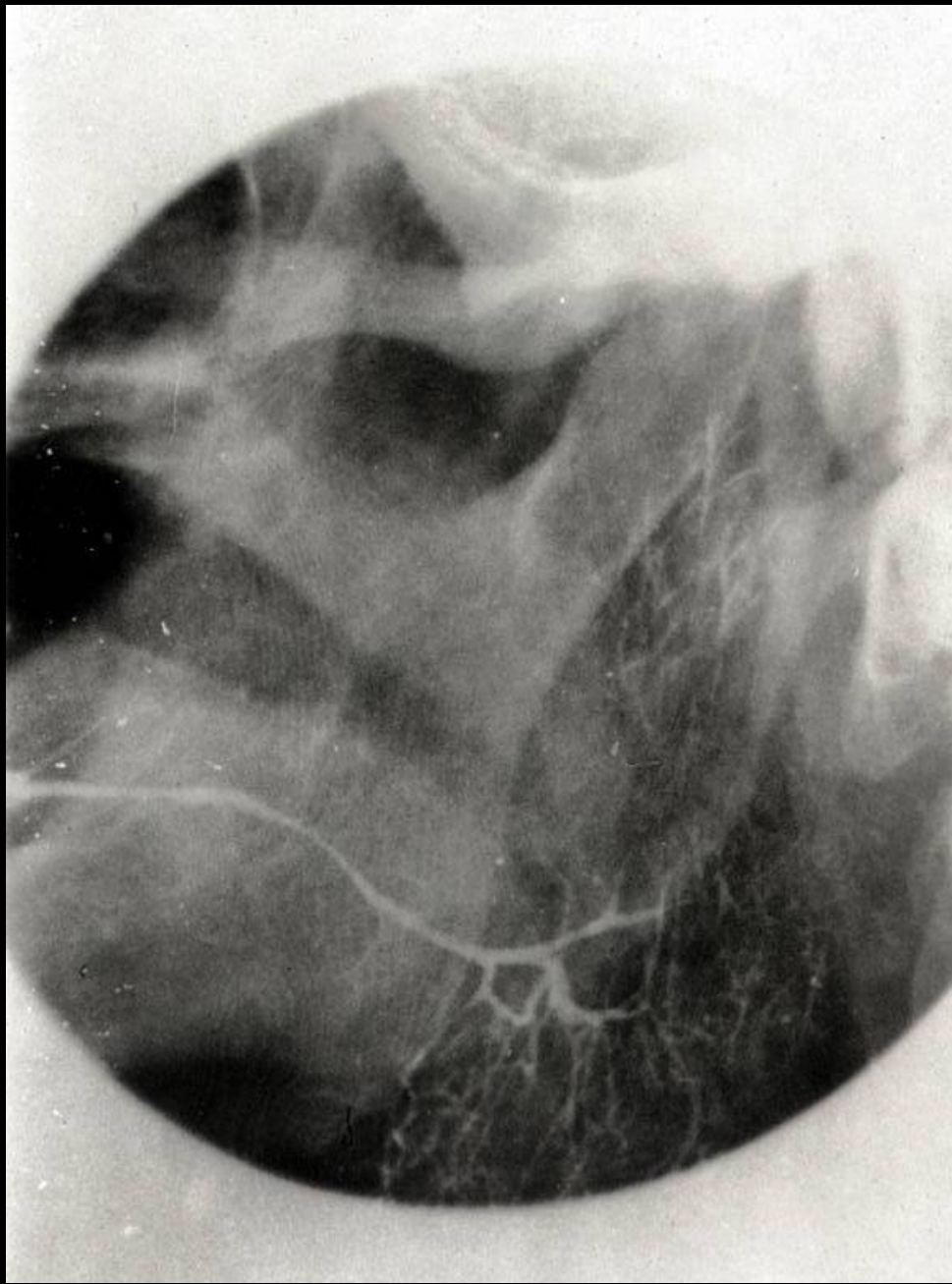


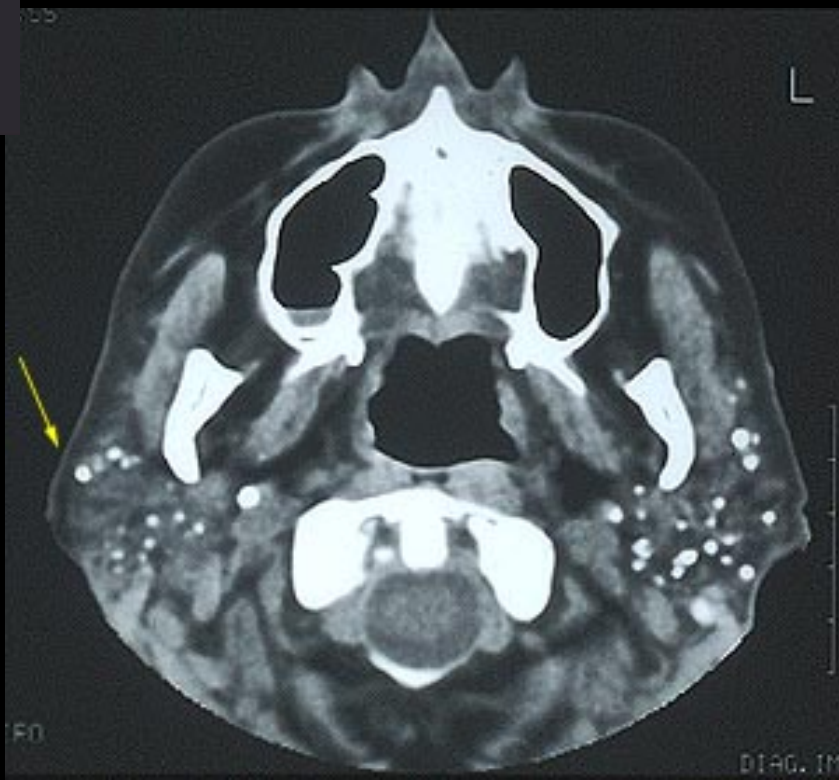
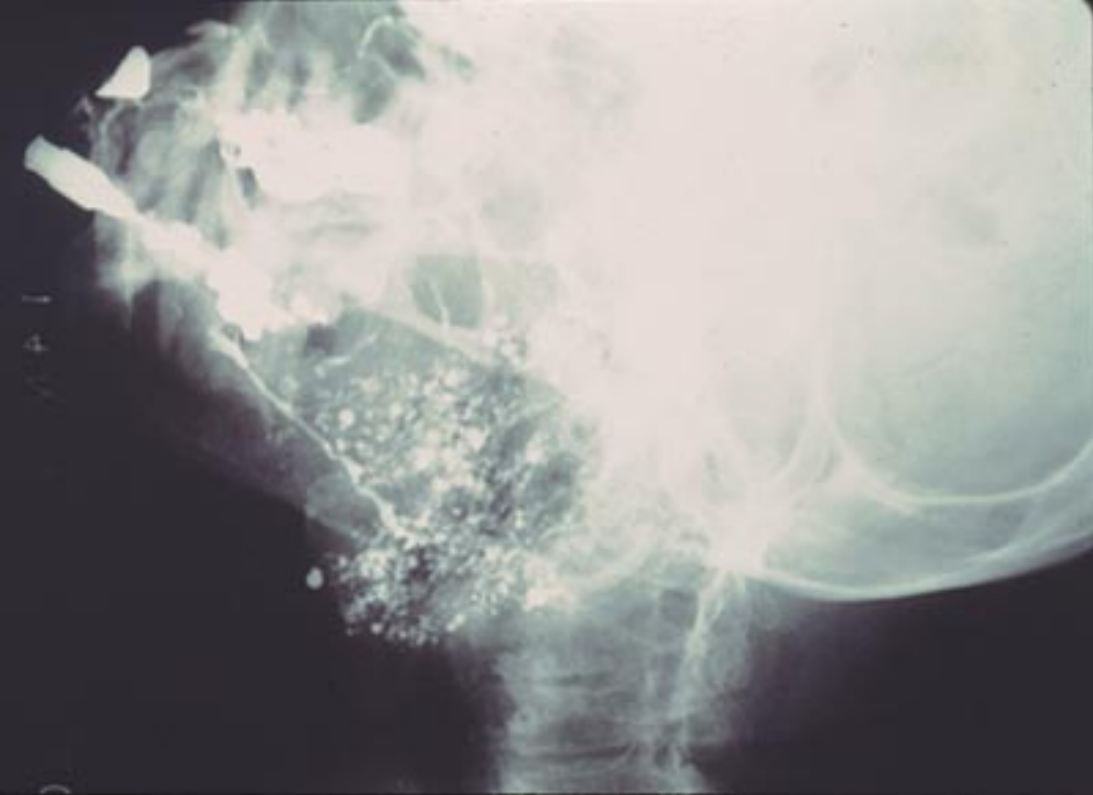# DIJAGNOSTIKA

- ANAMNEZA (lučenje sline, bol, oteklina)
- PREGLED (inspekcija, palpacija – oteklina, stanje papile, pareza)
- RTG – sijalografija, CT, scinfigrafija, UZ
- CITOLOGIJA
- PHD

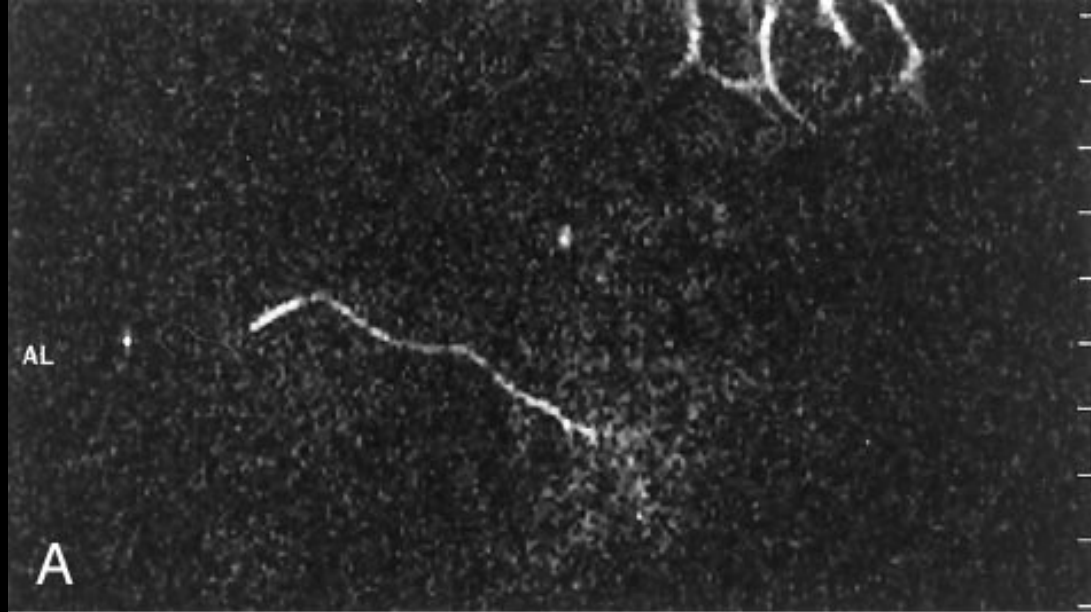



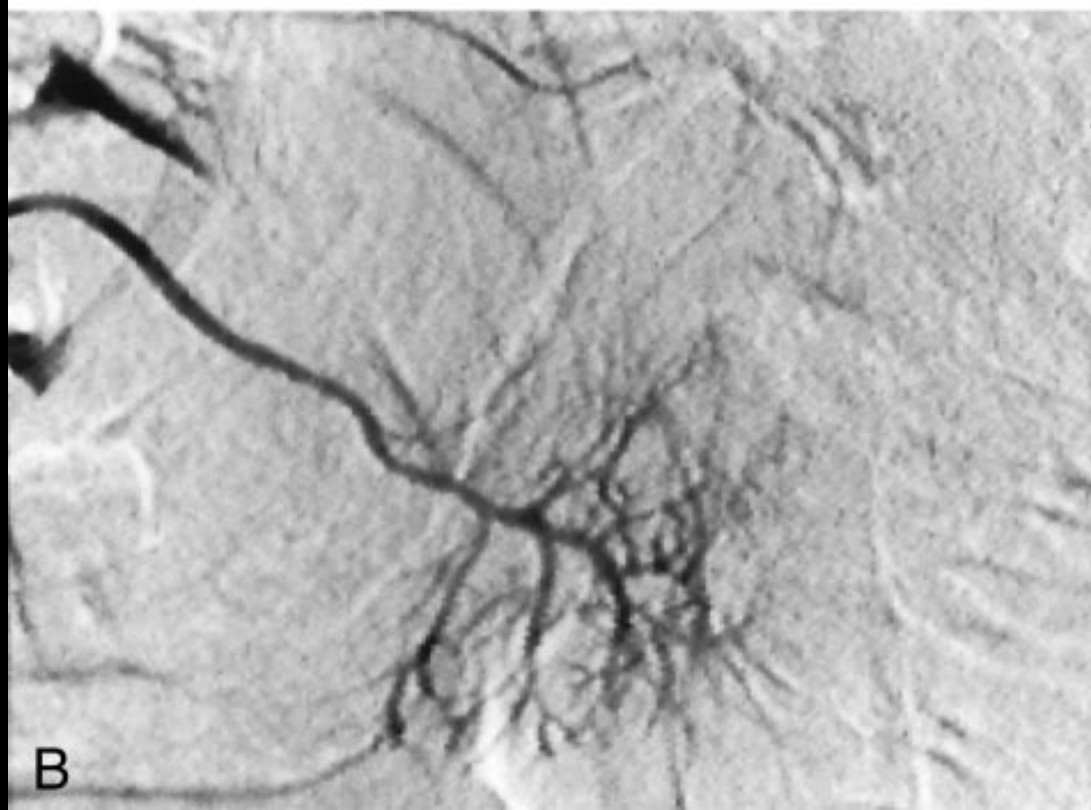




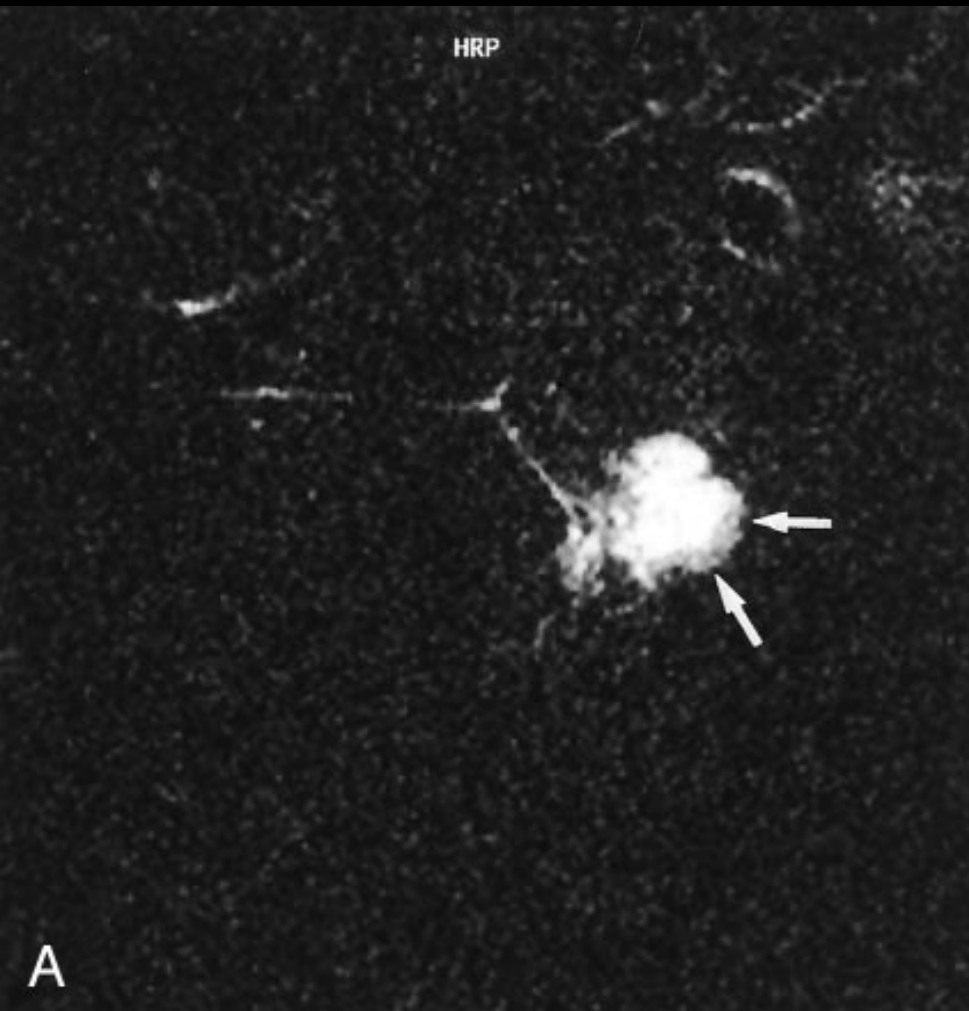




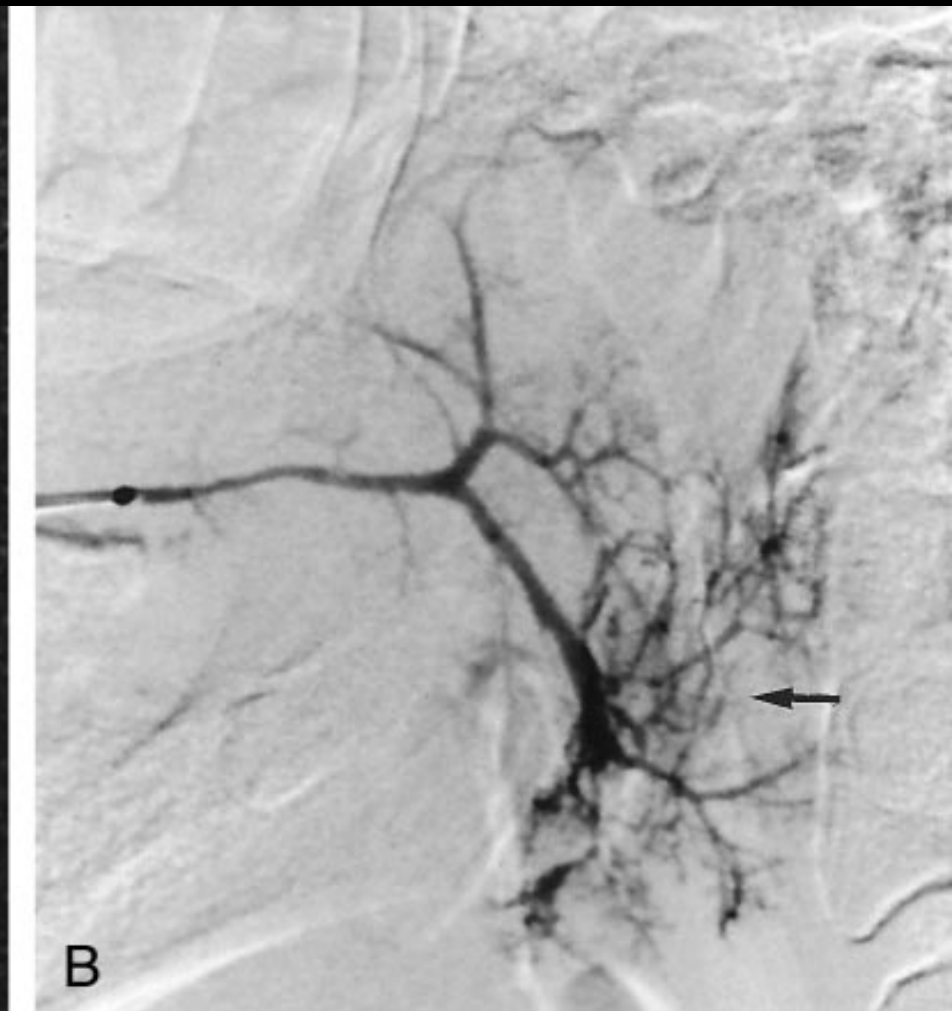MR sijalografija



Digitalna subtrakcijska  
sijalografija

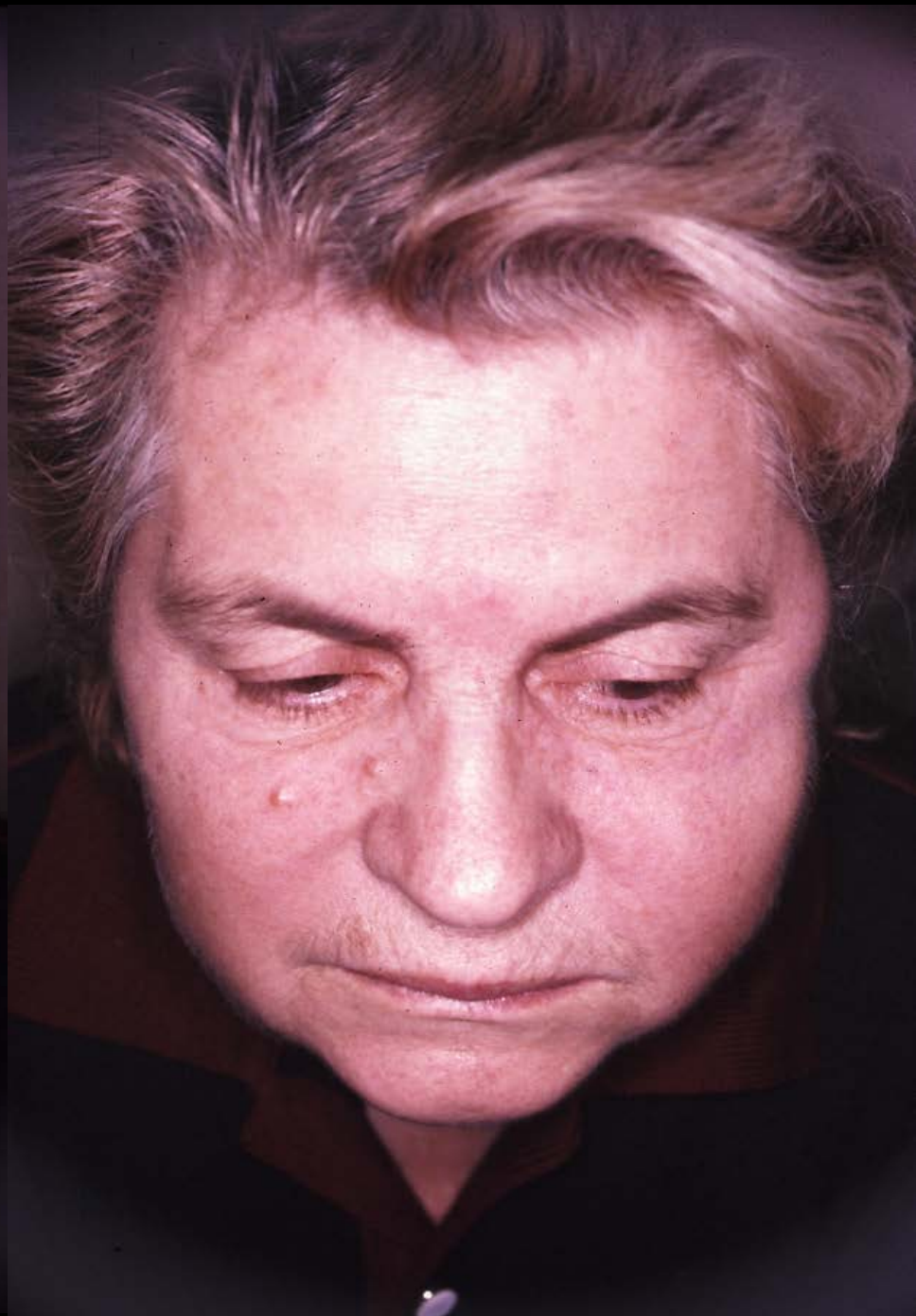
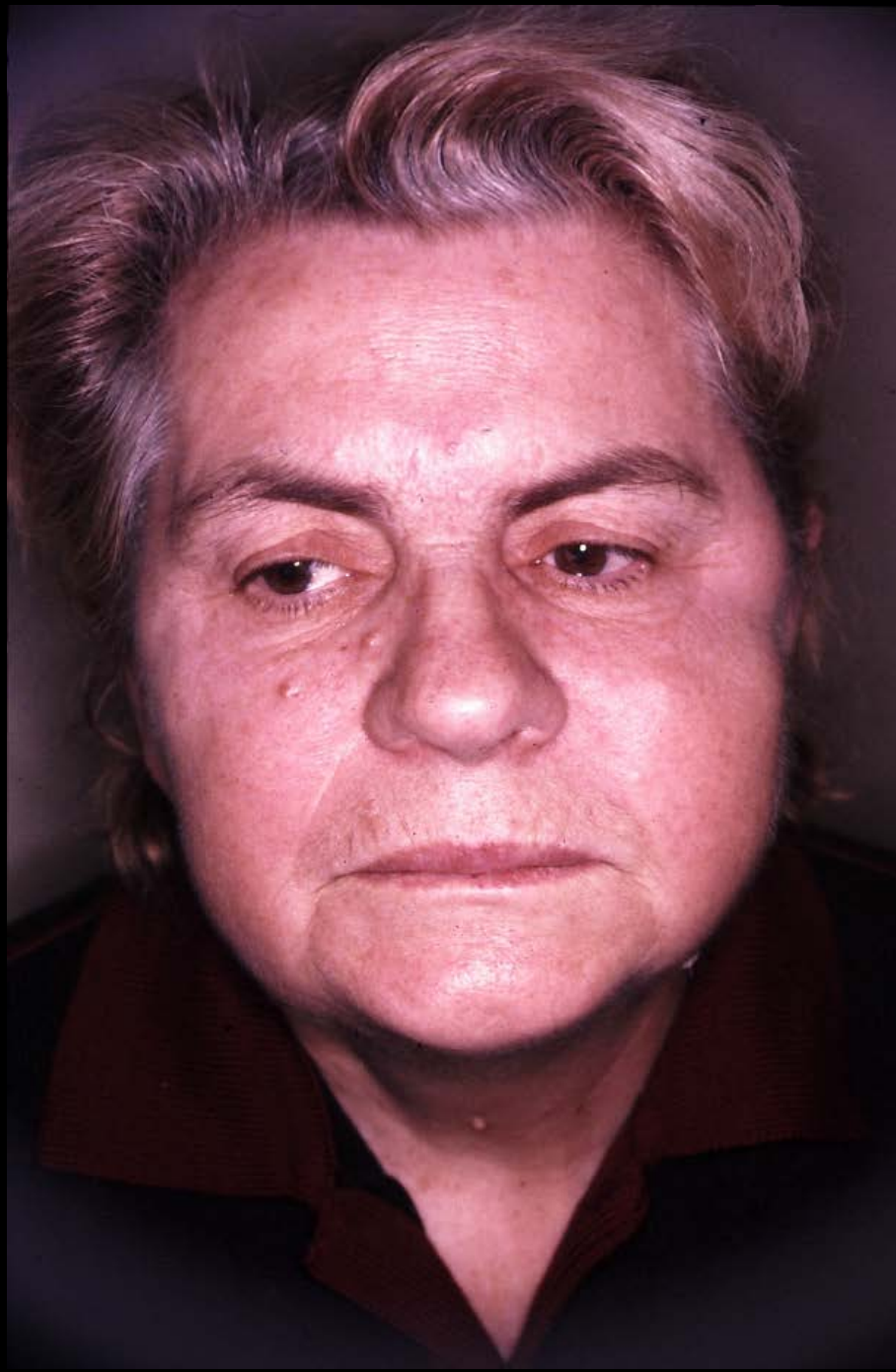
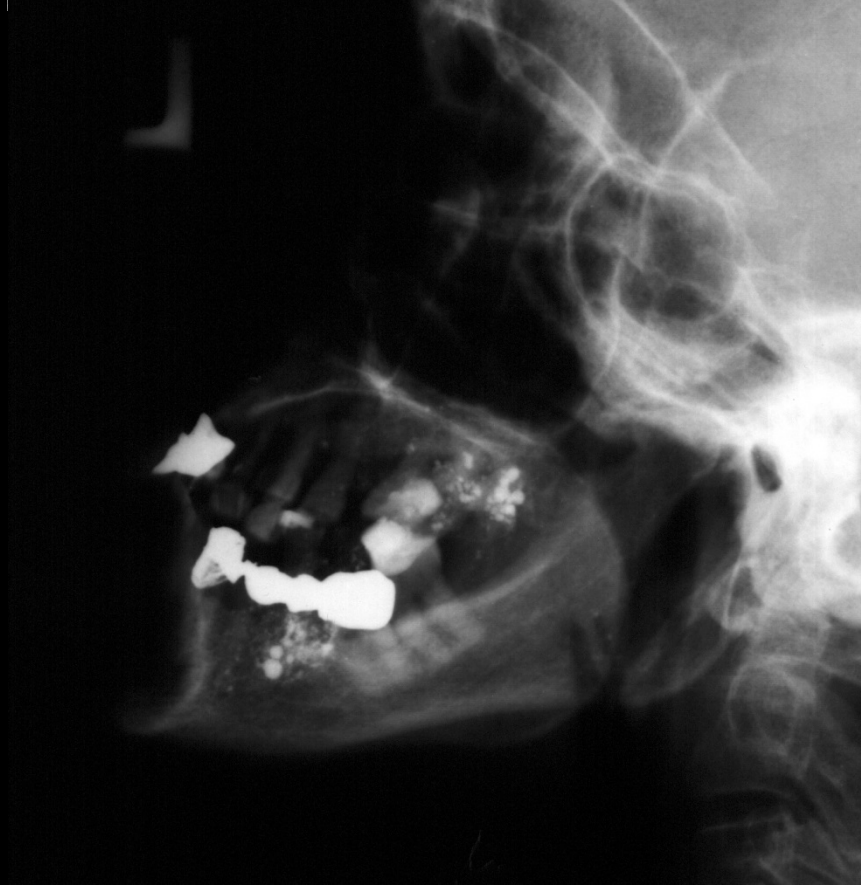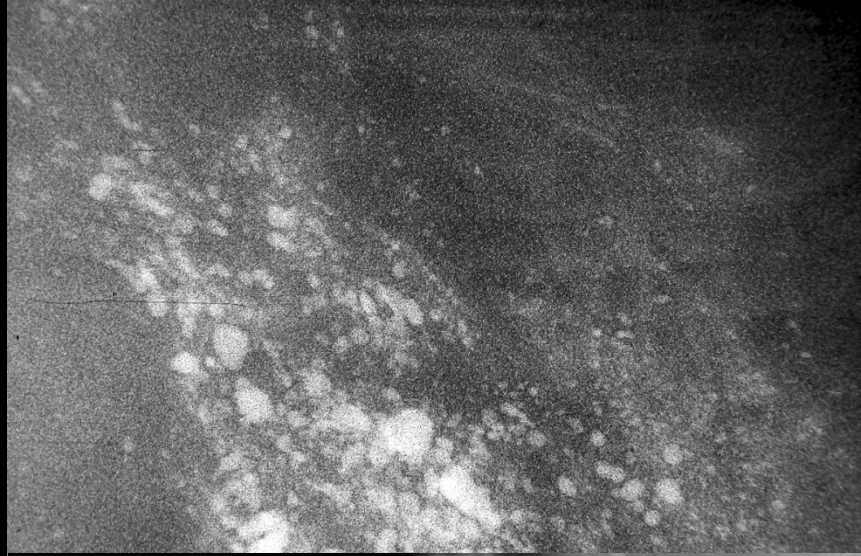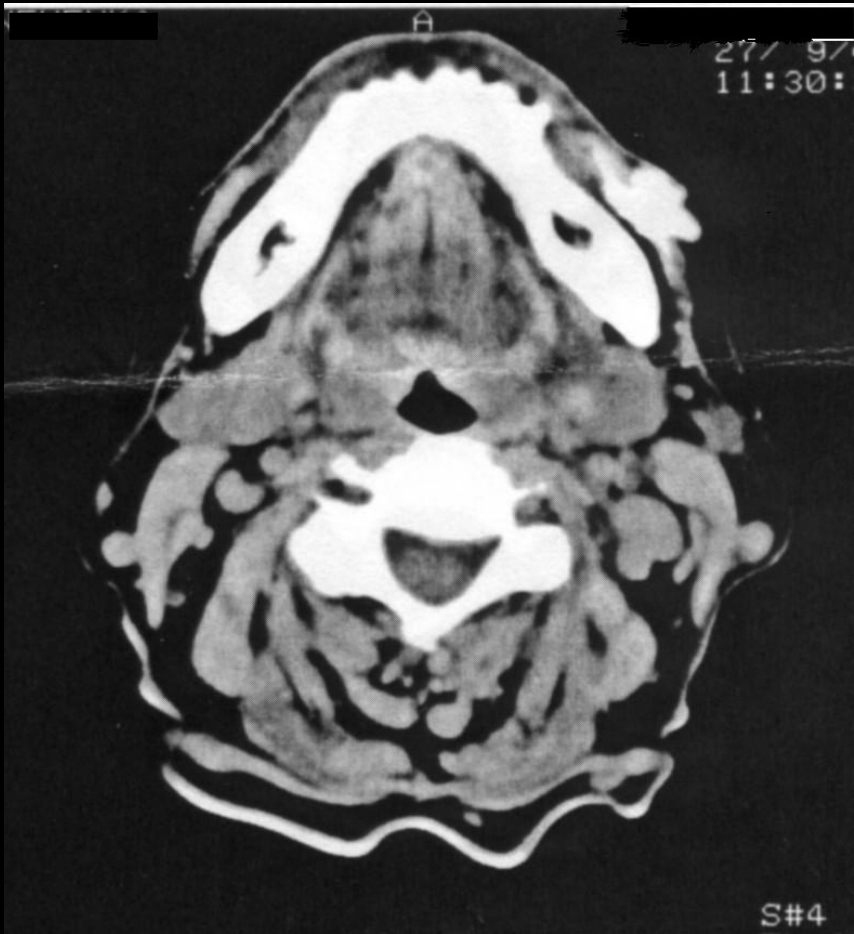MR sijalografija



Digitalna subtraksijska sijalografija







8.71:23:17.00.S1.400S  
2004.12.02 17:35:50  
7423. 2. 1.  
Ultravist 3  
120kV 250  
1.5s 37.0  
2.0mm 37.0  
1.25 37.0  
275mA  
20ml  
00.23.4

+ C

R  
×1.23  
DR HAT  
MR  
ing.Operai M.  
00.23.4

mm40  
OS=Y=30  
T-7800X

7141  
A M B  
F7070Y  
+63.0mm  
-19.5deg  
IH9

2004.12.02 17:35:50  
7450. 2. 1.  
Ultravist 3  
120kV 250  
1.5s 37.0  
2.0mm 37.0  
1.25 37.0  
275mA  
20ml  
00.23.4

+ C

RF3  
Stand  
D=204mm  
X=0 Y=2  
SCT-7800X  
KB Dubrava

27/ 97  
11:30:

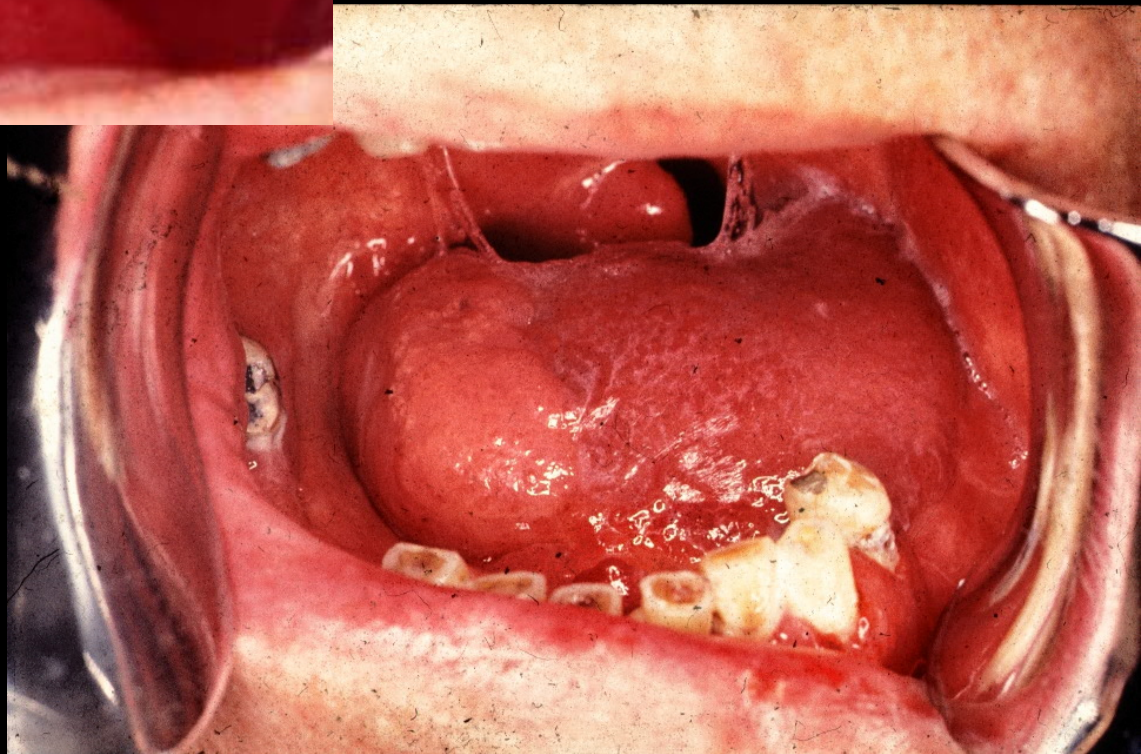
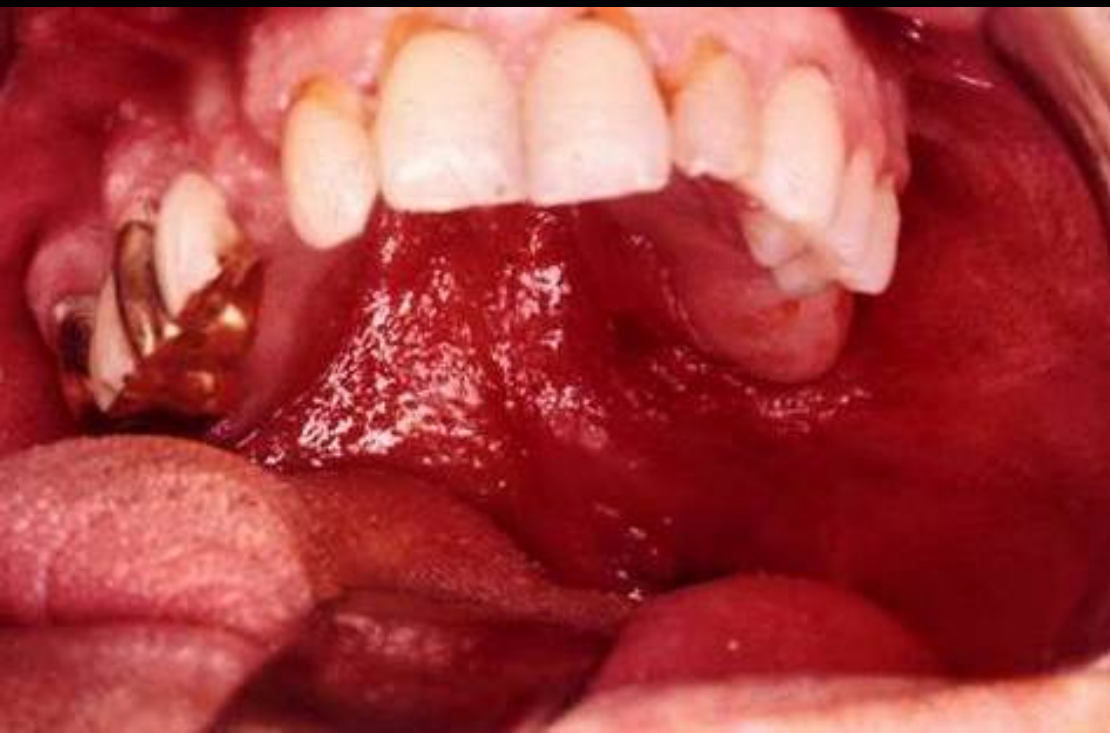L  
1.  
DR H  
M  
opel 1  
W: 2  
L:

S#4



# FUNKCIJSKI POREMEĆAJI

- SIALOREJA (Sialorrhoea, Ptyalismus) – akutna upala, afte, EPI, SCH, trudnoća, trovanje živom, nasljedno, “drooling” – debilitet - pareza facialisa
- HIPOSIALIJA – reverzibilne promjene, parotitis, anemija, nuspojava lijekova, simptomi kronične upale, BLL, sialoadenoze, zračenje



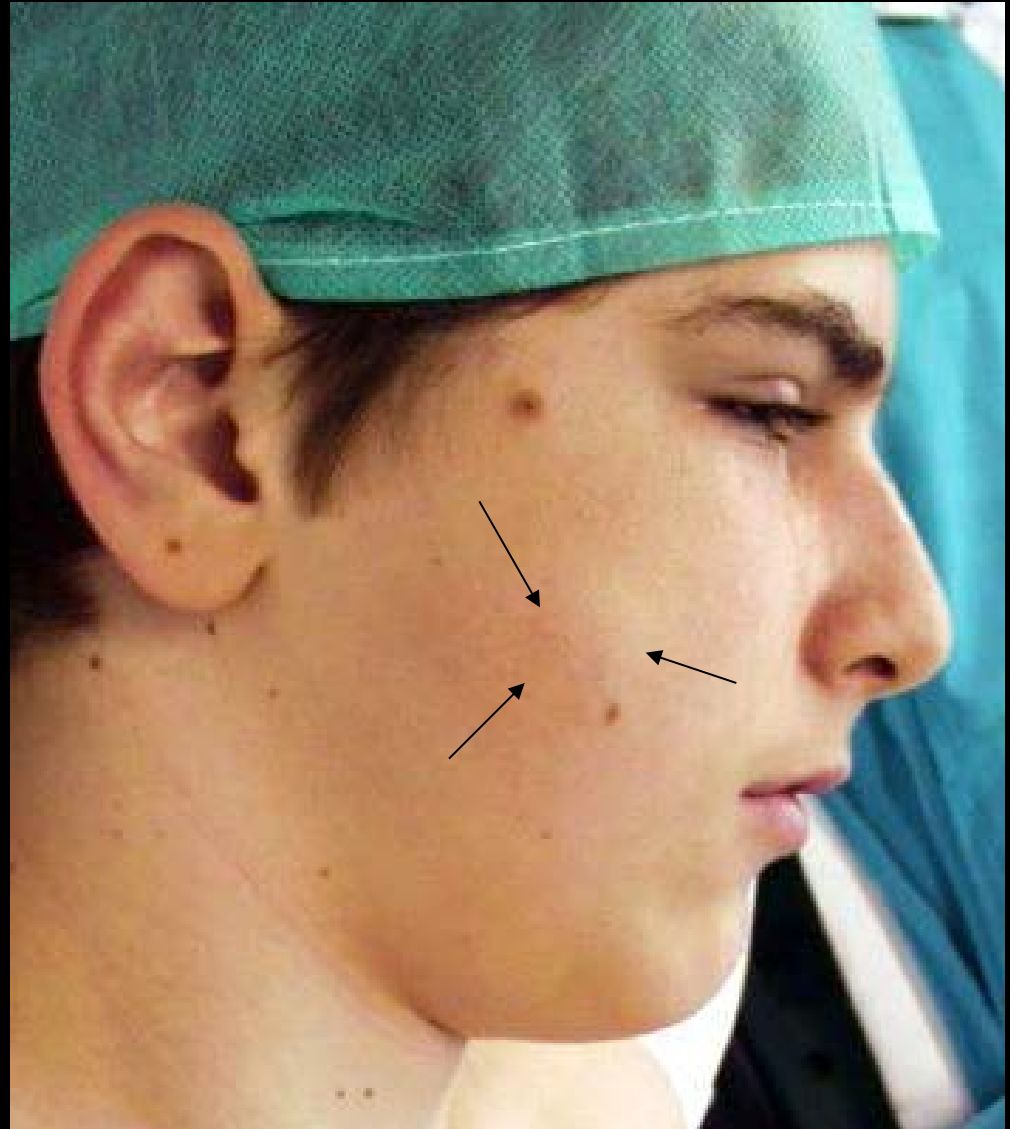
# RAZVOJNE ANOMALIJE

- AGENEZIJA
- HIPOPLAZIJA
- MALFORMACIJE IZVODNIH KANALA



# RAZVOJNE ANOMALIJE

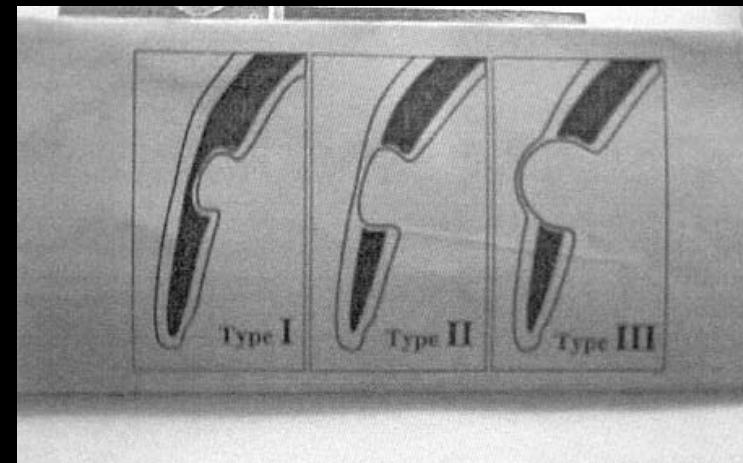
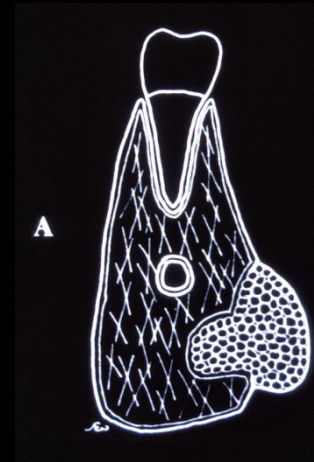
- AKCESORNE

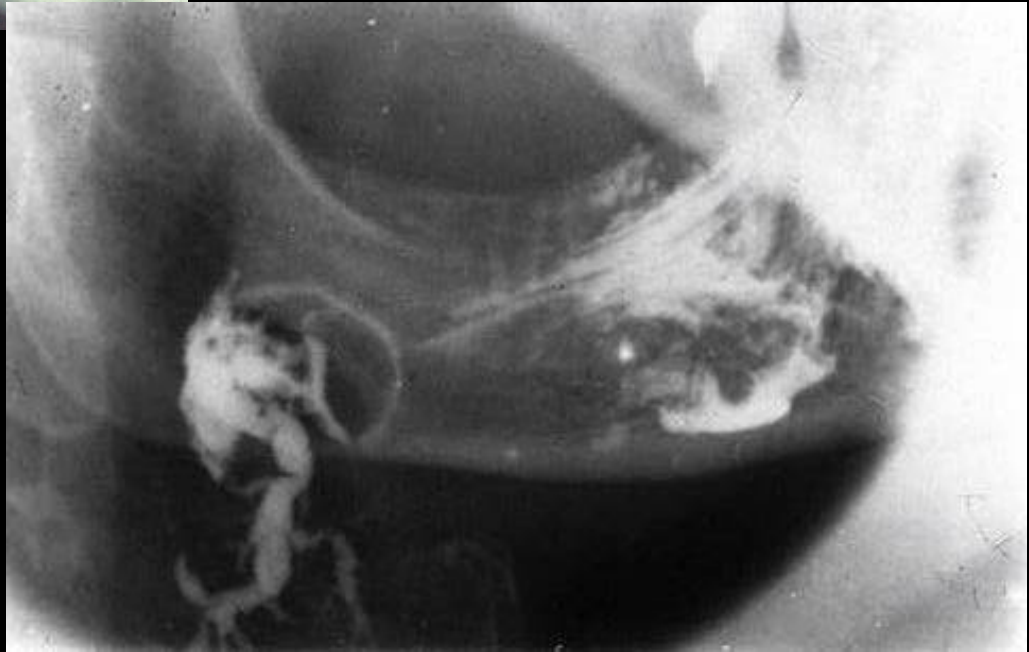
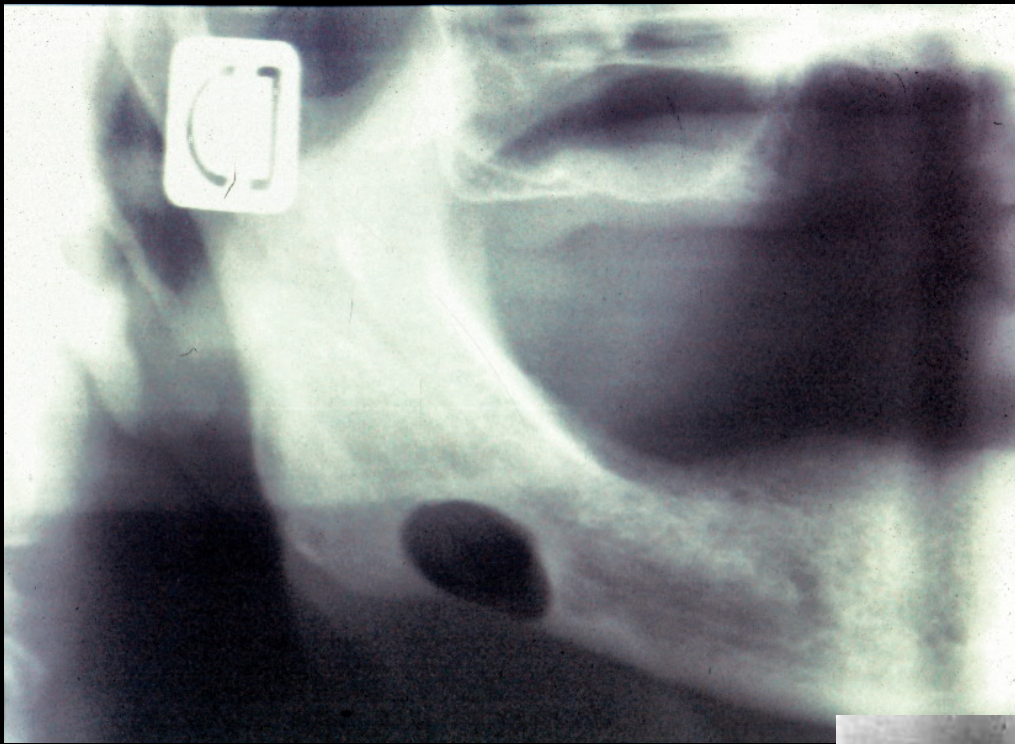


# RAZVOJNE ANOMALIJE

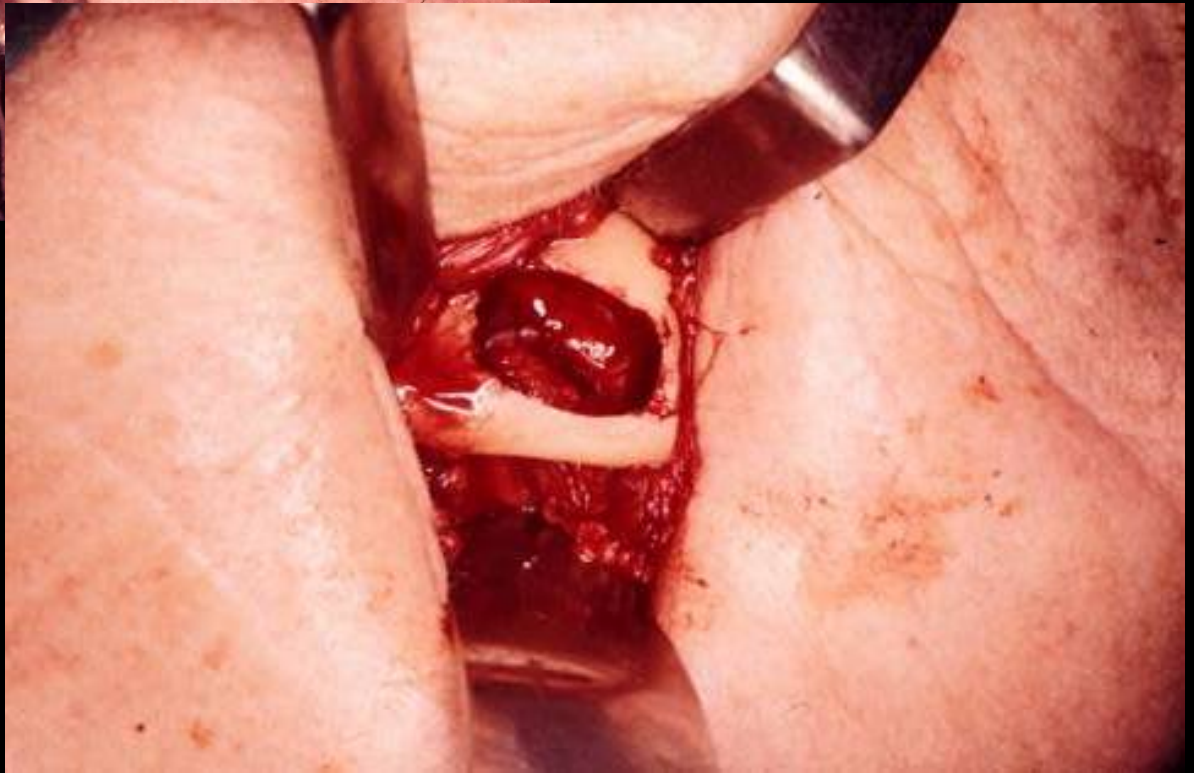
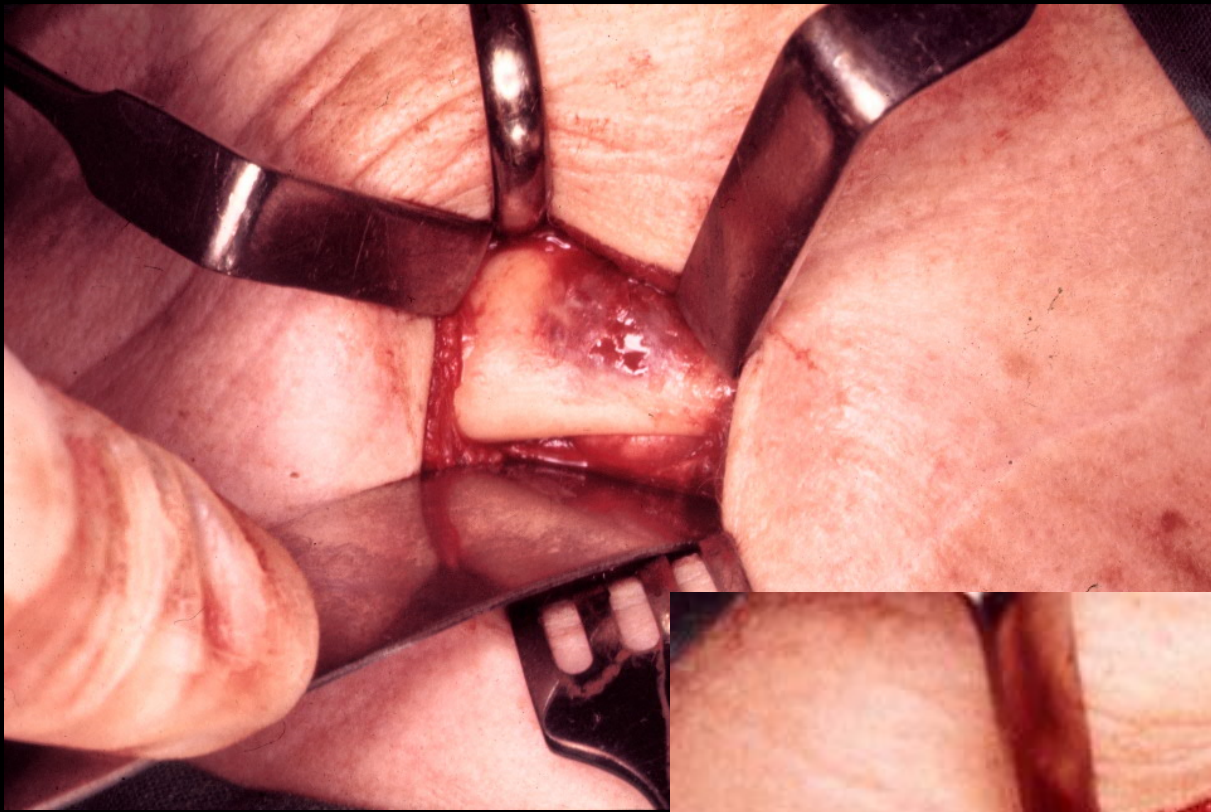
- ABERANTNE  
(EKTOPIČNE)  
ŽLIJEZDE

intralimfoglandularne,  
paraparotidnih l.č.,  
intraosealno, meko tkivo  
vrata – čvorovi sa ili bez  
salivarne fistule  
u kosti – cistične  
formacije  
th - kirurška

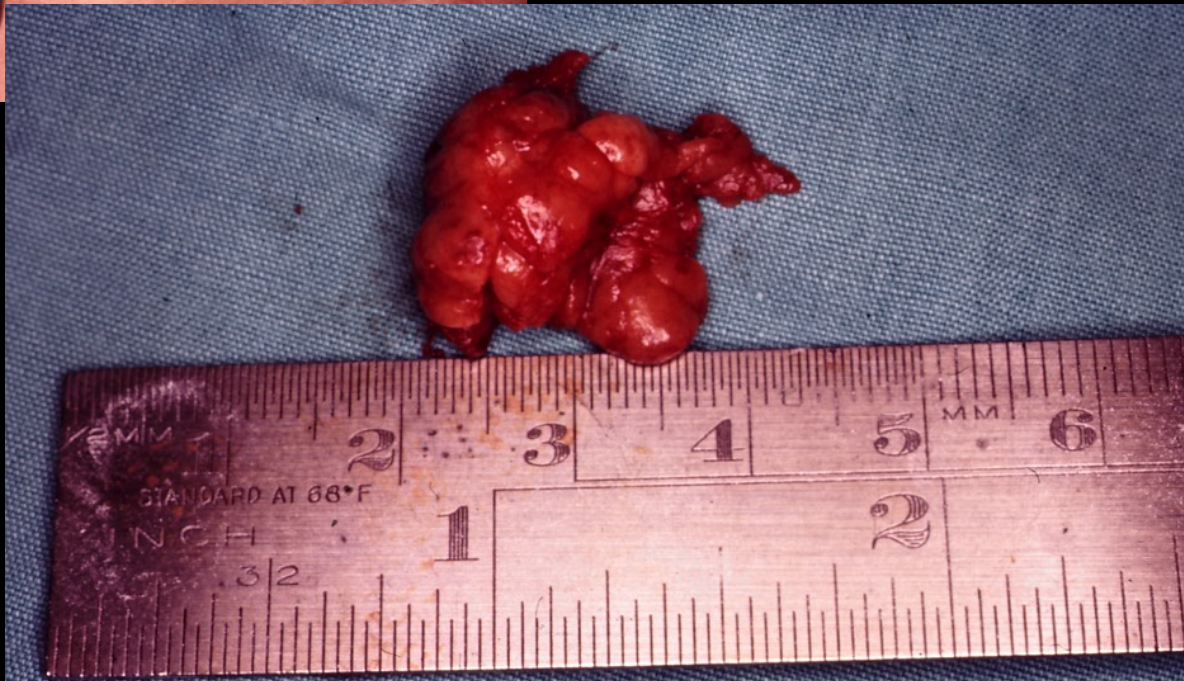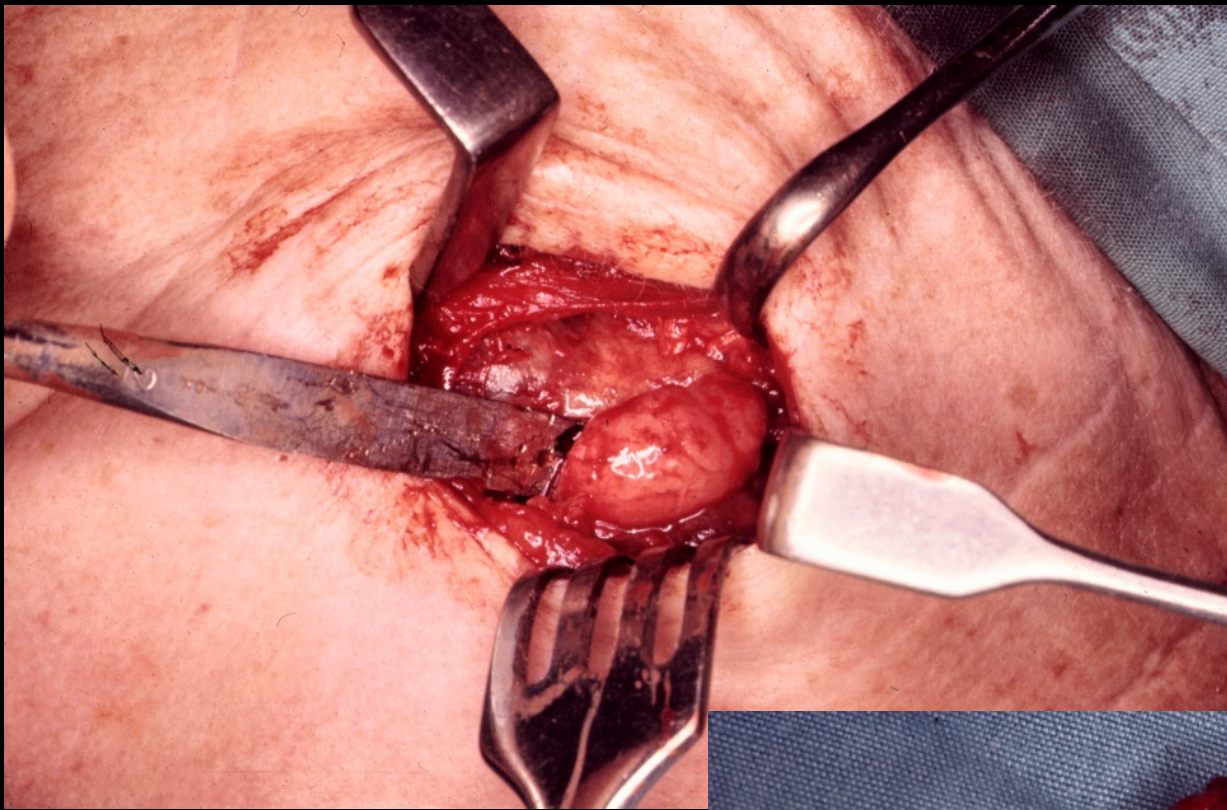












# AKUTNA UPALA

virusne, bakterijske, najčešće parotida

## EPIDEMIČKI PAROTITIS (MUMPS)

- 70% obje parotide
- < 10% submandibularna žlijezda

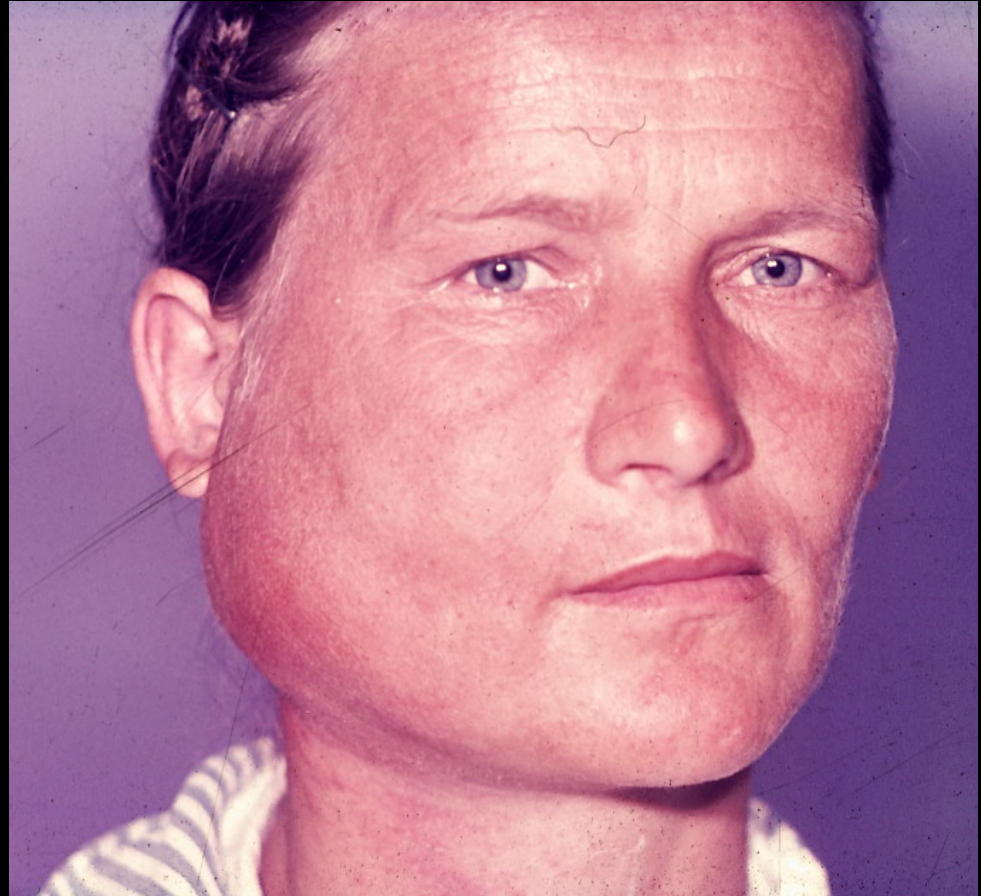## AKUTNI BAKTERIJSKI SIALOADENITIS

- najčešće parotida, u 20% obje žlijezde
- submandibularna - kamenac
- ascendentna infekcija ili opstrukcija kamencem
- bolan otok, oskudna gnojna sekrecija
- opći simptomi upale
- hidracija, antibiotici, dobra higijena, rijetko incizija i drenaža



# AKUTNA UPALA

AKUTNI BAKTERIJSKI  
SIALOADENITIS



# KRONIČNA UPALA

## *KRONIČNA RECIDIVIRAJUĆA*

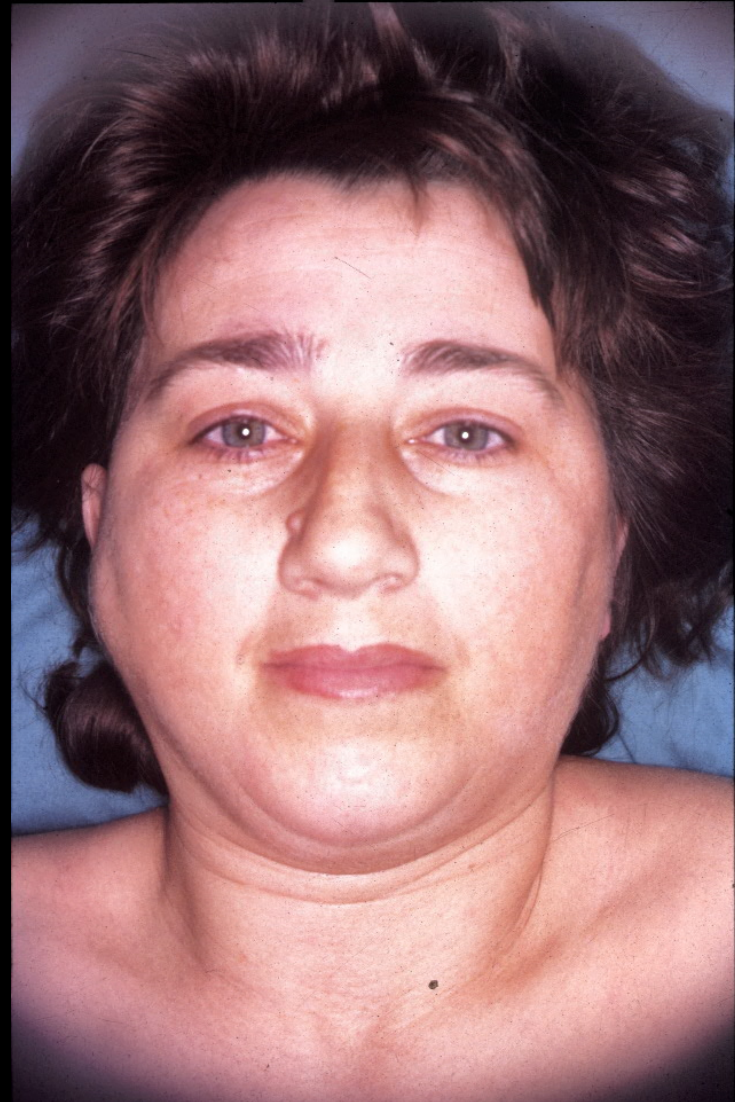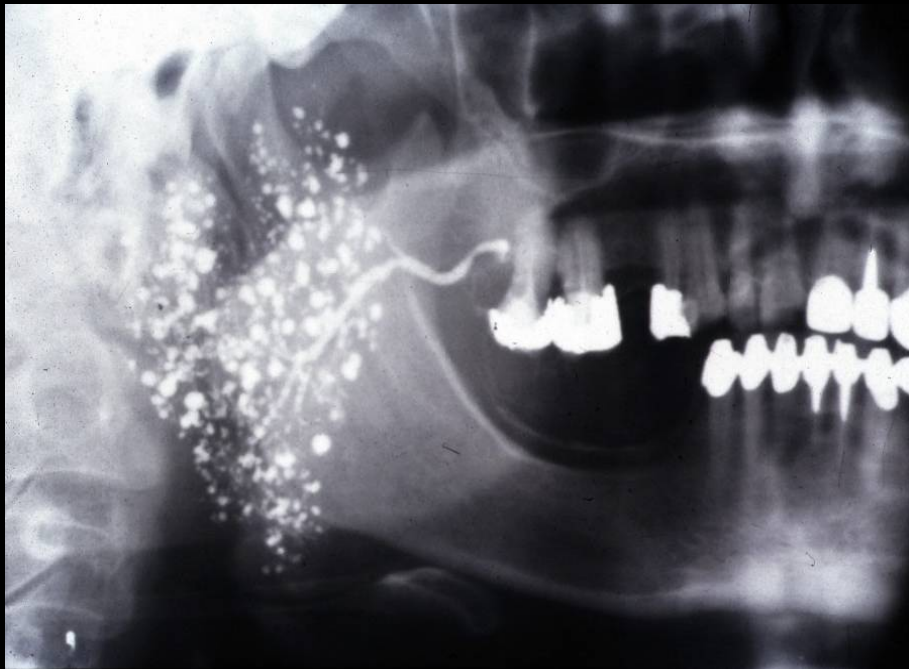- bakterijska, najčešće parotida
- kronično oštećena žlijezda zbog više akutnih upala
- deformirani izvodni kanali i vezivom prožeto žl. tkivo
- sekrecija smanjena, slina gusta i zamućena, oteklina se pojačava pri jelu

## *REKURENTNI PAROTITIS*

- žene srednjih godina
- djeca do 12. godine uz spontanu remisiju u pubertetu
- konzervativna th., antibiotici ev. i intraduktalno
- parotidektomija - rijetko

# KRONIČNA UPALA

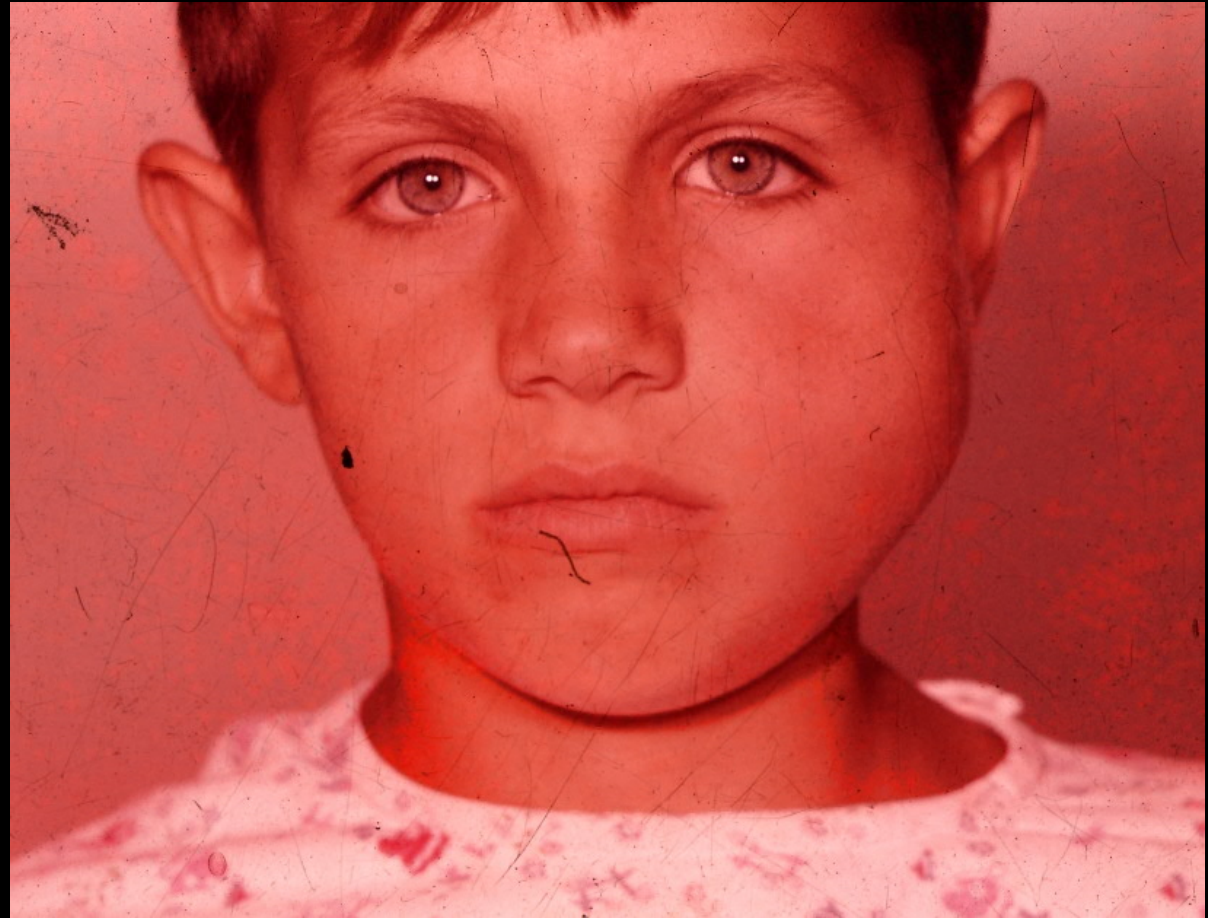KRONIČNA  
RECIDIVIRAJUĆA UPALA





# KRONIČNA UPALA

REKURENTNI  
PAROTITIS

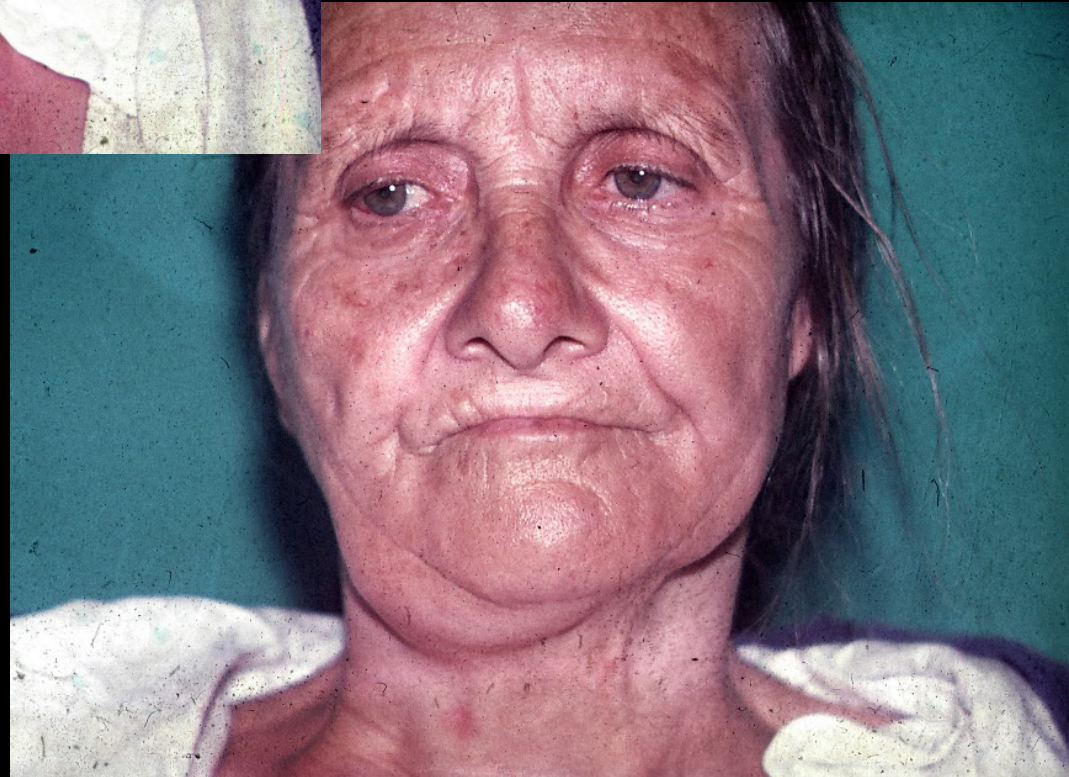
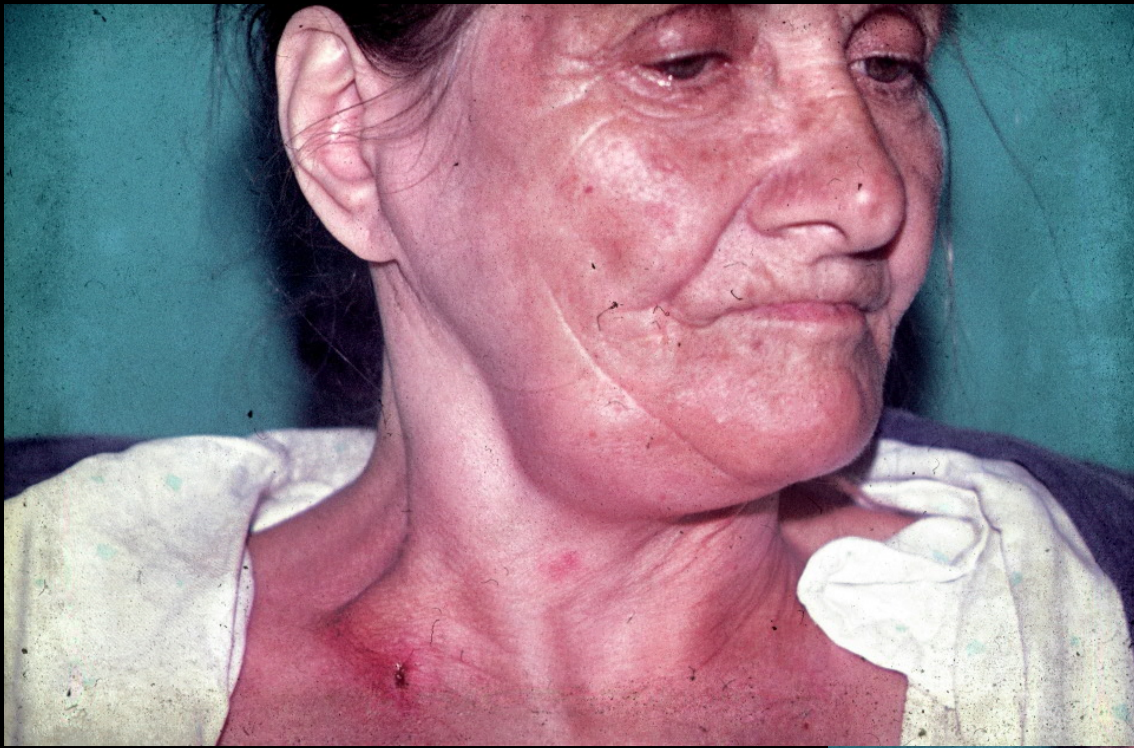
- SPECIFIČNE  
INFEKCIJE

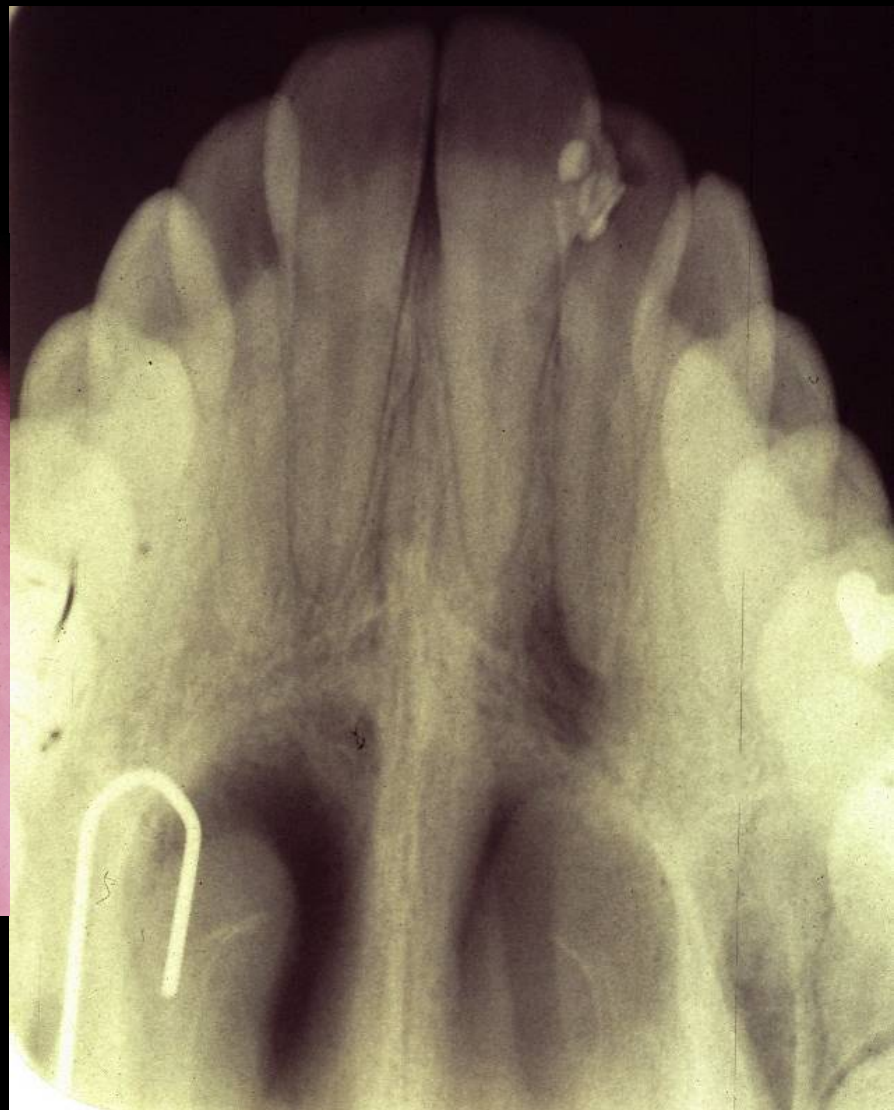
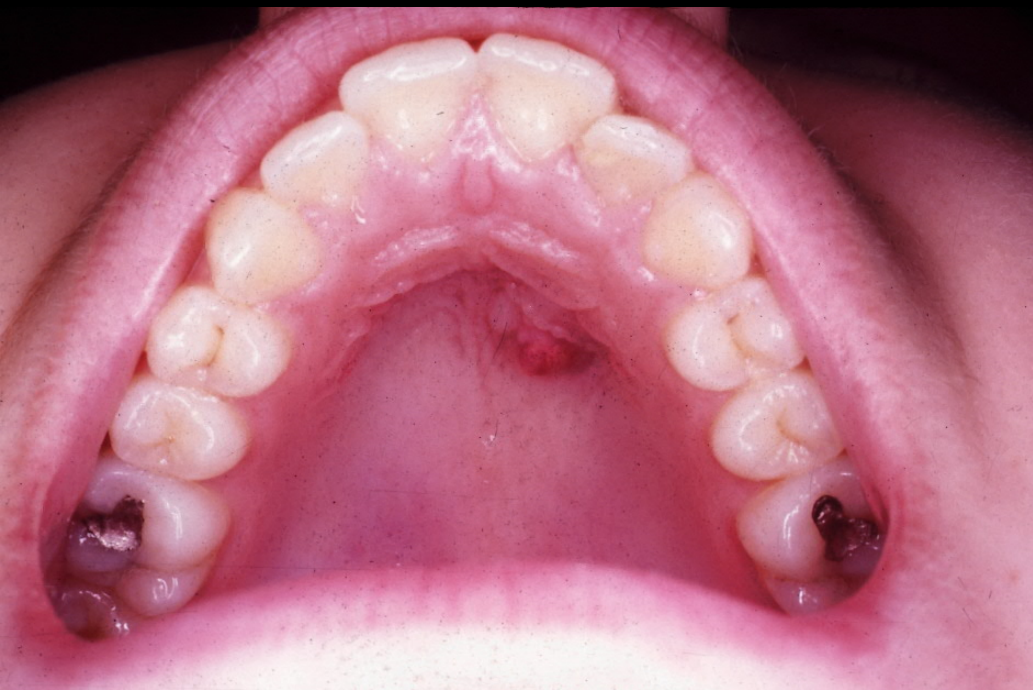# KRONIČNA UPALA

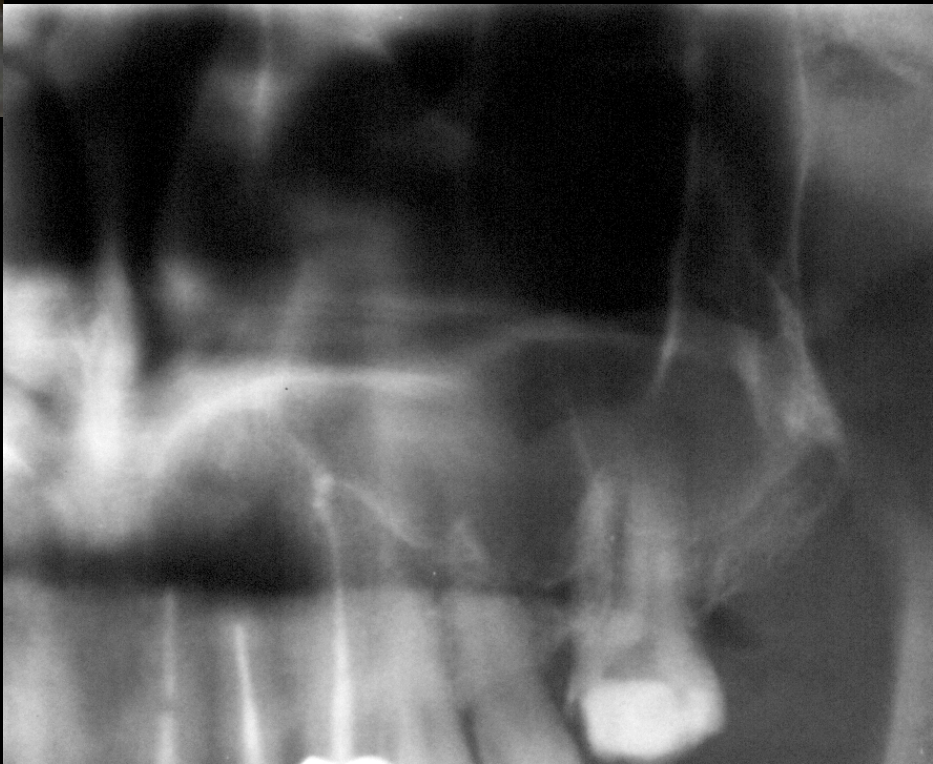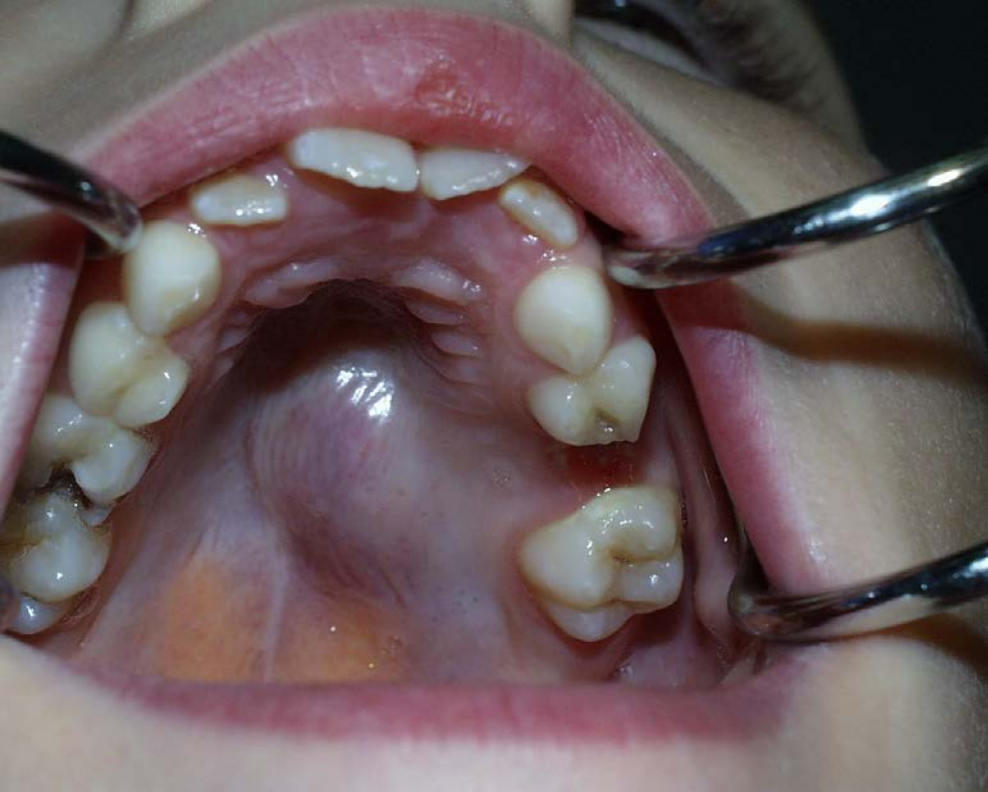## *SPECIFIČNE UPALE*

- TBC
- sarkoidoza
  - uvoparotidna groznica – Heerfordtov sindrom –  
uveitis, parotitis, tranzitorna paraliza facialisa
- aktinomikoza
- lues





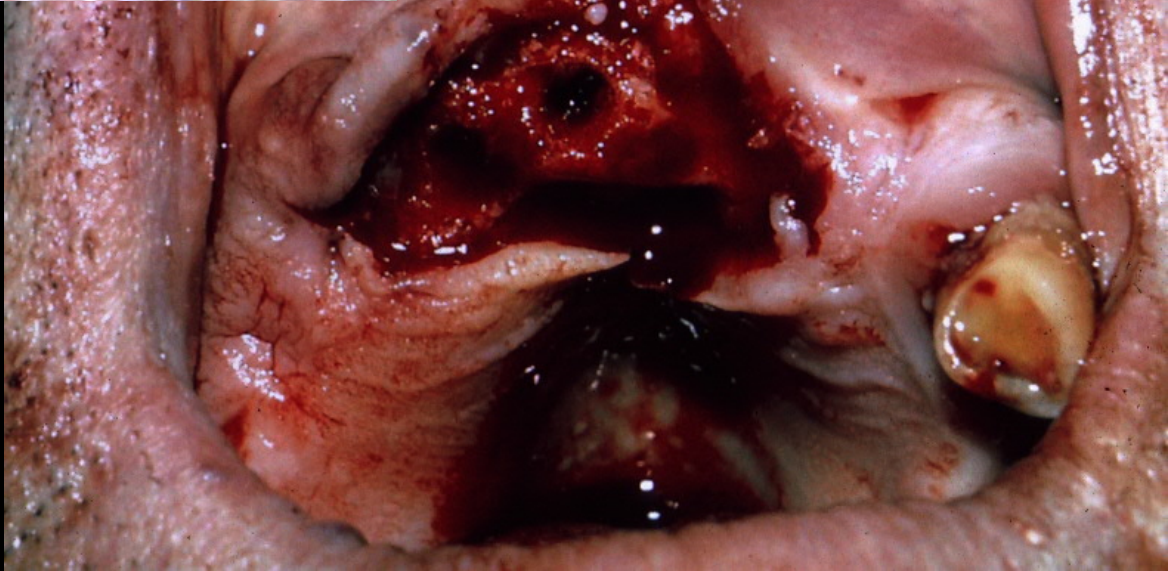
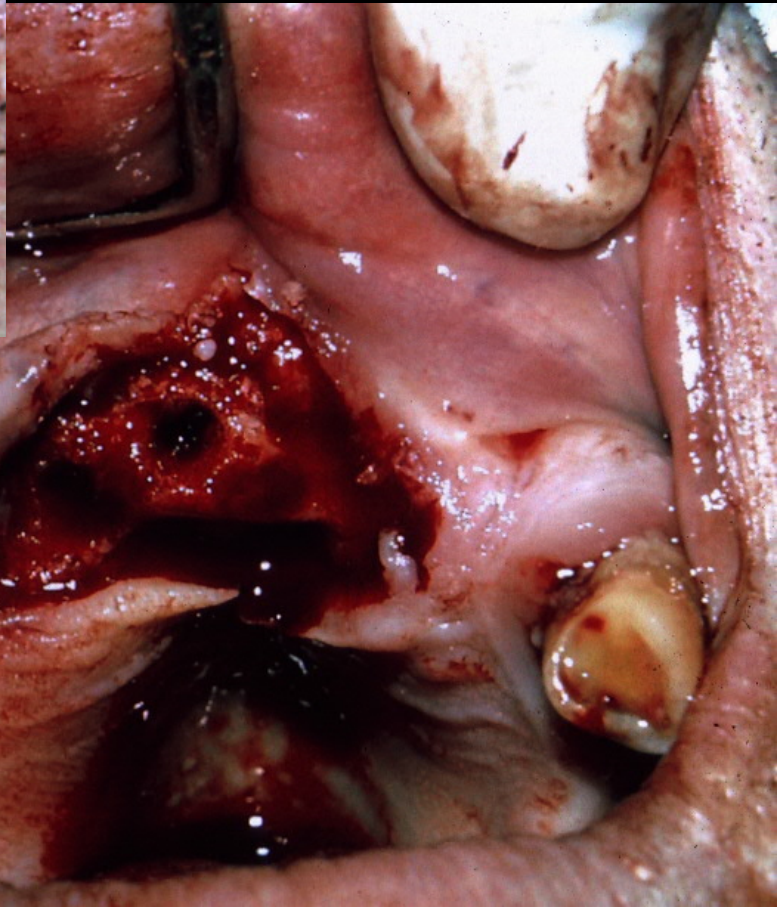
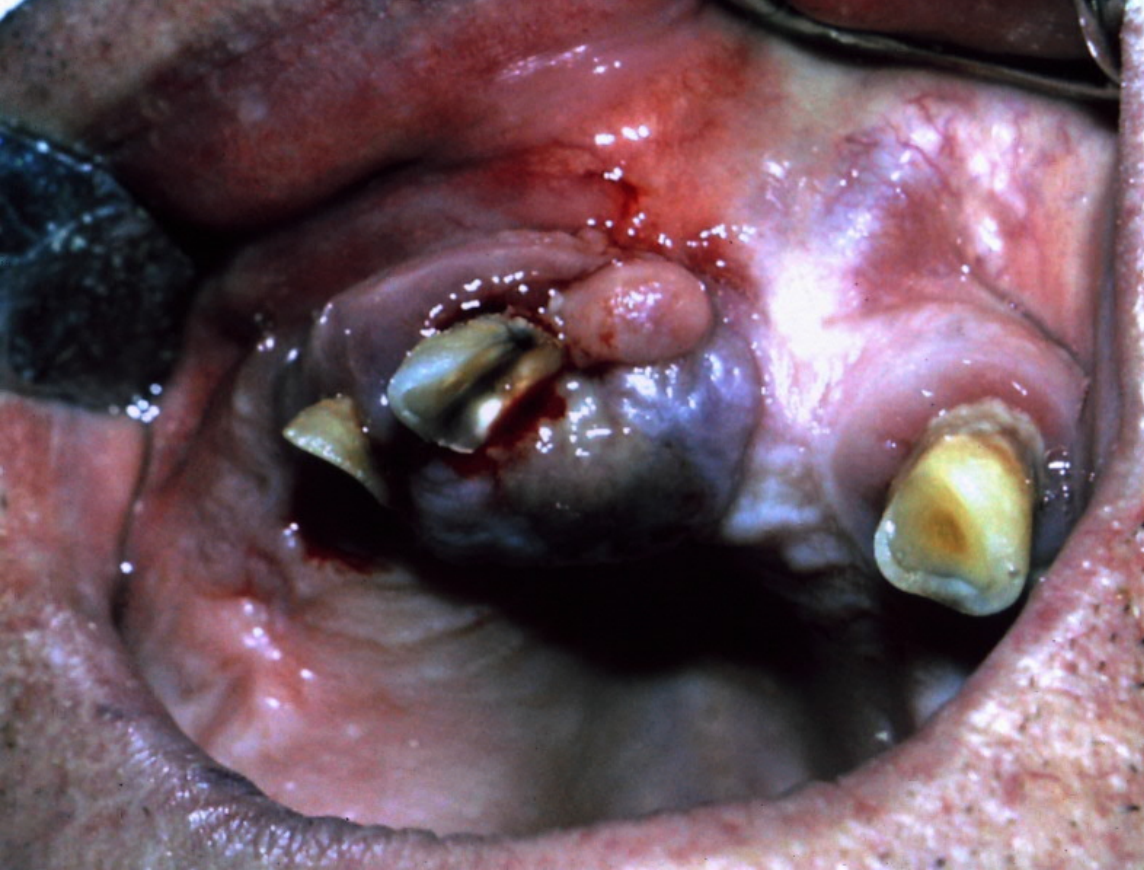


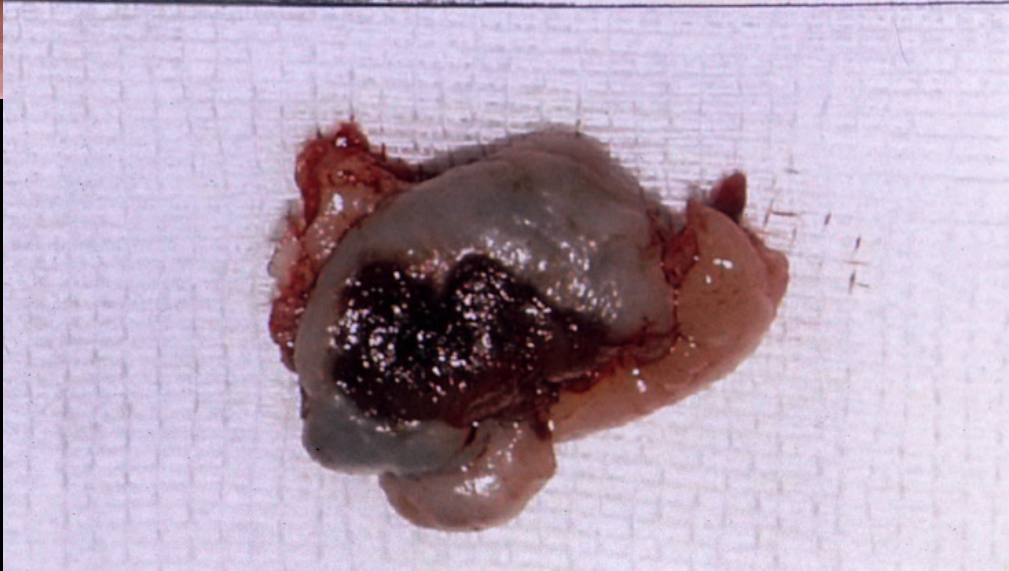

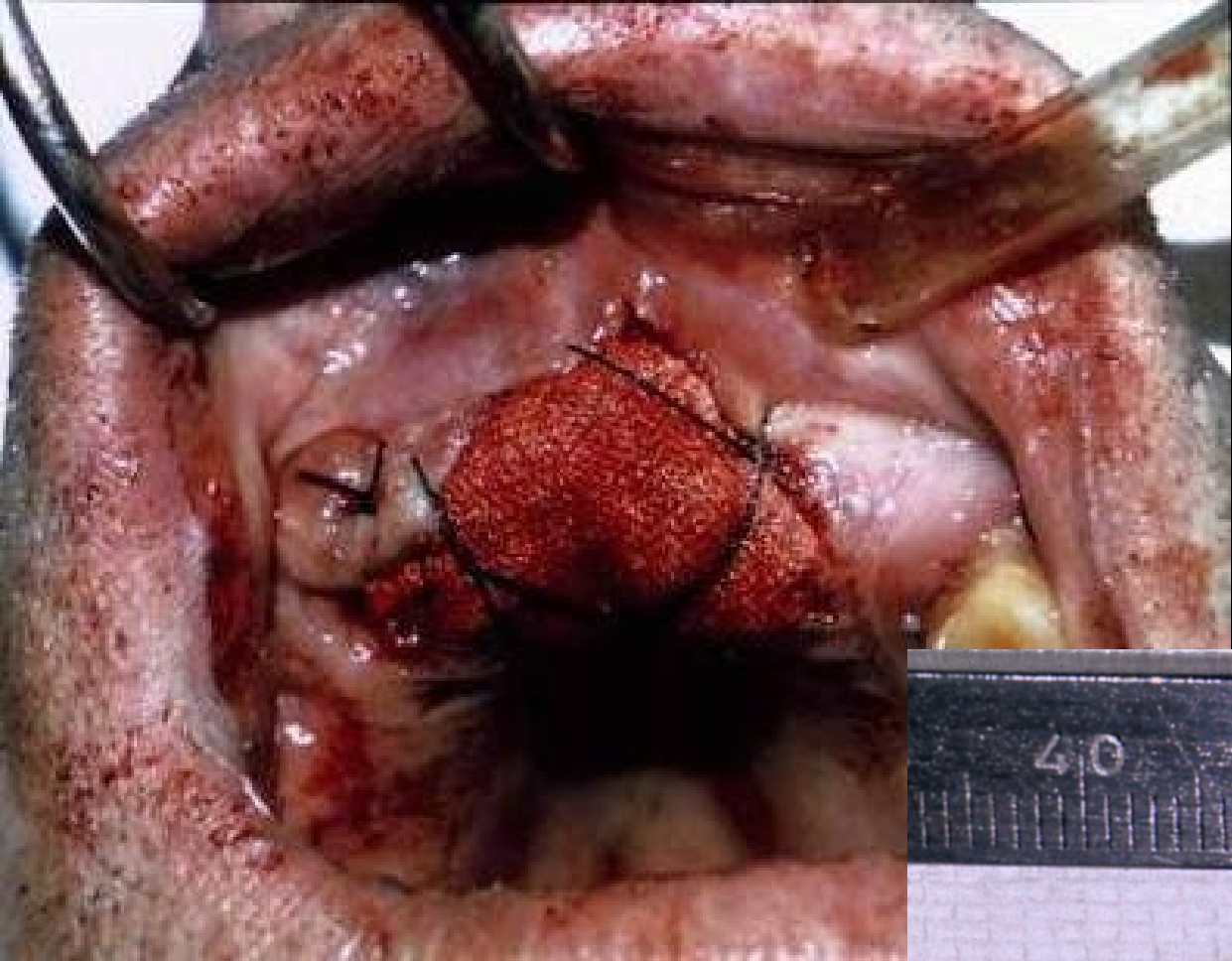



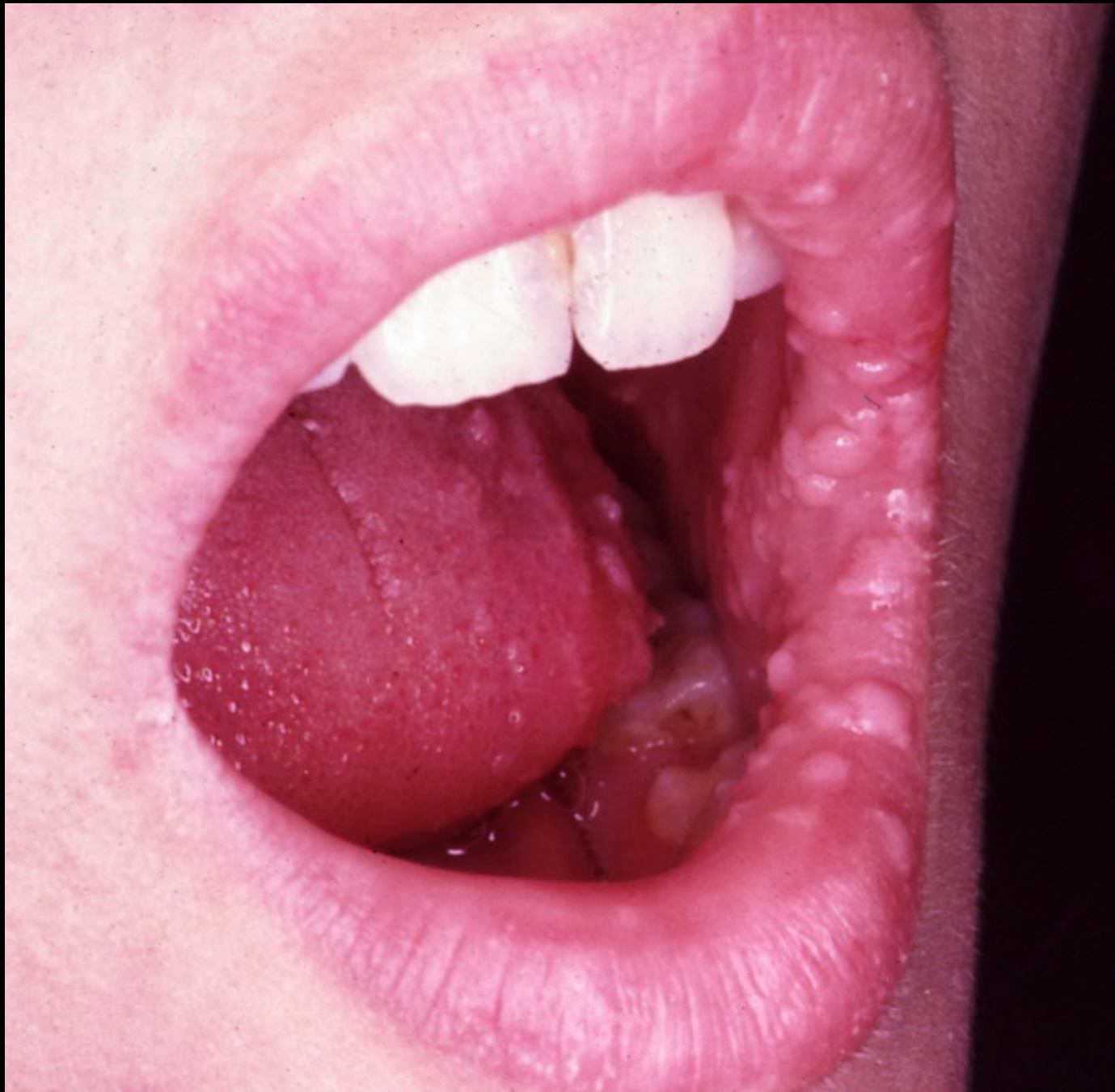




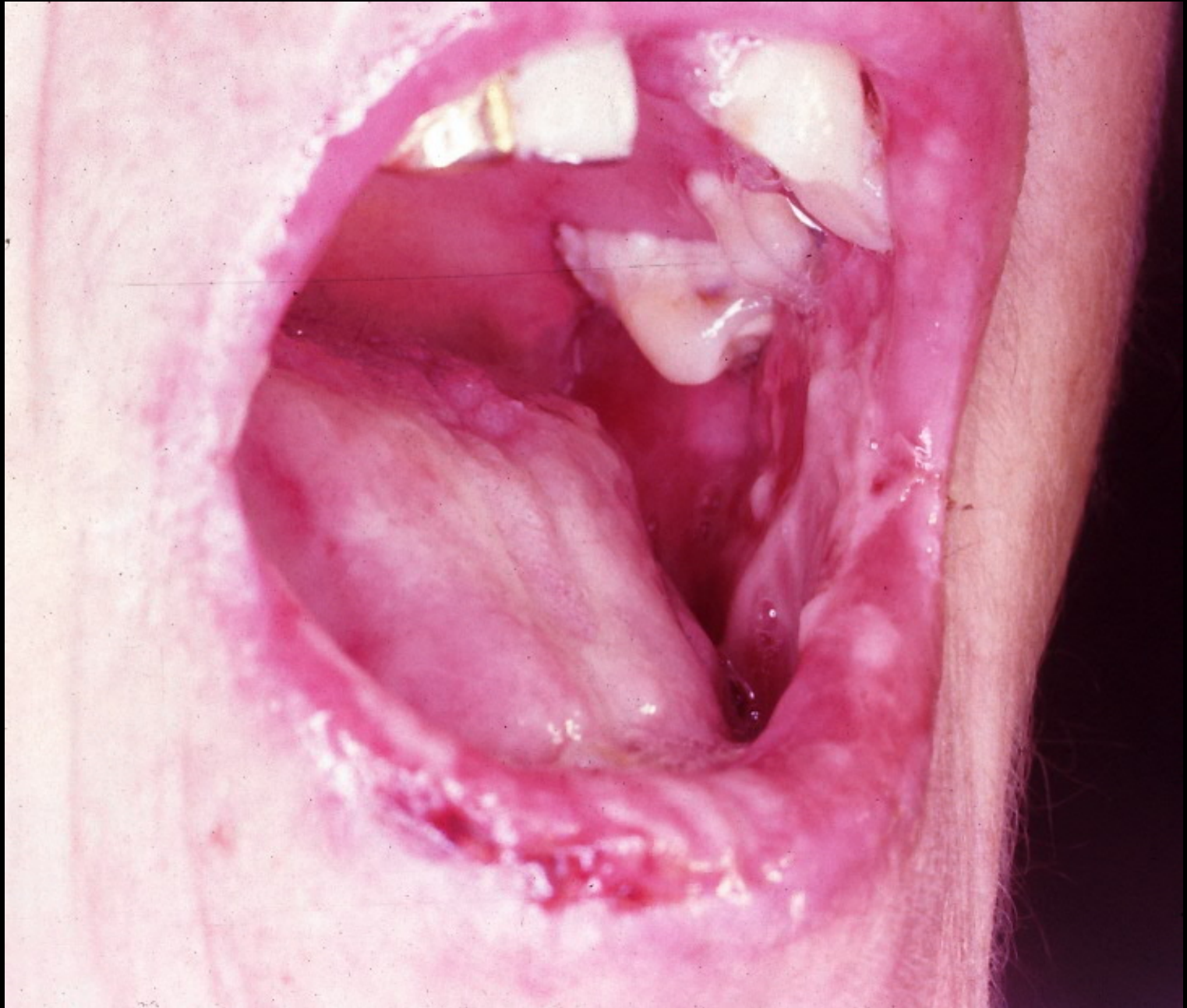




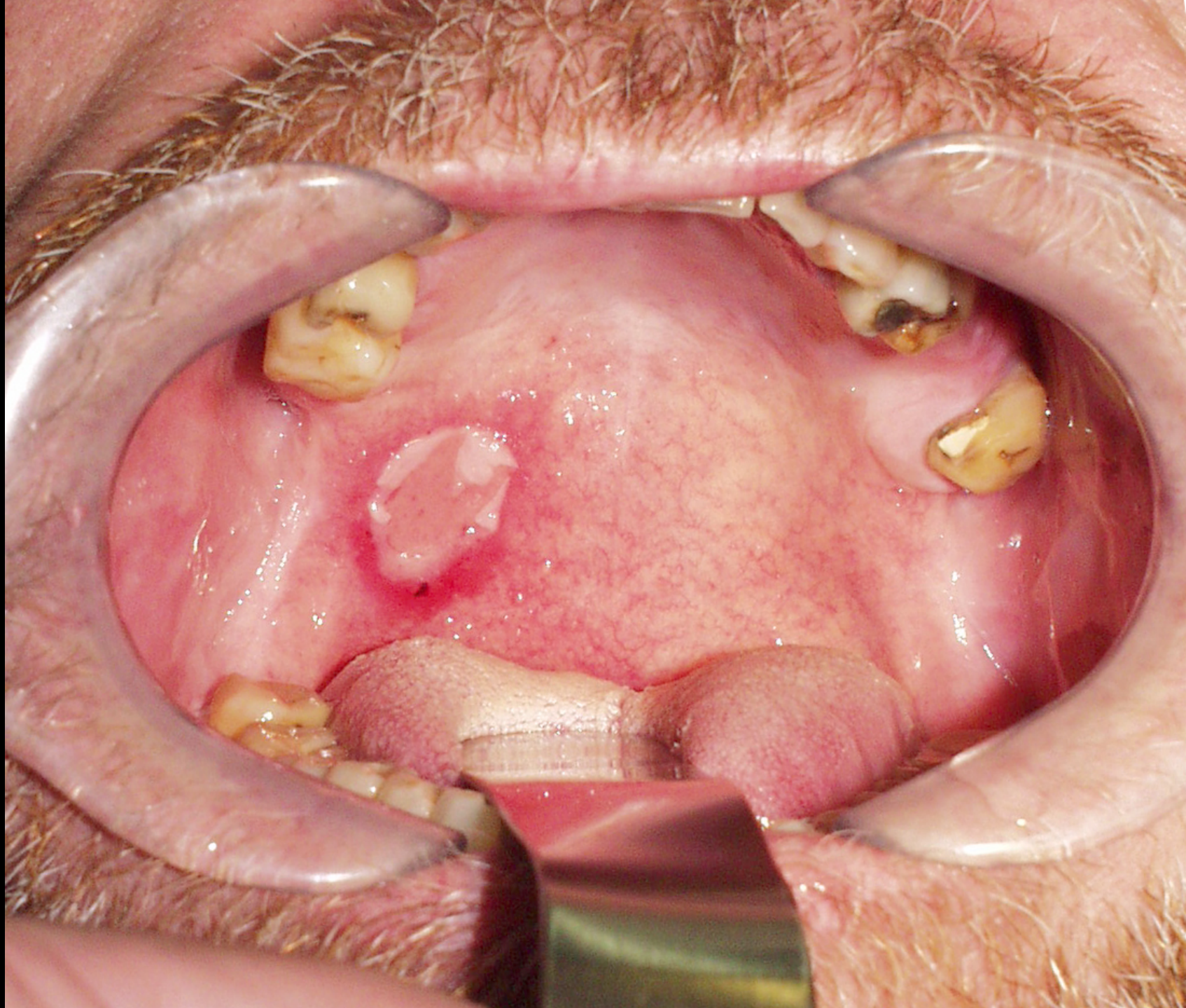




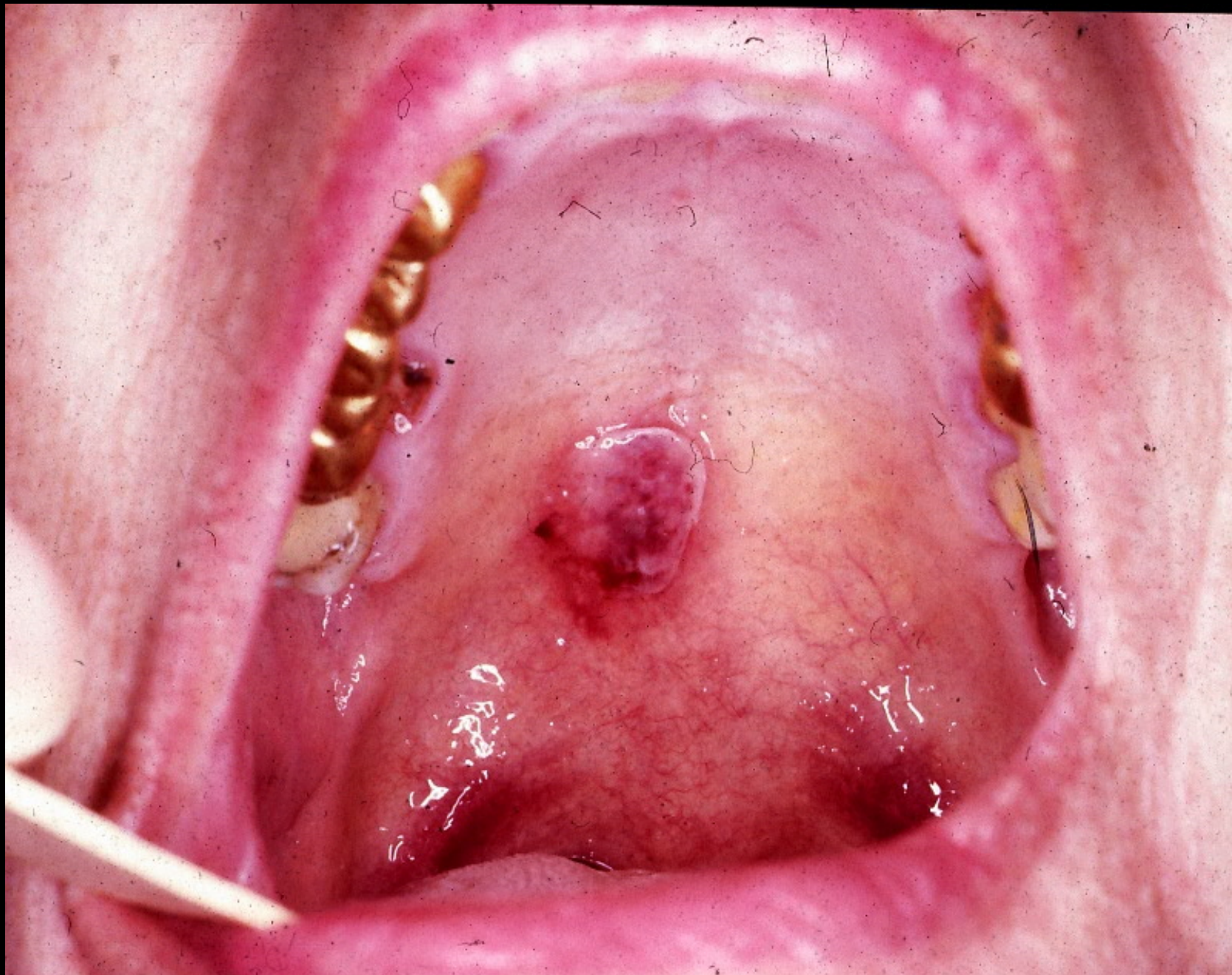




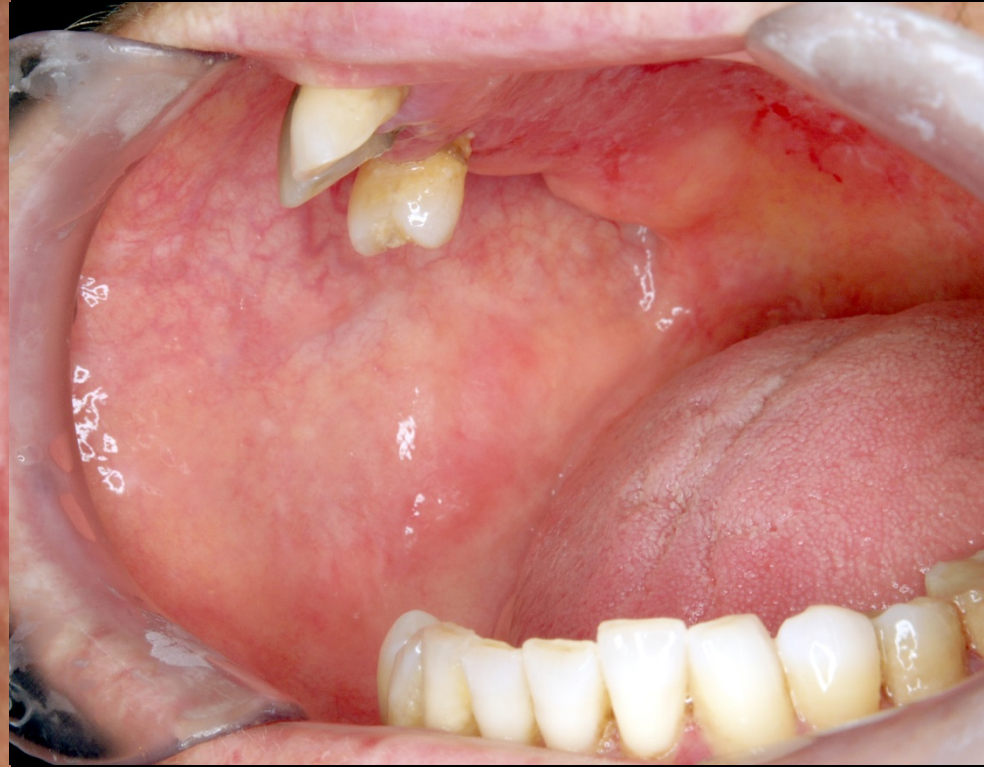
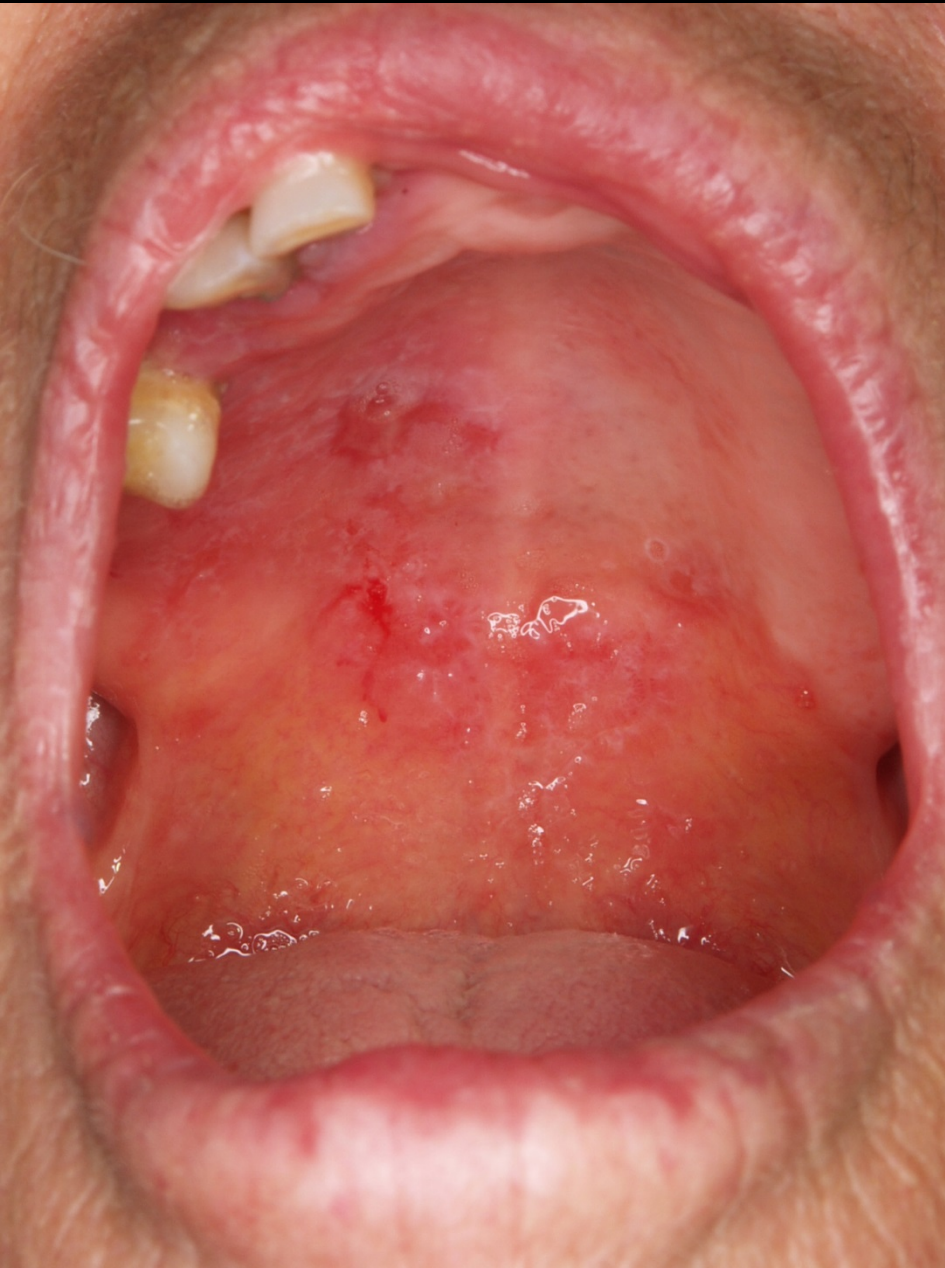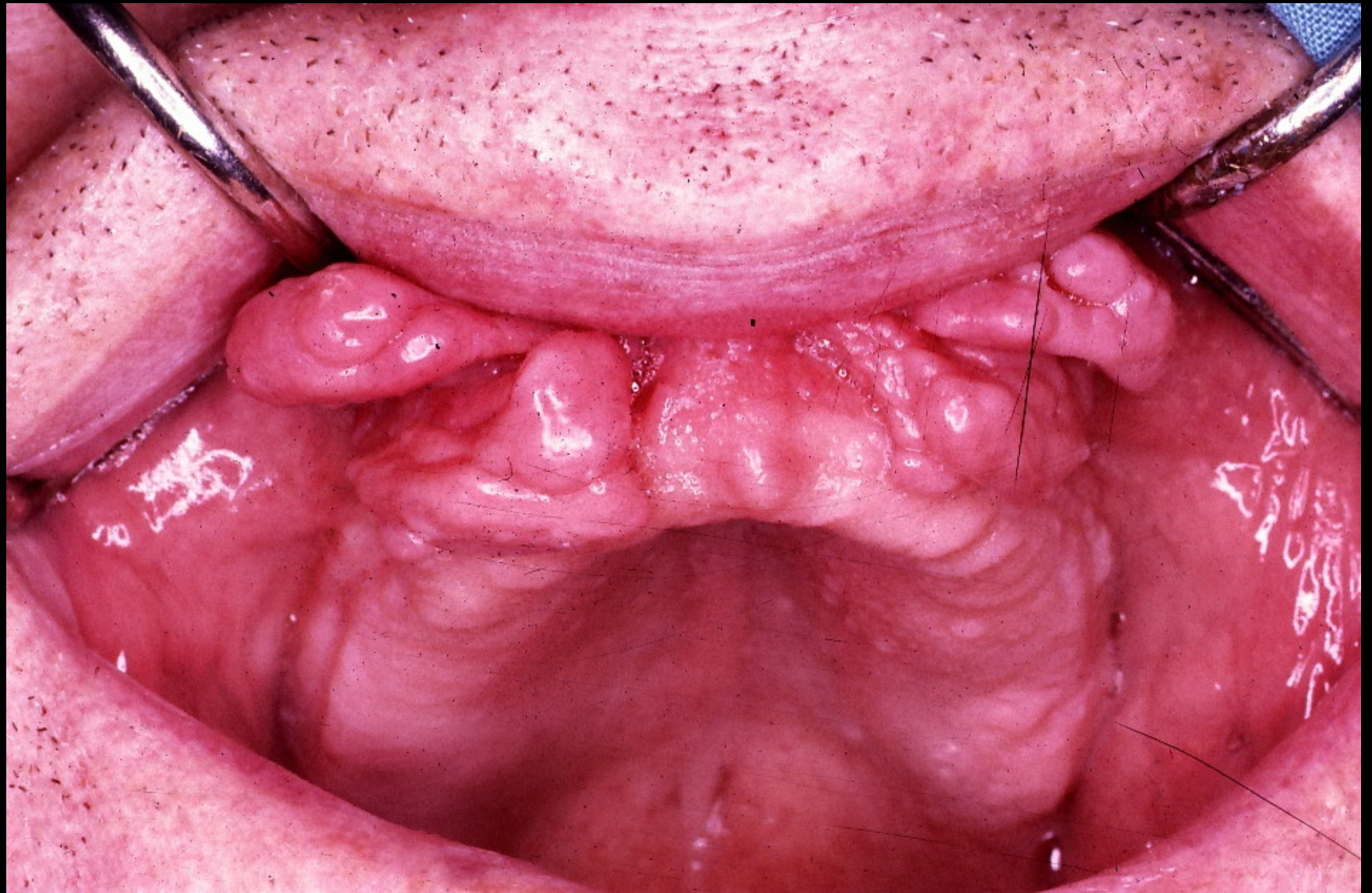




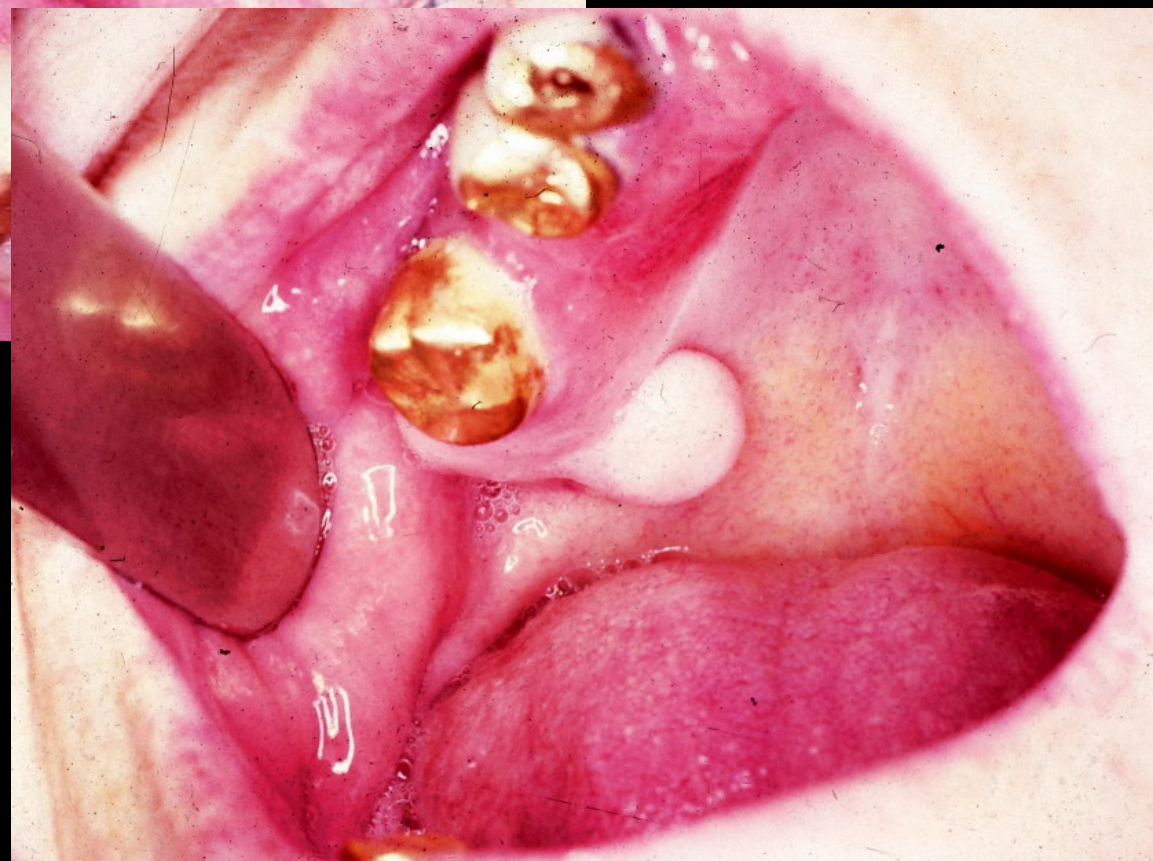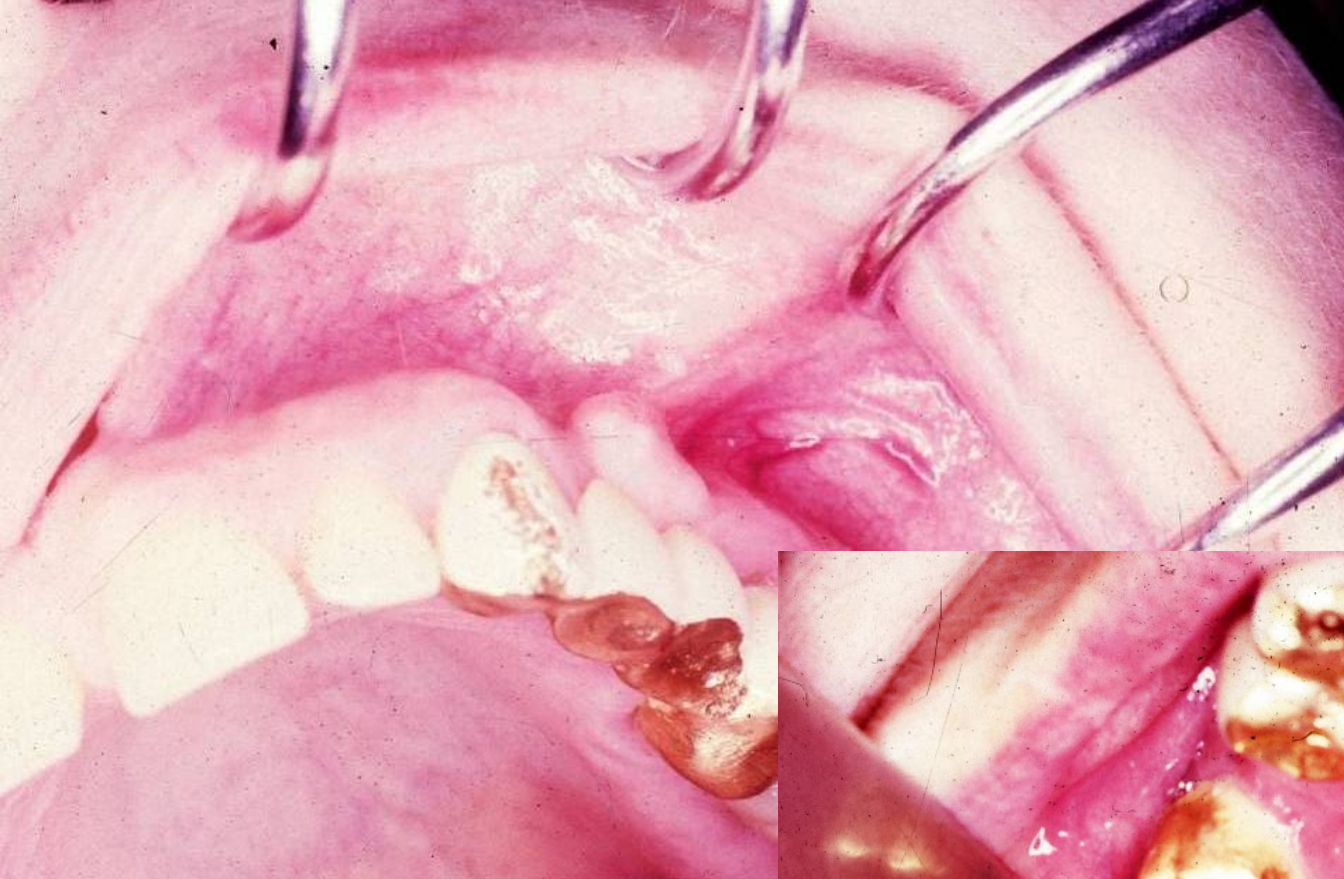




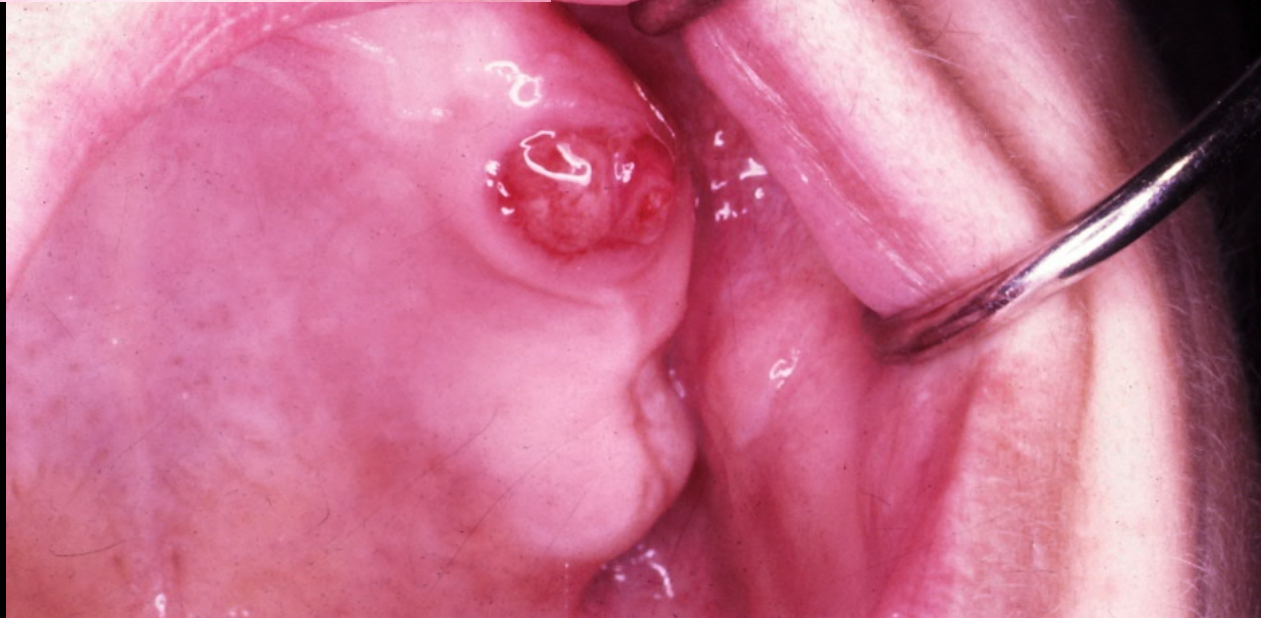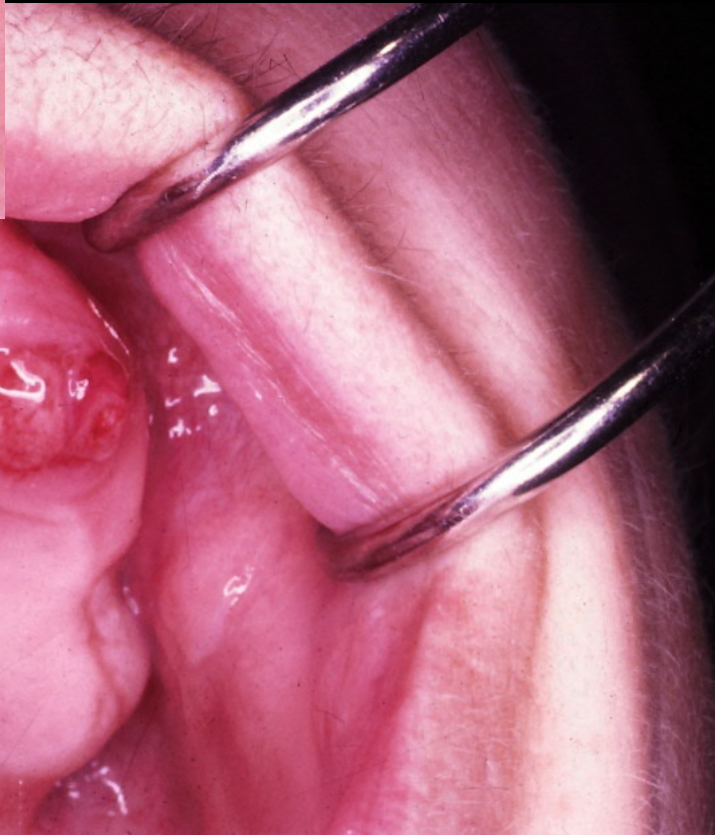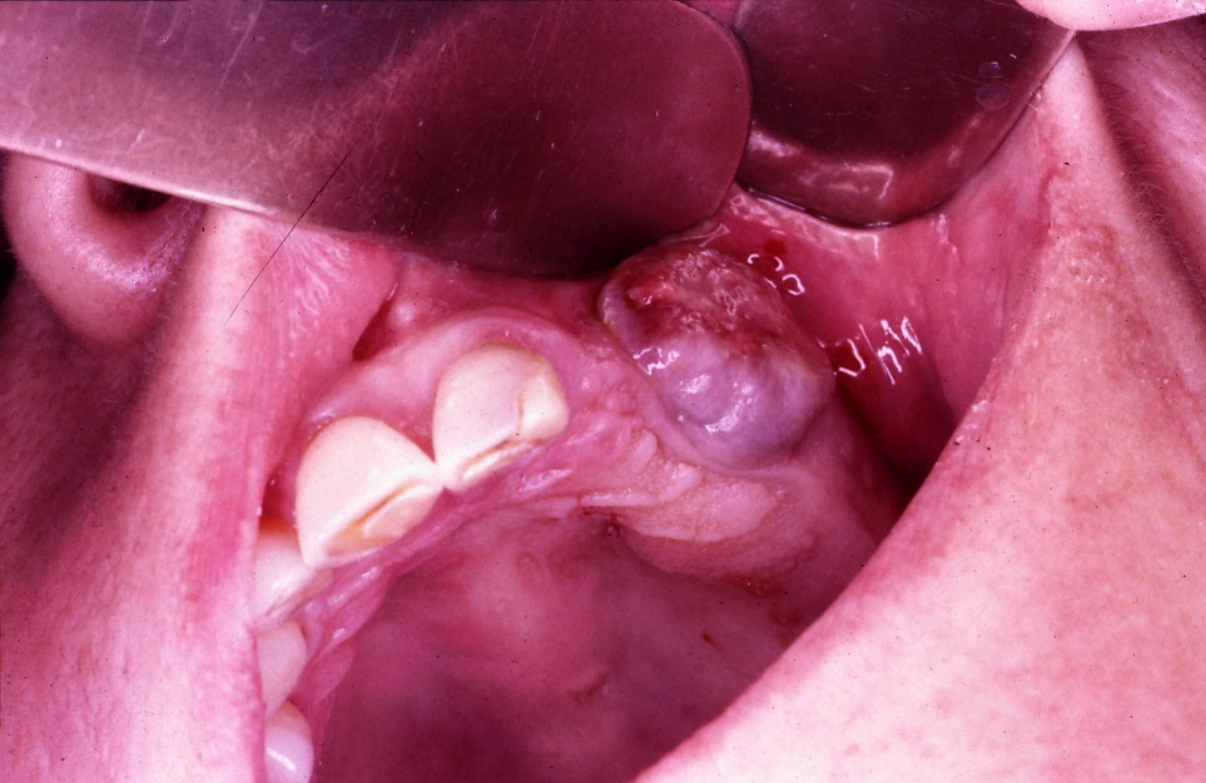








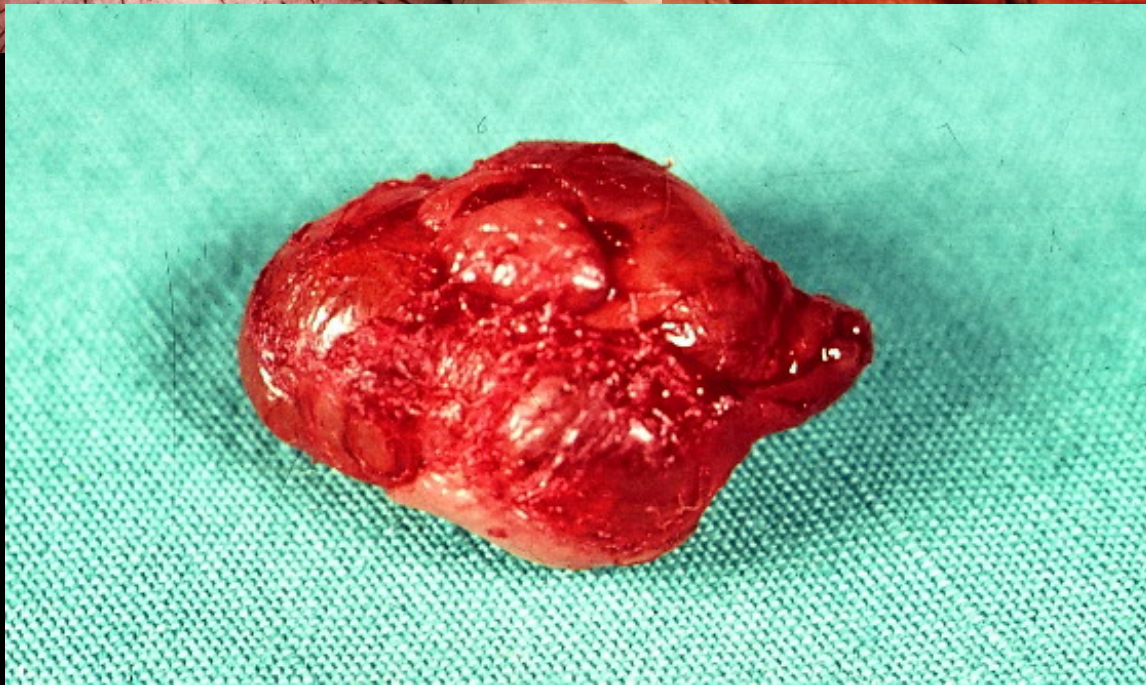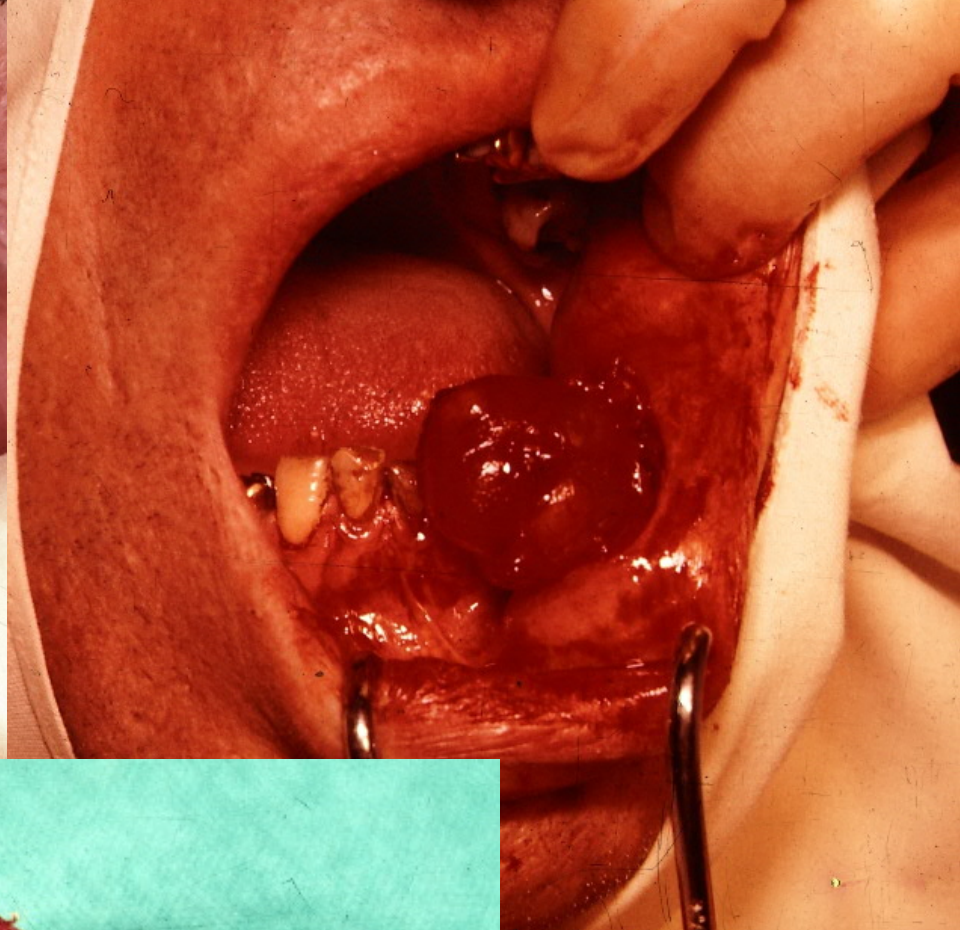




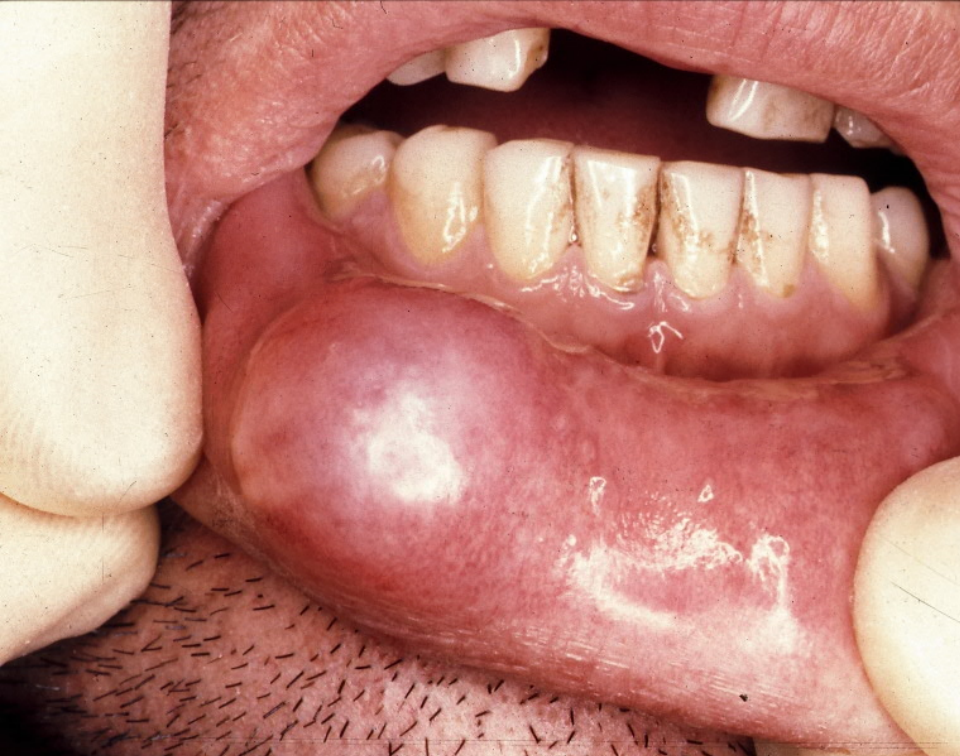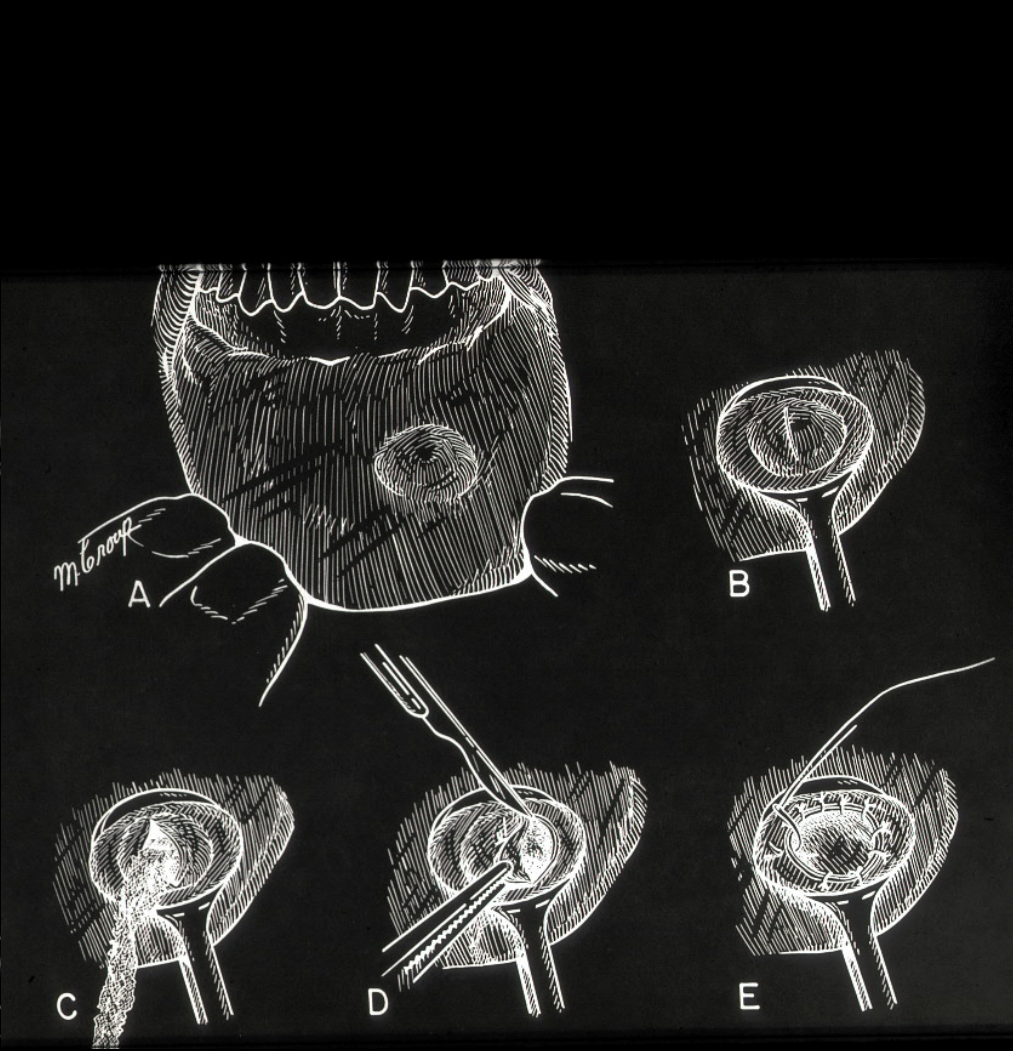
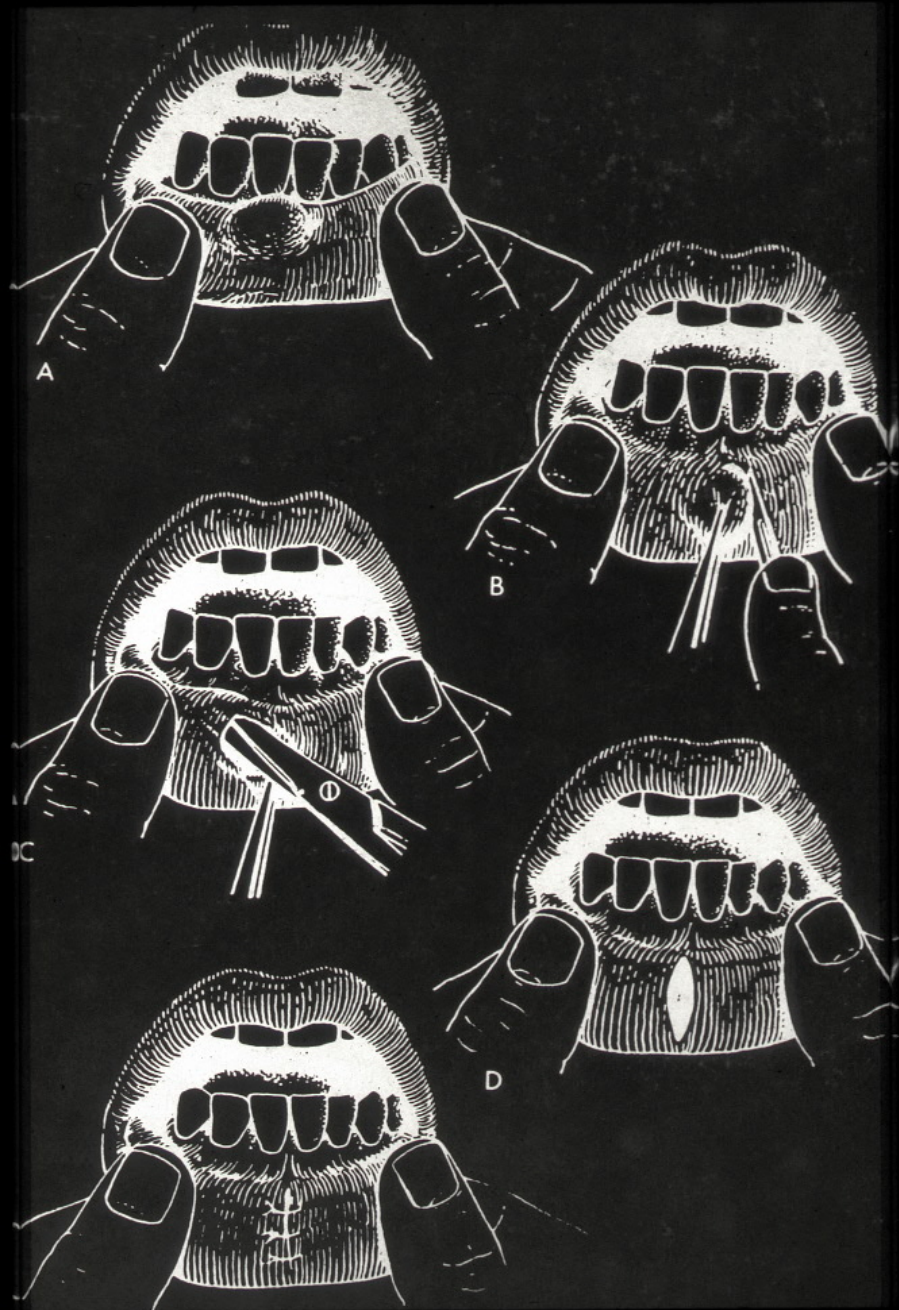
# CISTIČNE PROMJENE

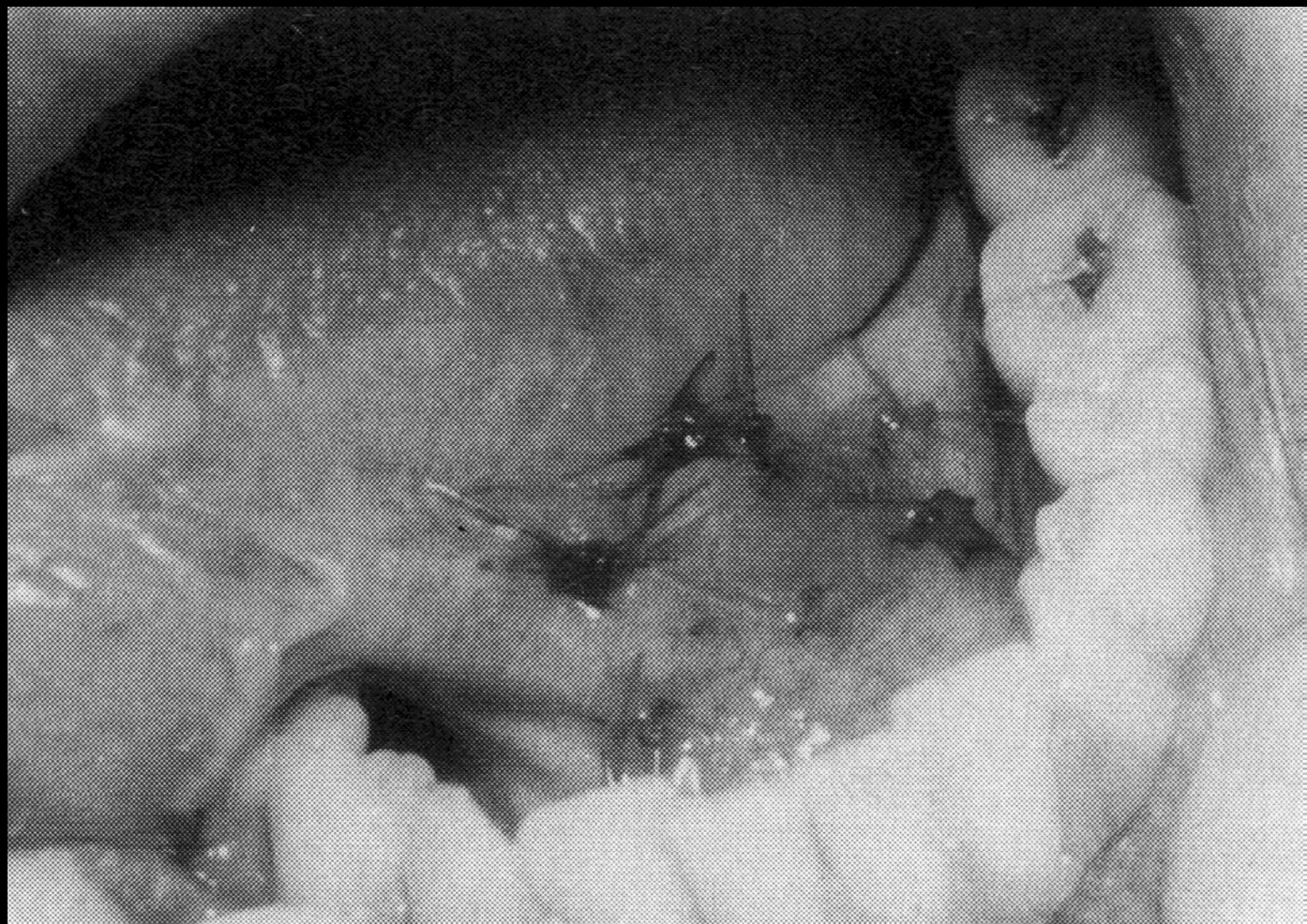
- *KONGENITALNE* – bezbolna oteklina
  - dermoidne - punkcijom
  - duktalne - sialografijom
  - od prvog škržnog luka – vezane uz zvučnik
- *STEČENE* – sekundarno nakon upale, kamenca, traume
- *MUKOKELE*



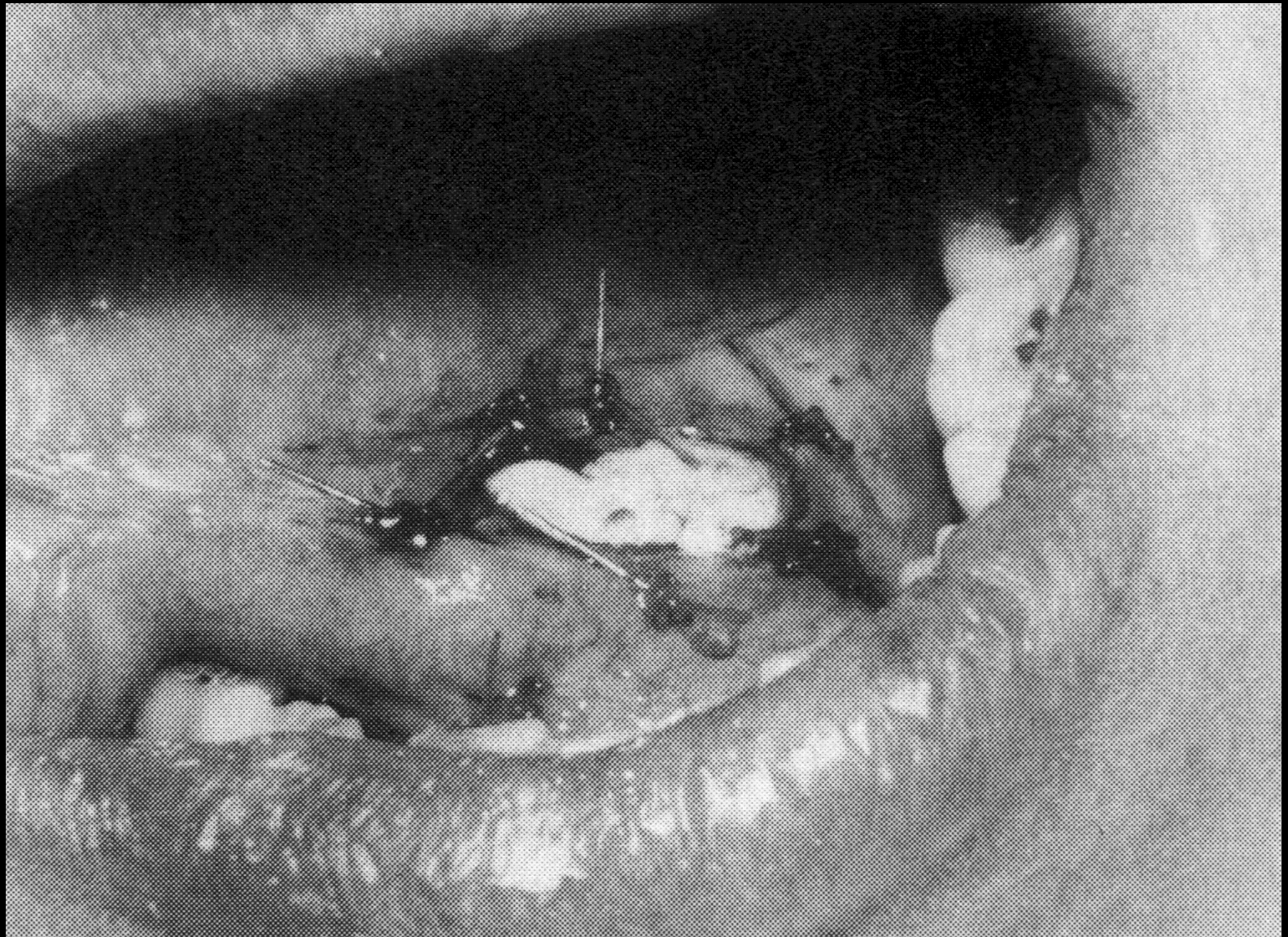




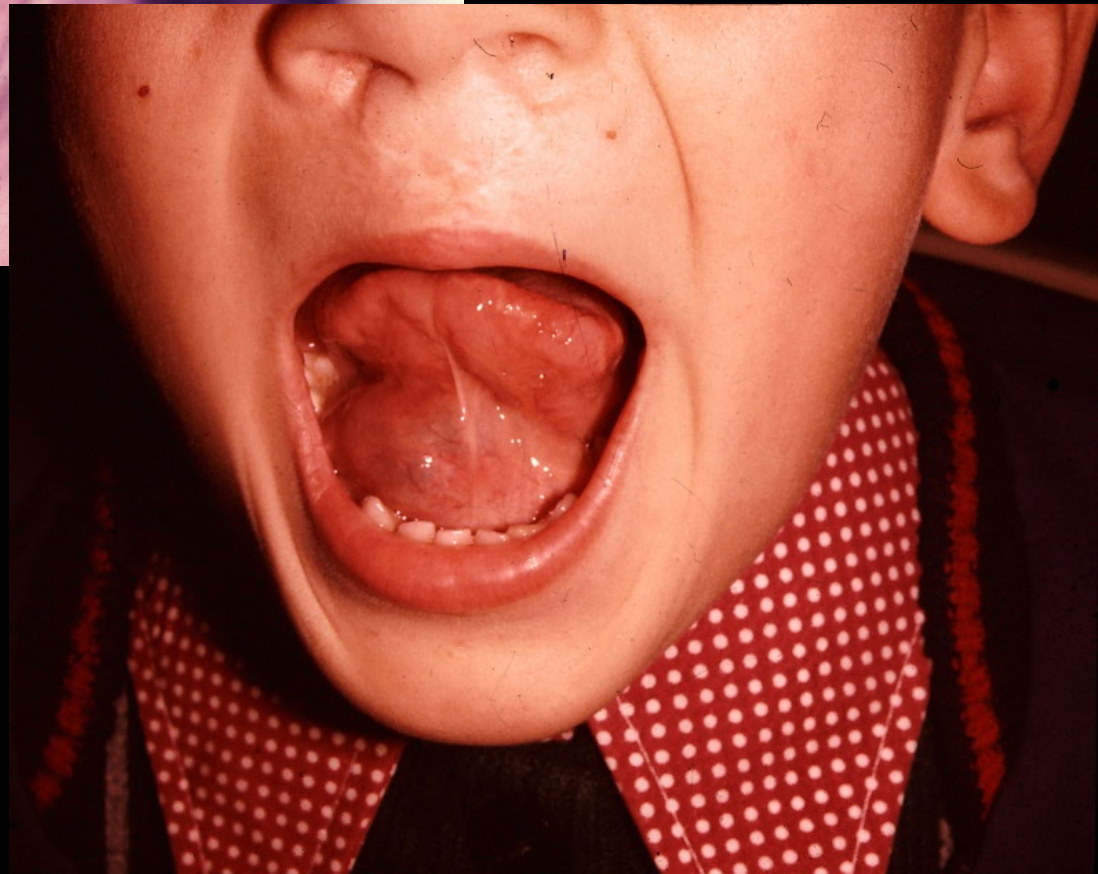
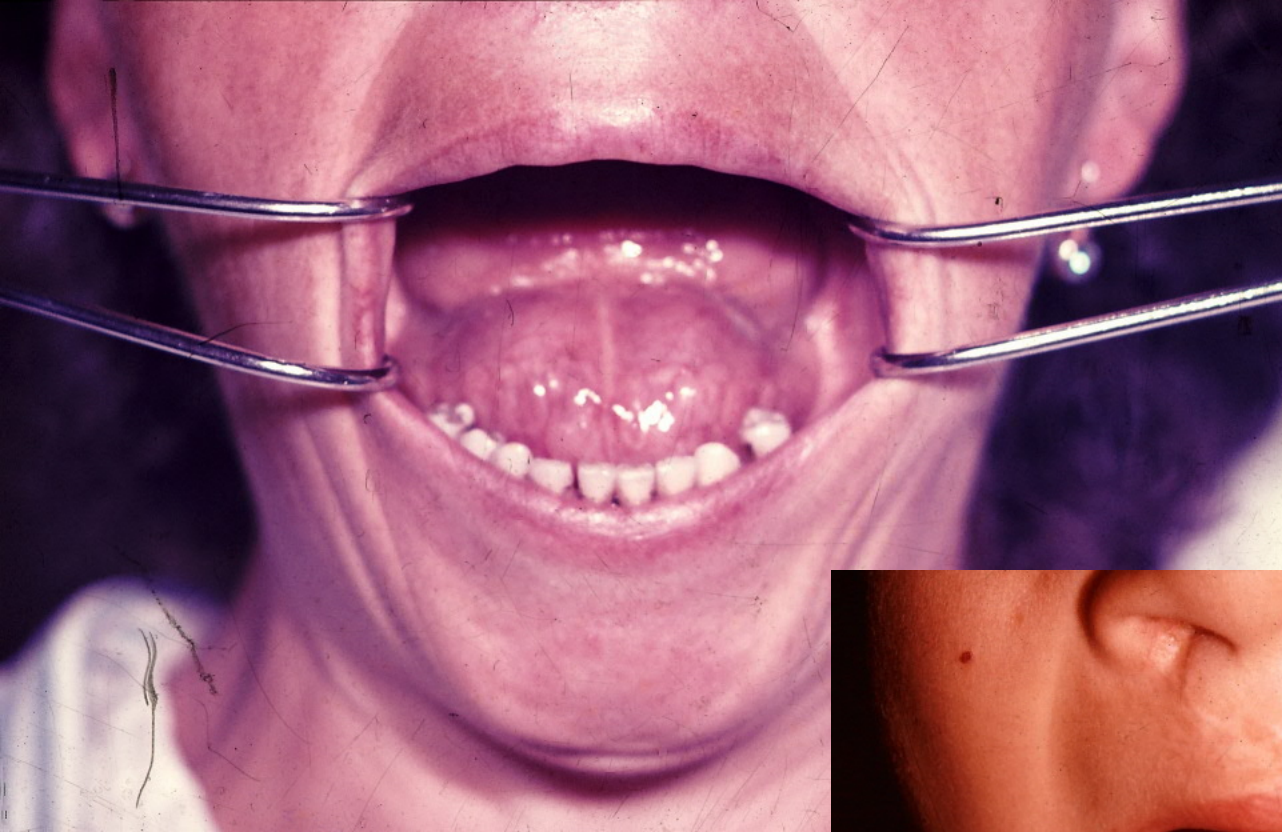


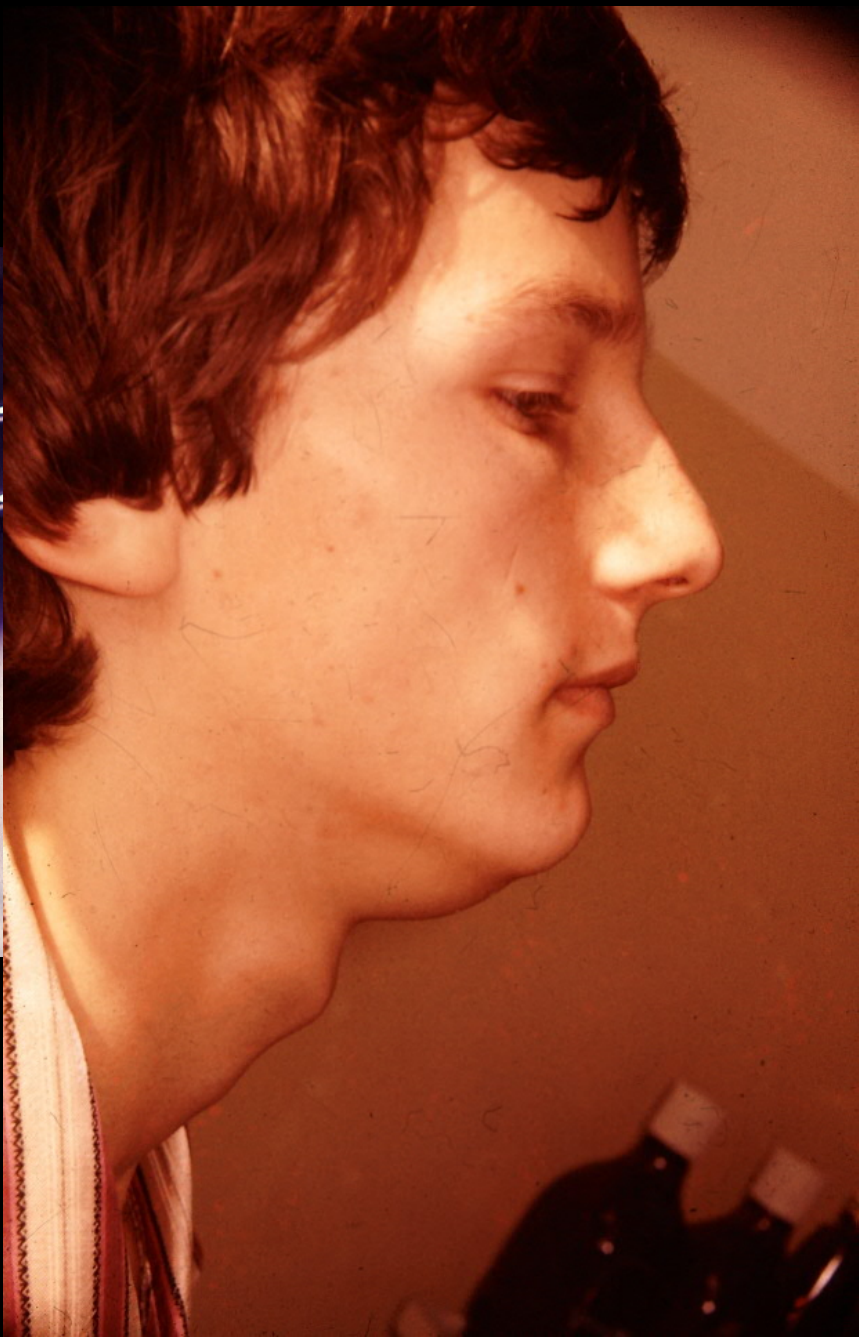
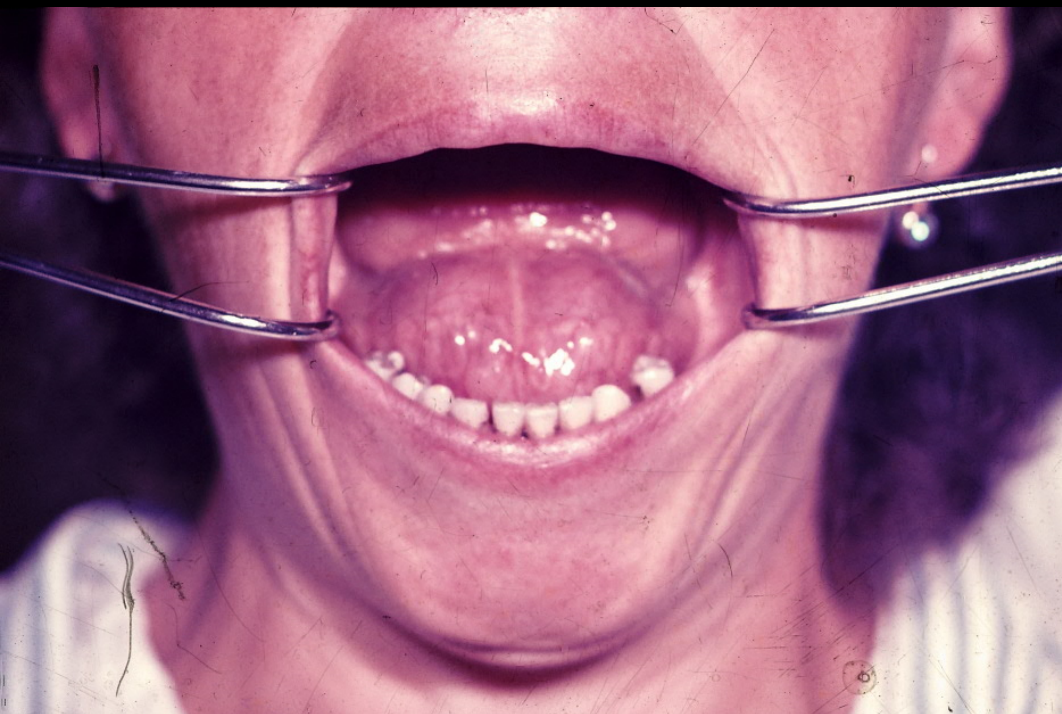




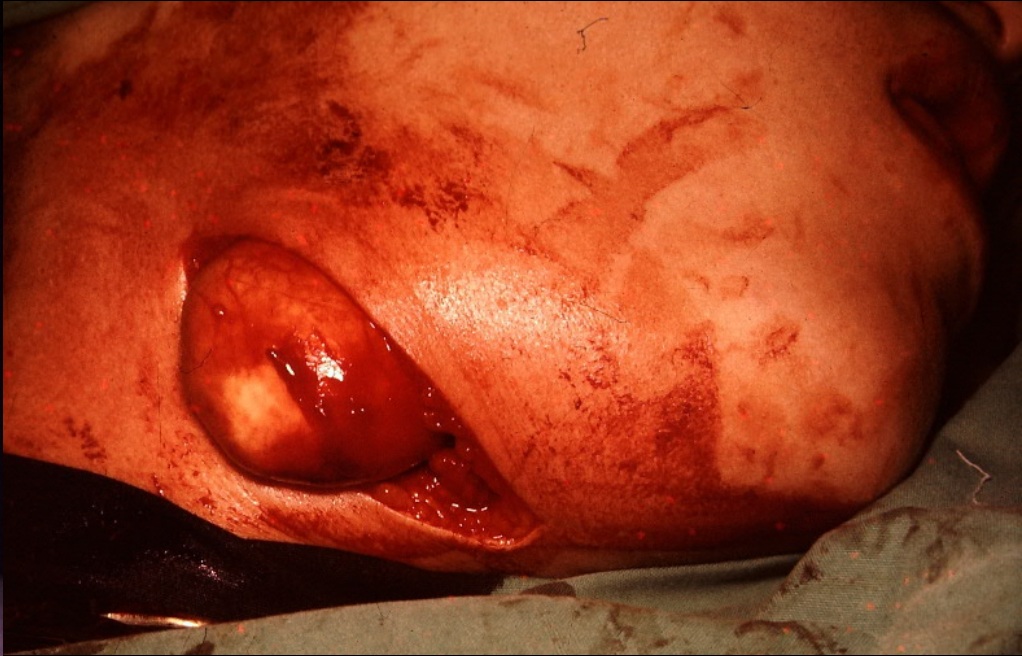
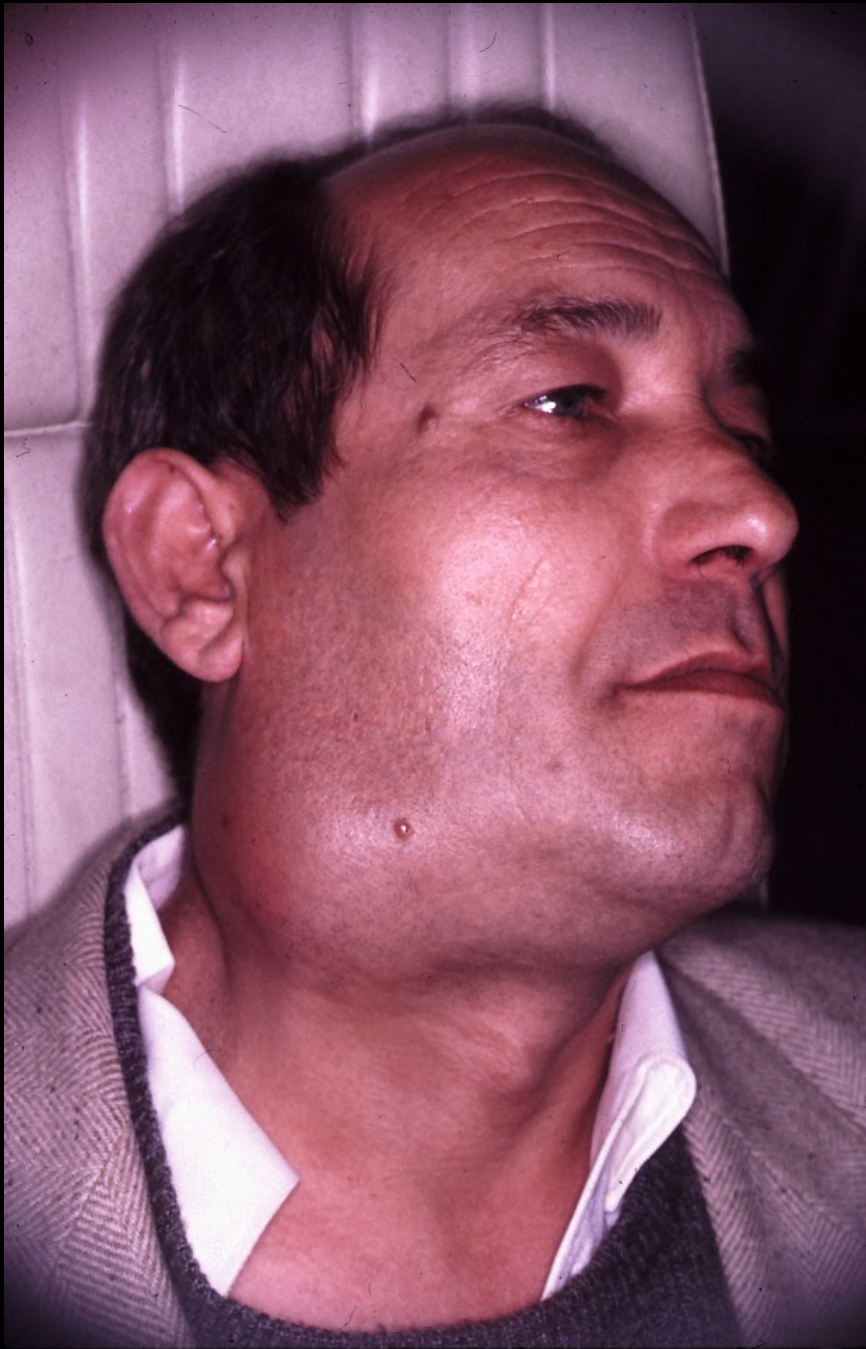




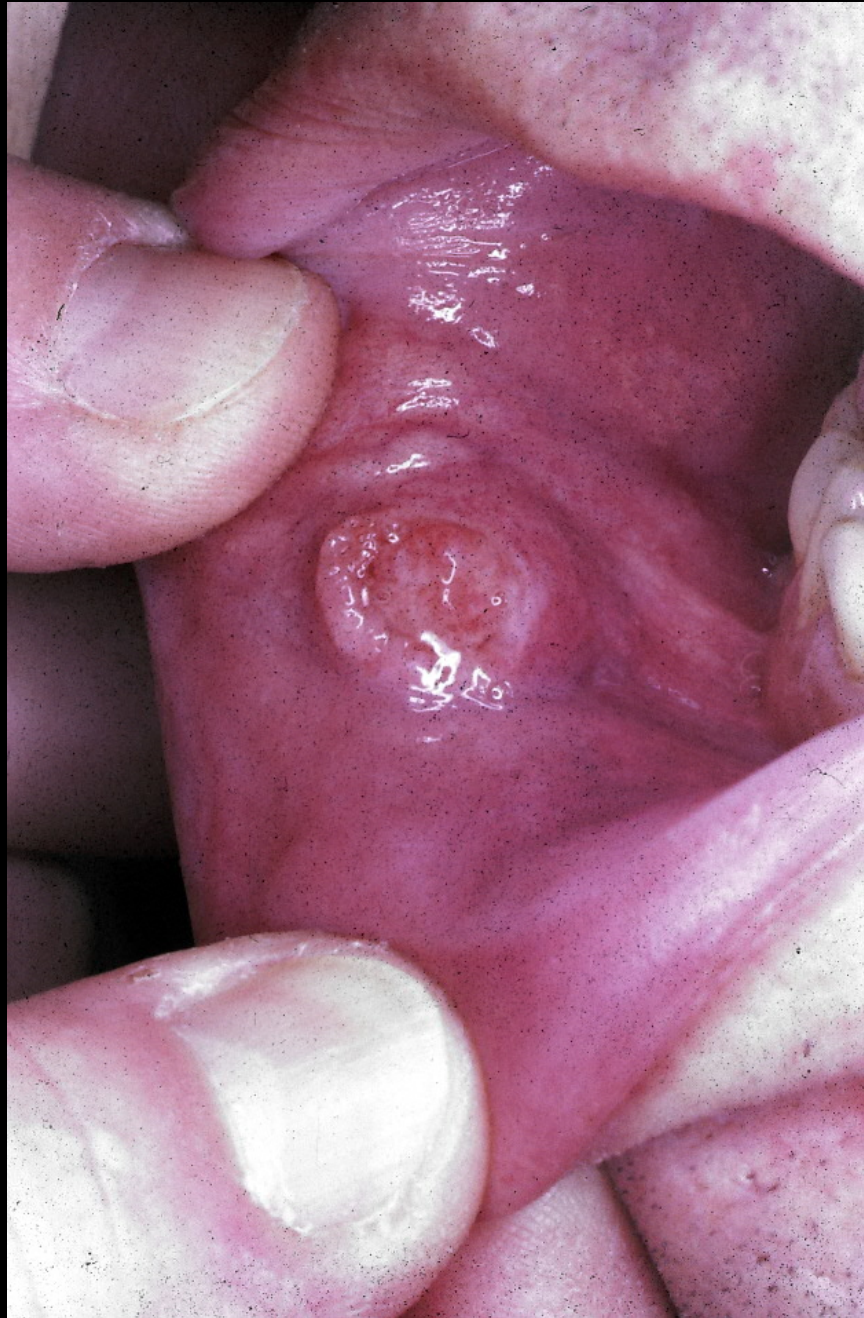





# **BENIGNA LIMFOEPITELIJALNA LEZIJA (BLL) – *mioepitelni imuni sialoadenitis***

- asimptomatsko povečanja žlijezda, hiposialija, ev. superponirana infekcija
- patognomonični nalaz su otoci mioepitelnih stanica
- sekundarno – kod sustavnih bolesti
  
- SOLITARNA
- MIKULICZEVA BOLEST
- SJOEGRENNOV SINDROM



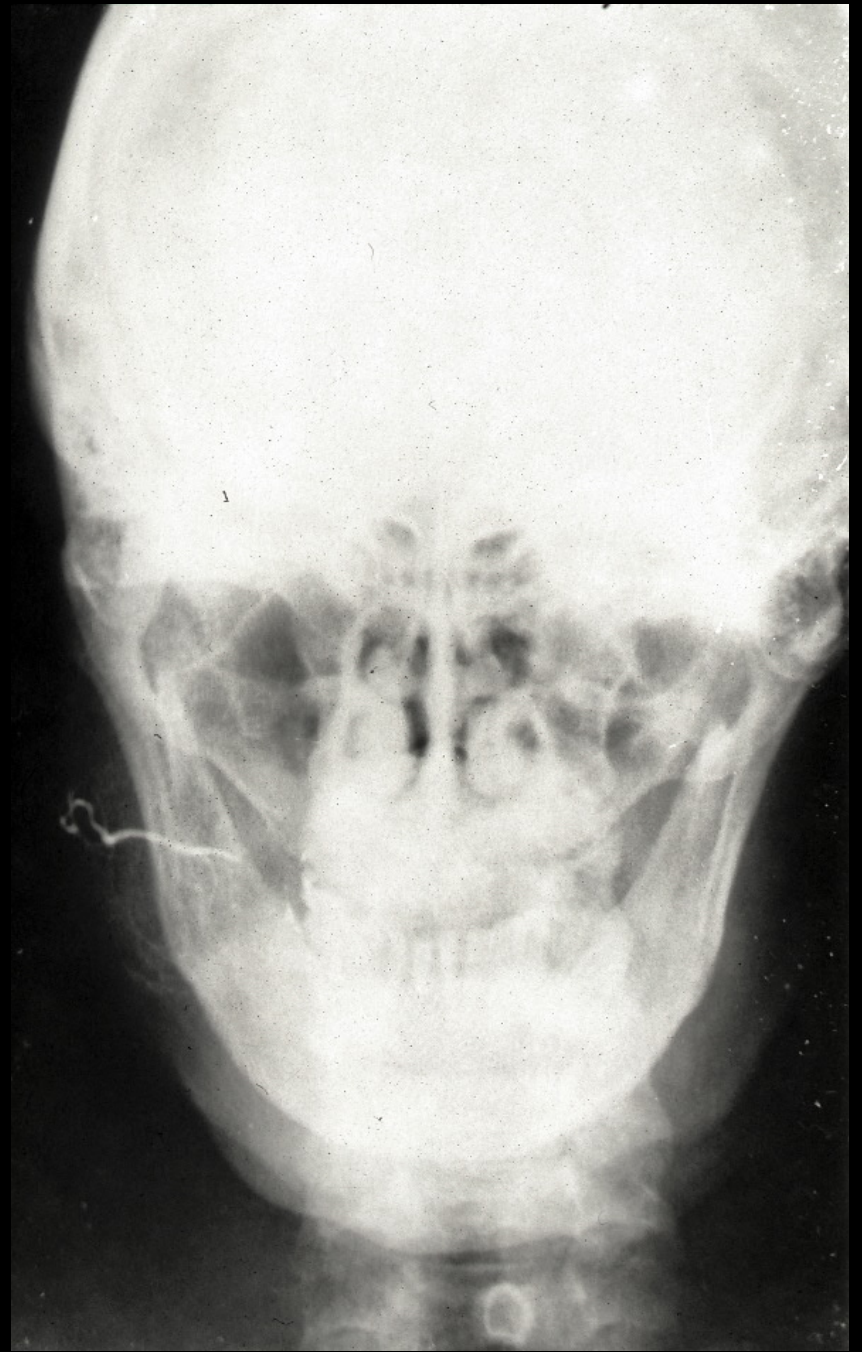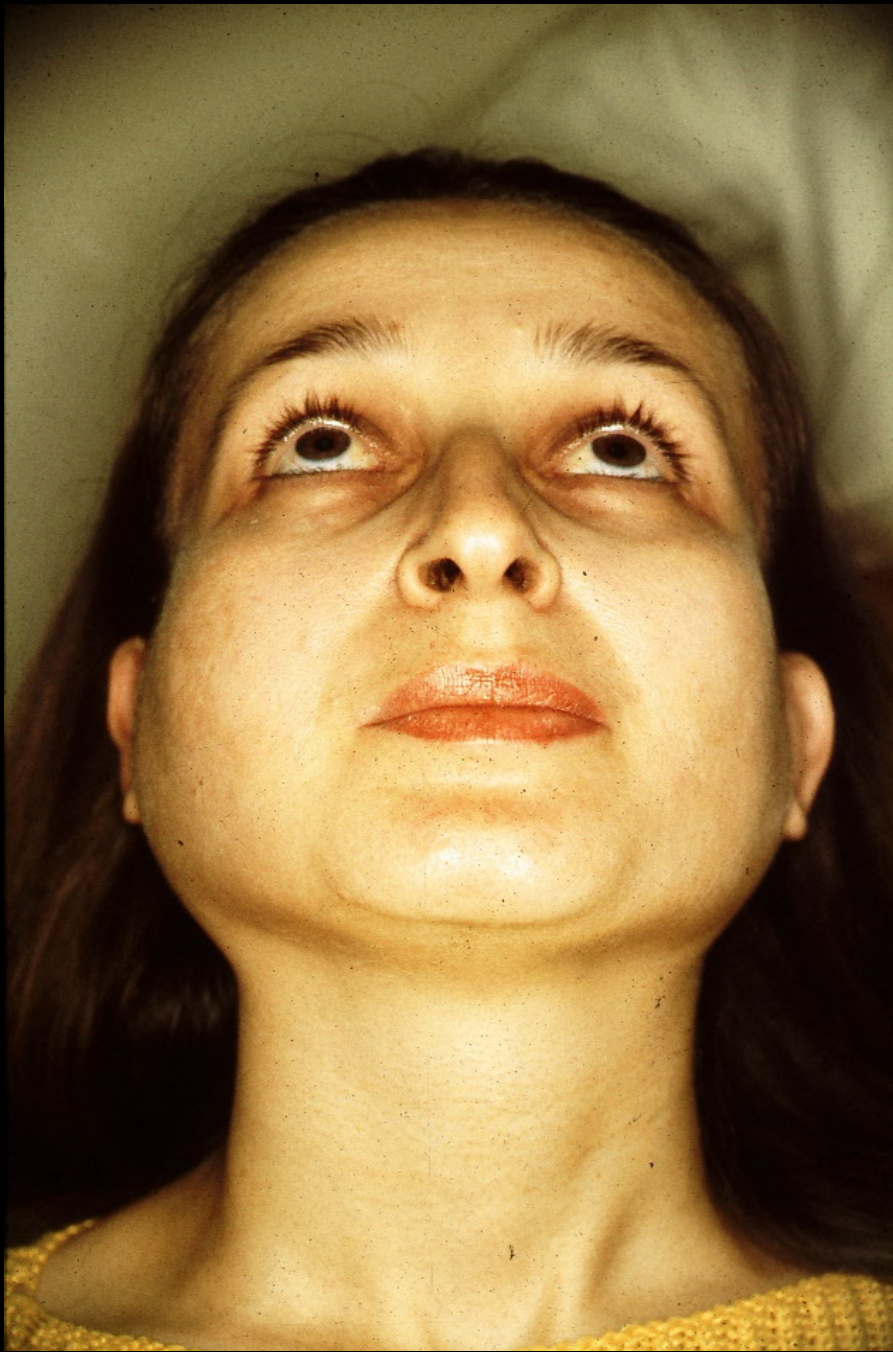# BENIGNA LIMFOEPITELIJALNA LEZIJA (BLL) – mioepitelni imuni sialoadenitis

## MIKULIČEV SINDROM

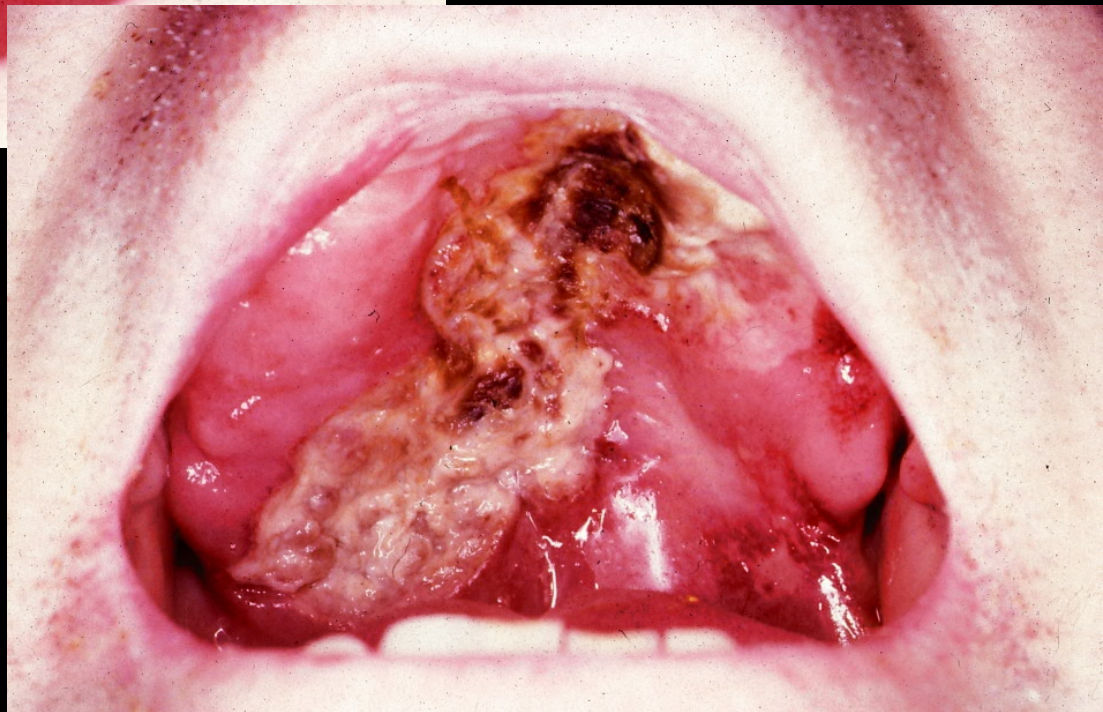
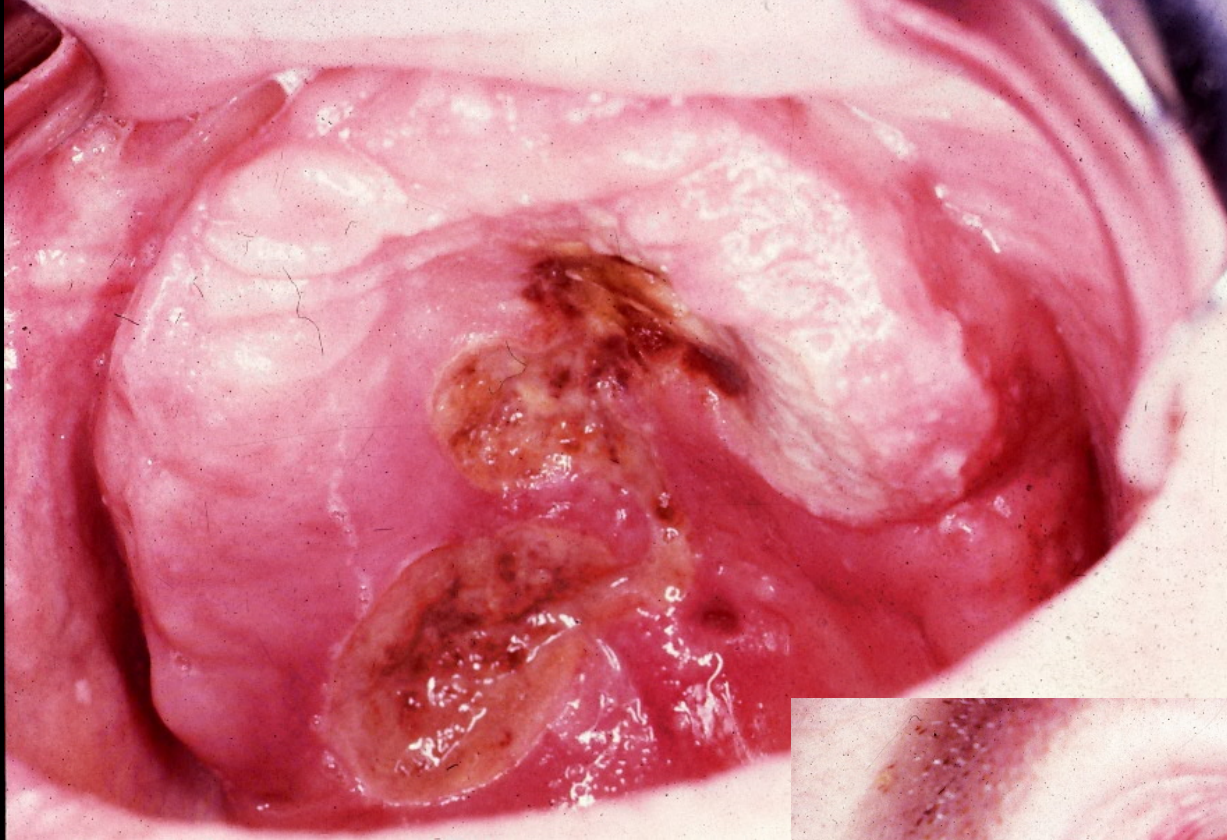
- simetrično pogodene slinovnice i suzne žlijezde
- kserostomija
- kseroftalmija

## SJOEGRENOV SINDROM

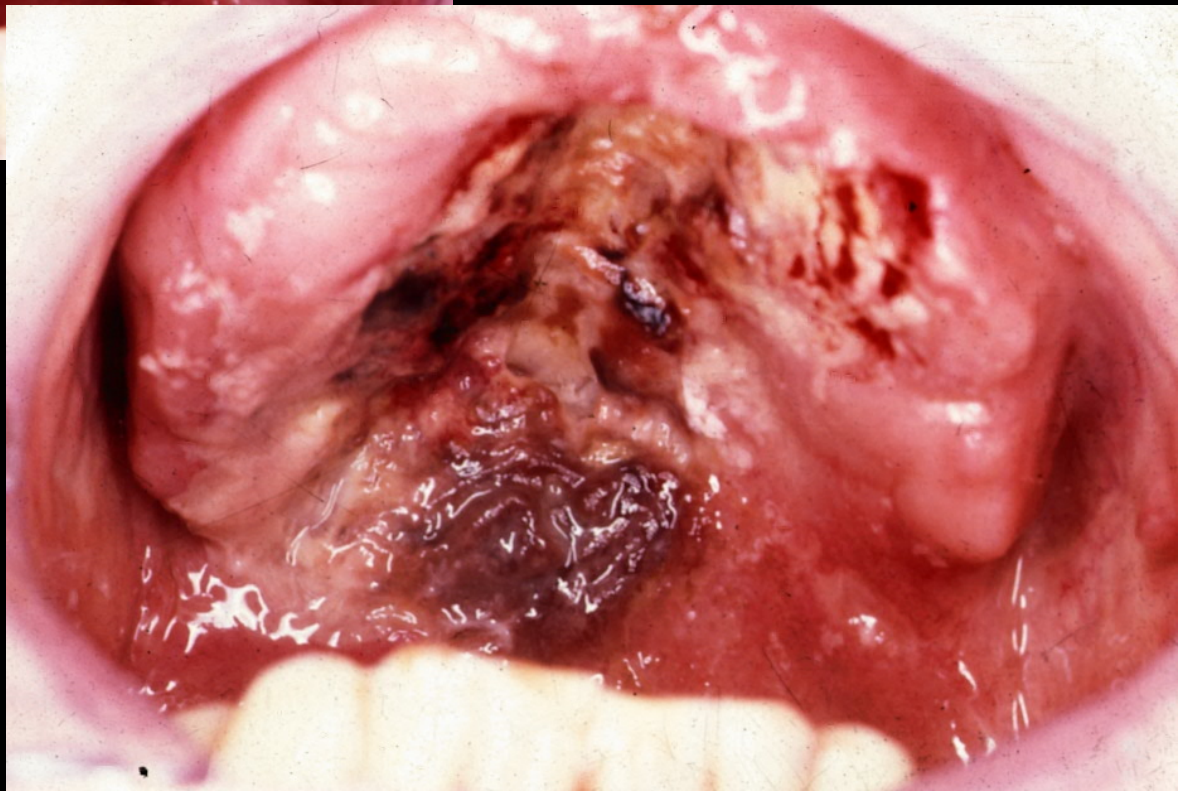
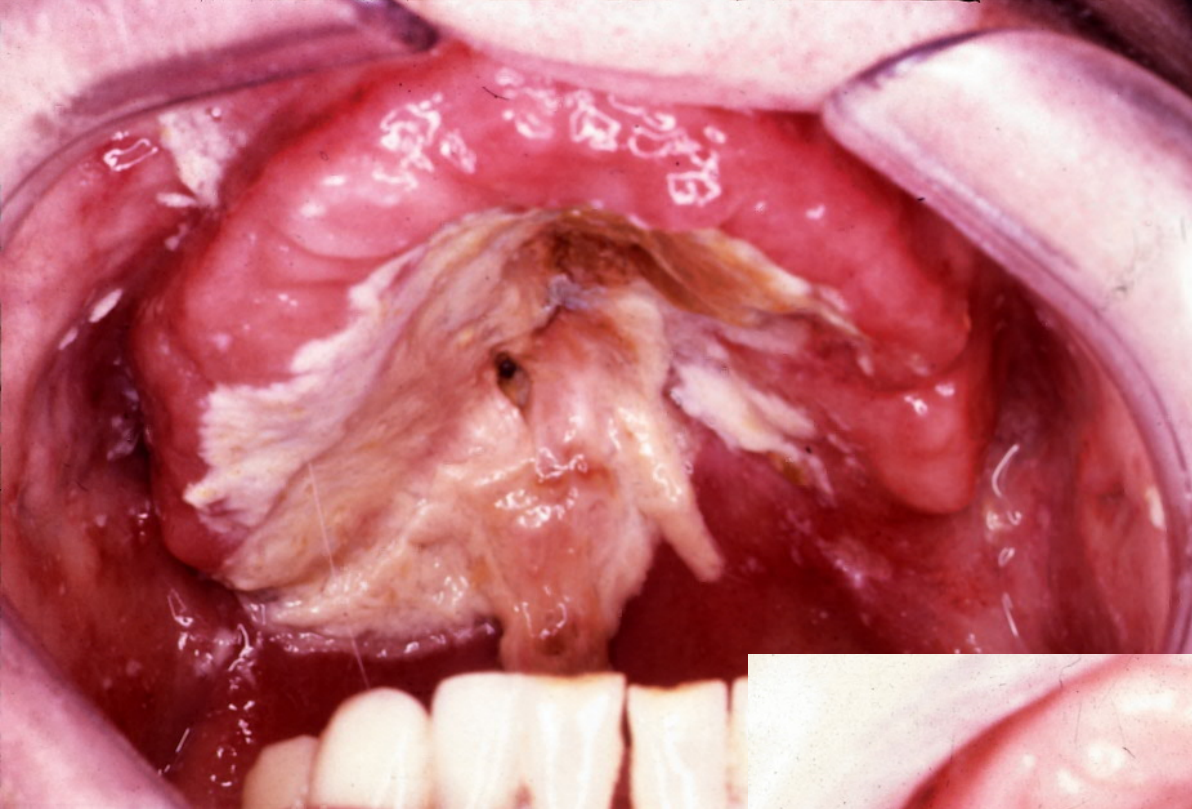
- autoimuna bolest
- velike i male slinovnice, suzne žlijezde + reumatoidni artritis *ili* lupus eritematodes
- kserostomija, keratokonjunktivitis, bronhitis
- biopsija sluznice i malih slinovnica
- th – konzervativna, kir. – kod kroničnih upala







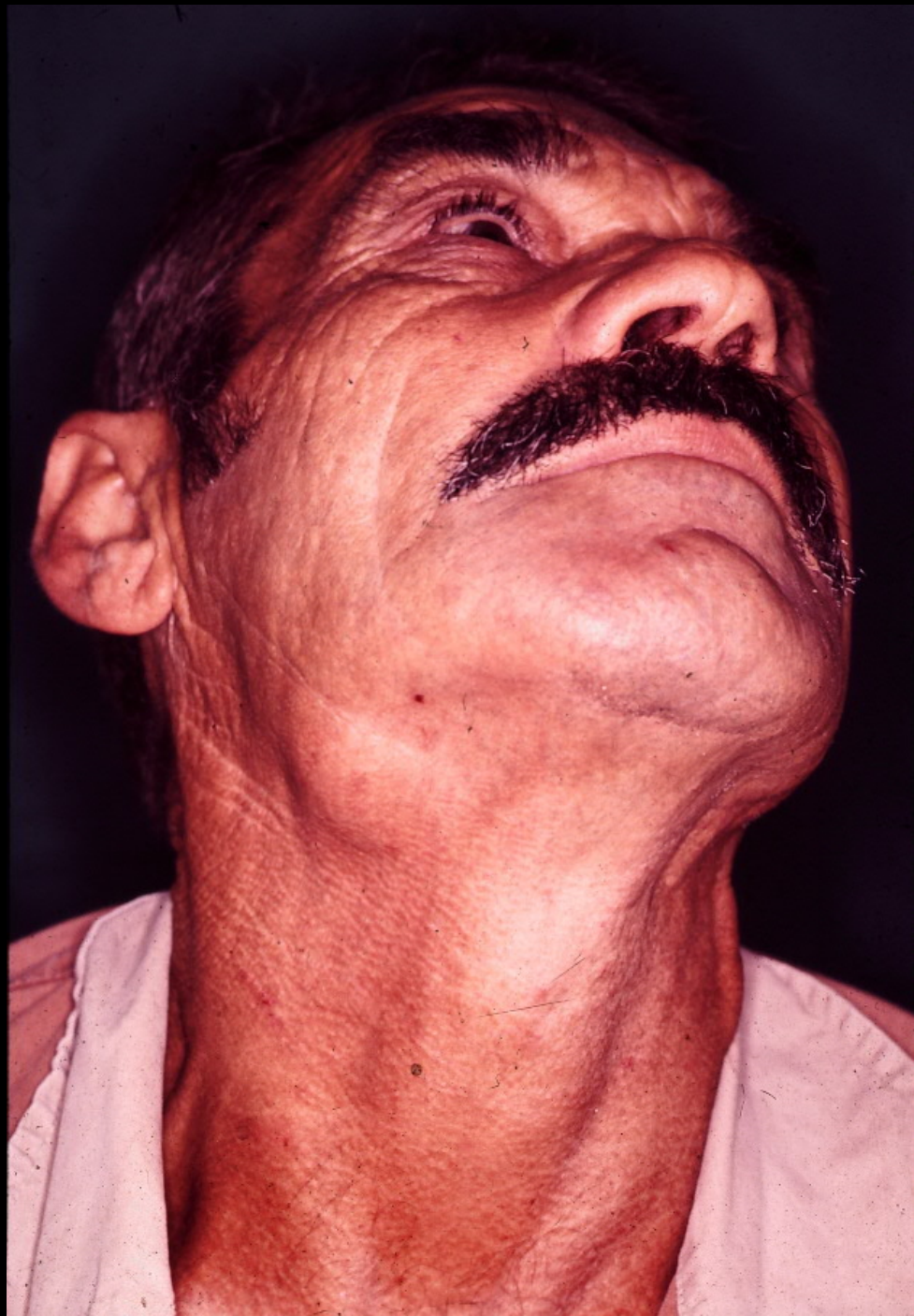



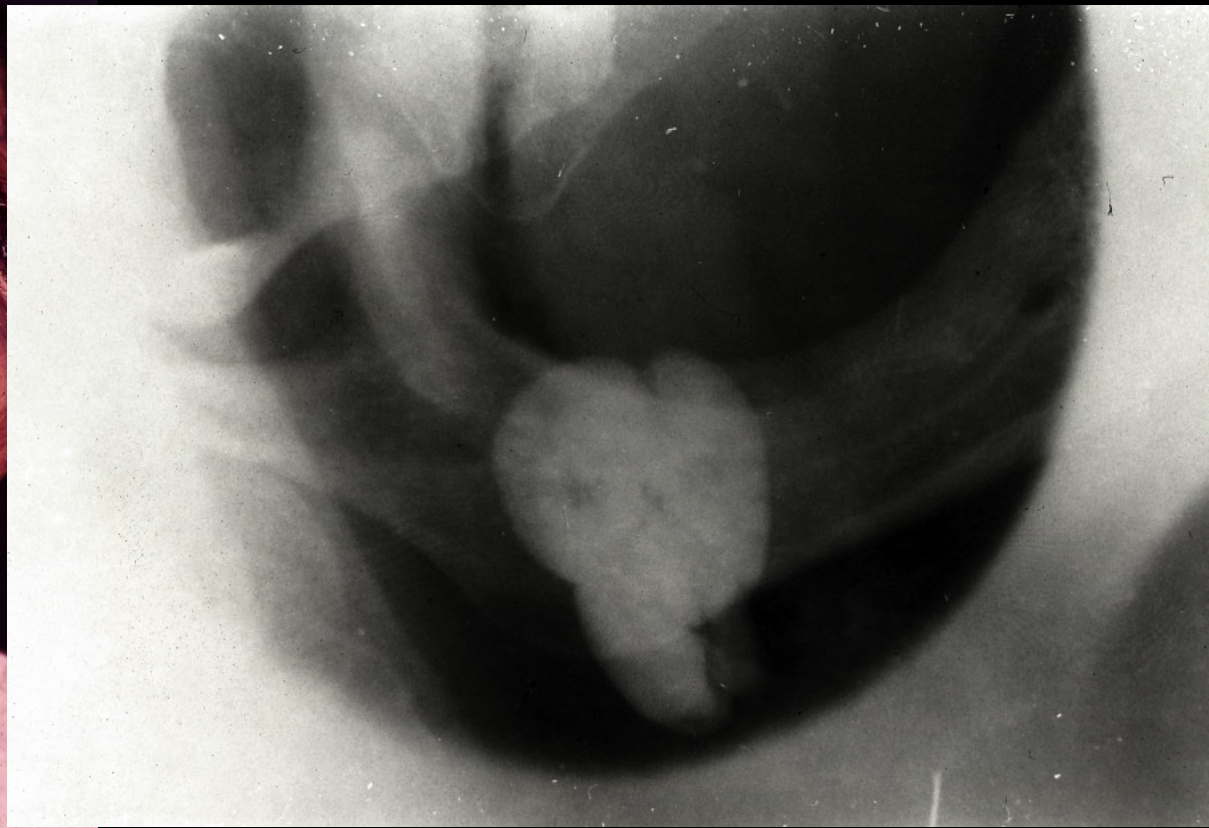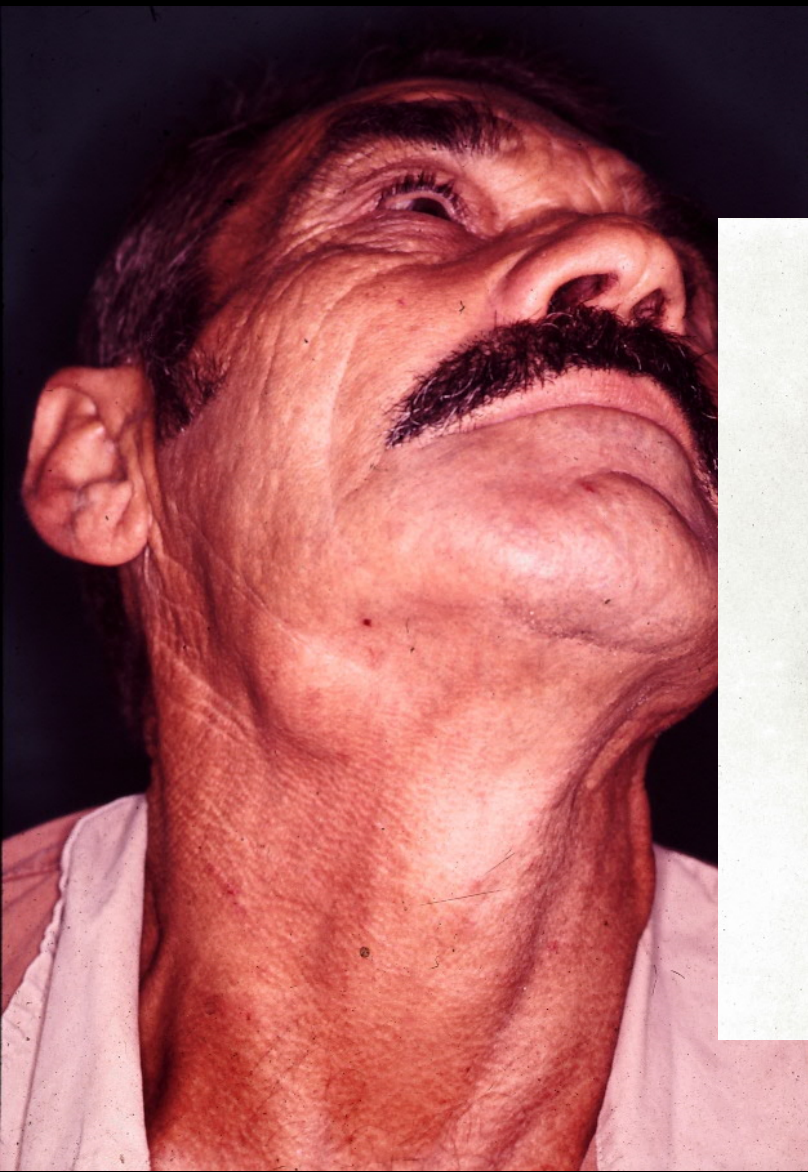


# SIALOLITIJA ZA

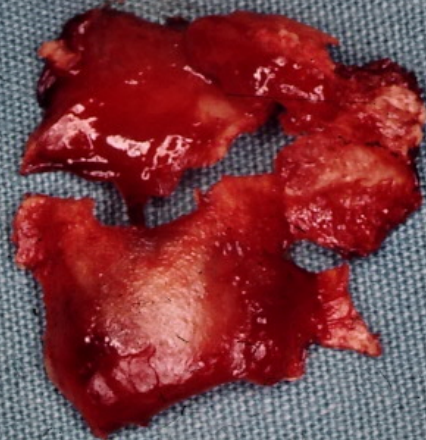
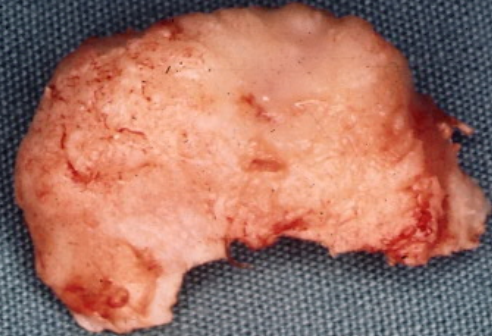
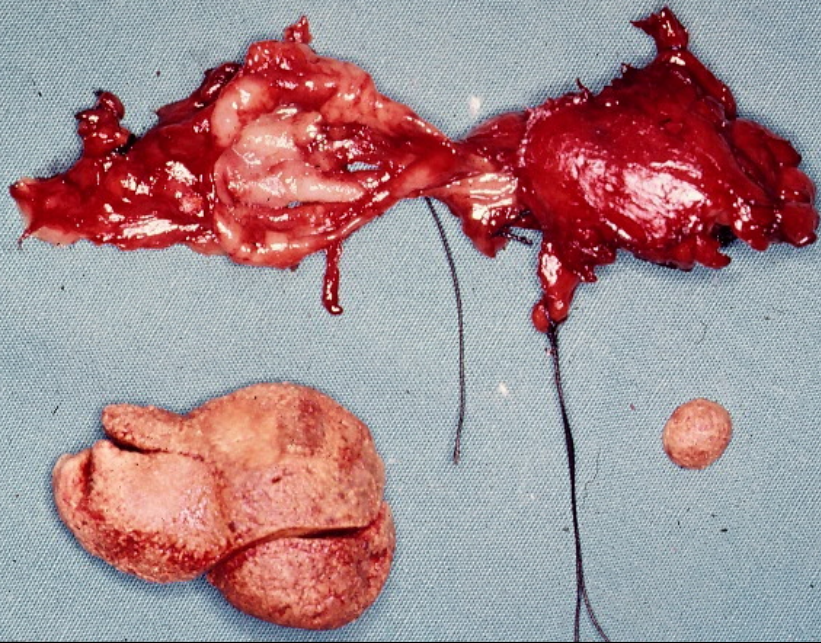

- 80% submandibularna žlijezda
- 19% parotida
- 1% sublingvalna
- izrazito rijetko malih slinovnica
- u 75% uz kronični sialoadenitis
- češće u muškaraca
- kamenac na bazi kalcij fosfata i organoskog matriksa – nastaje taloženjem oko mukoznog čepa
- često u izvodnom kanalu i opstruira izlaz sline
- često ponavljano bolno oticanje neposredno prije i za vrijeme jela
- dg: rtg – zagrizna snimka, postranična
- th: kirurška



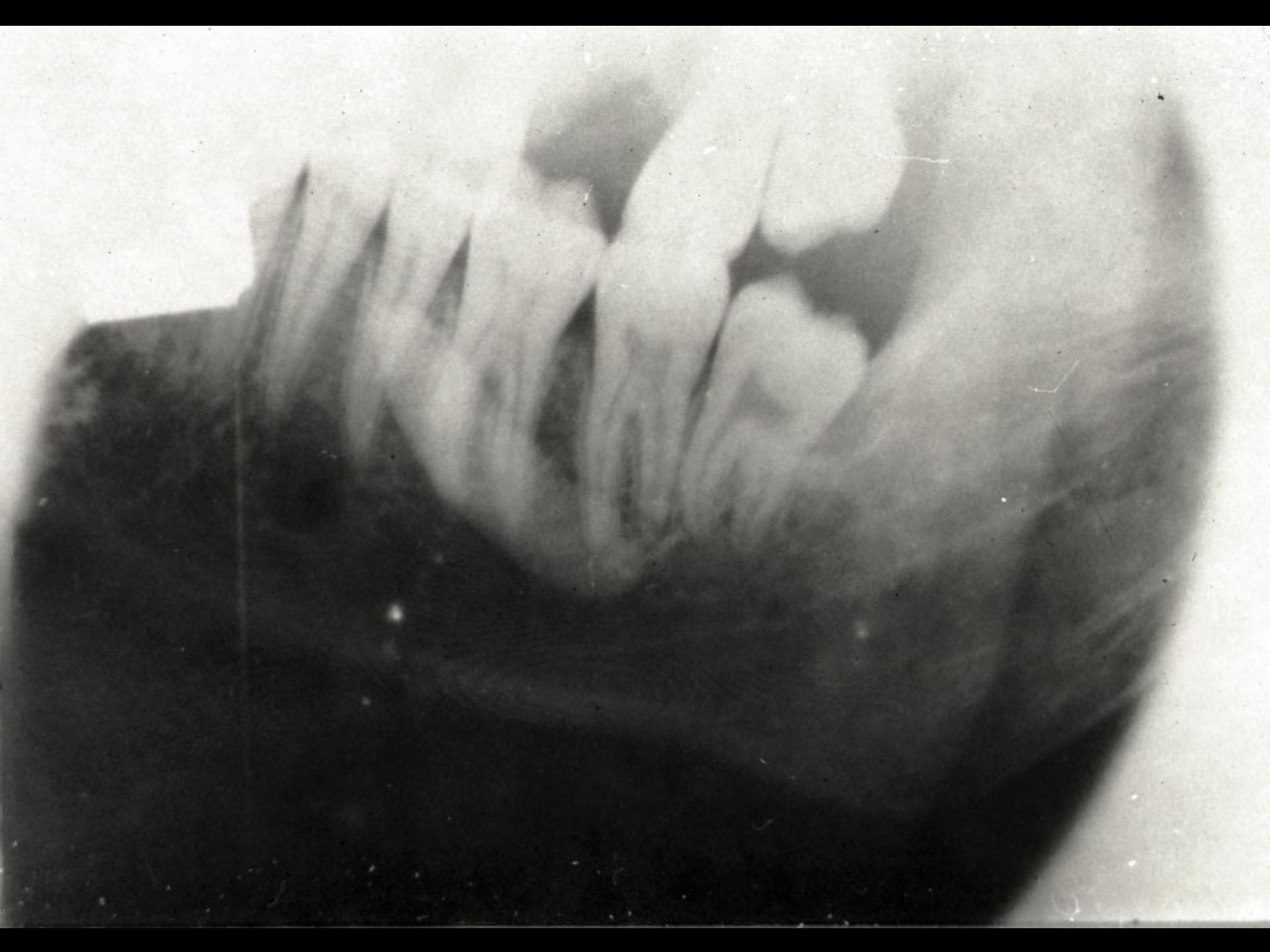



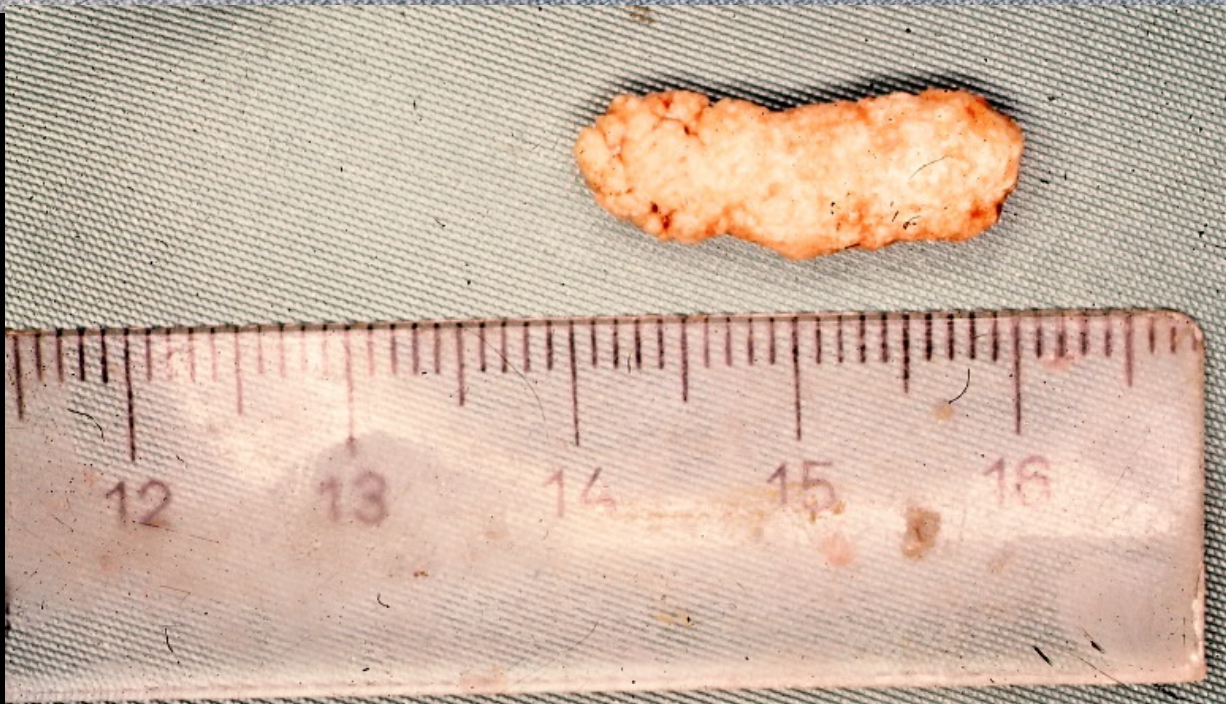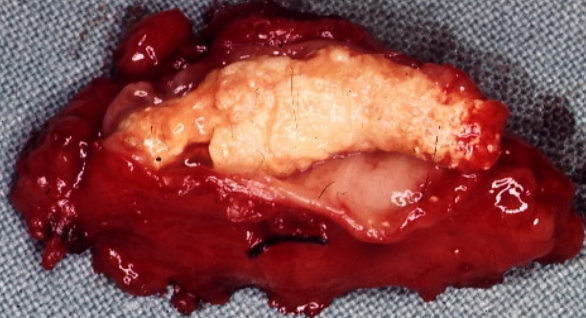


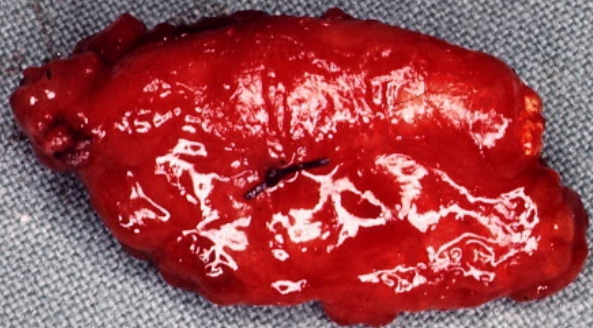



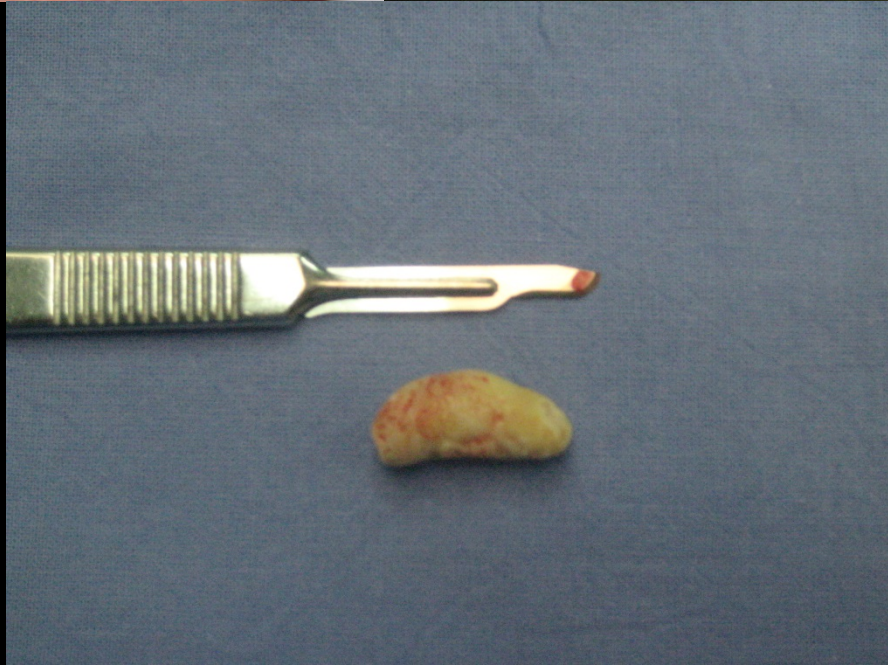
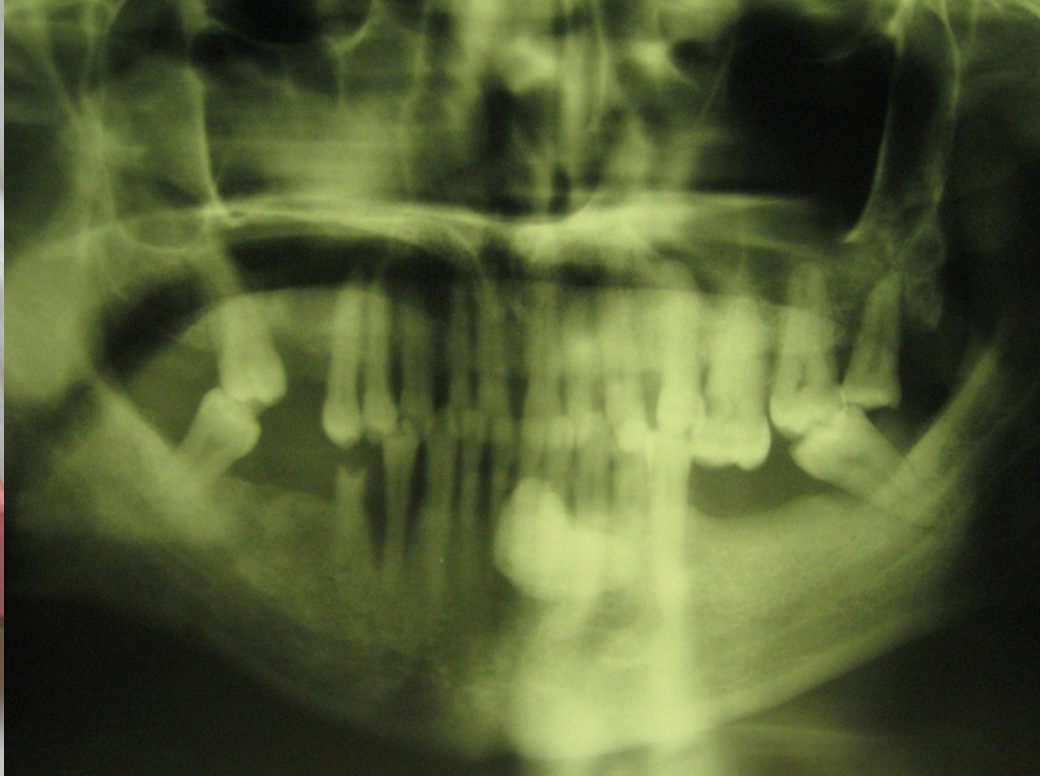

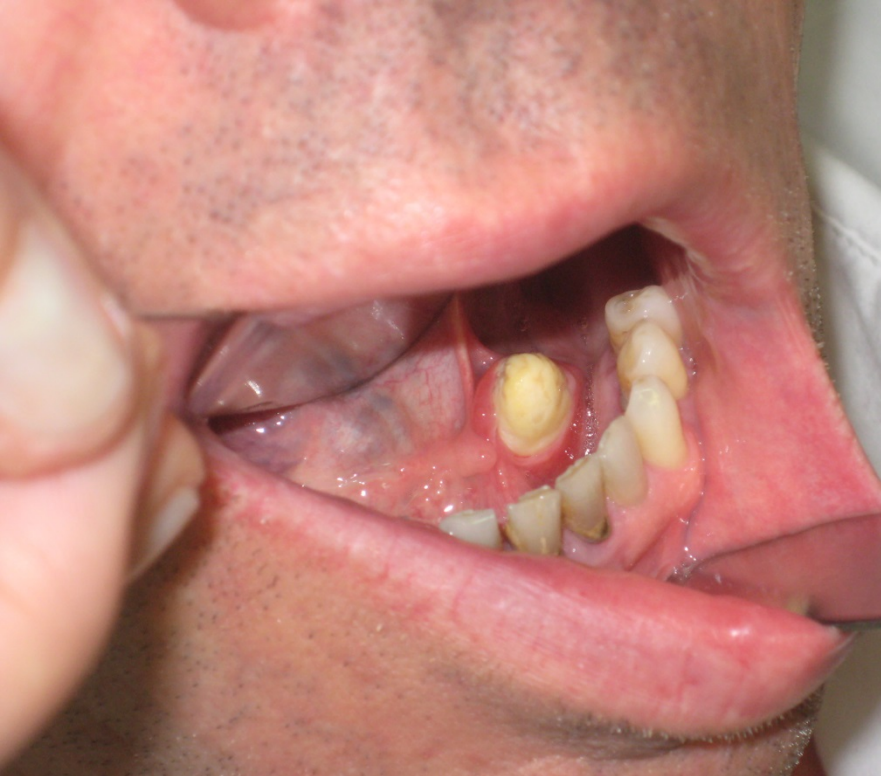




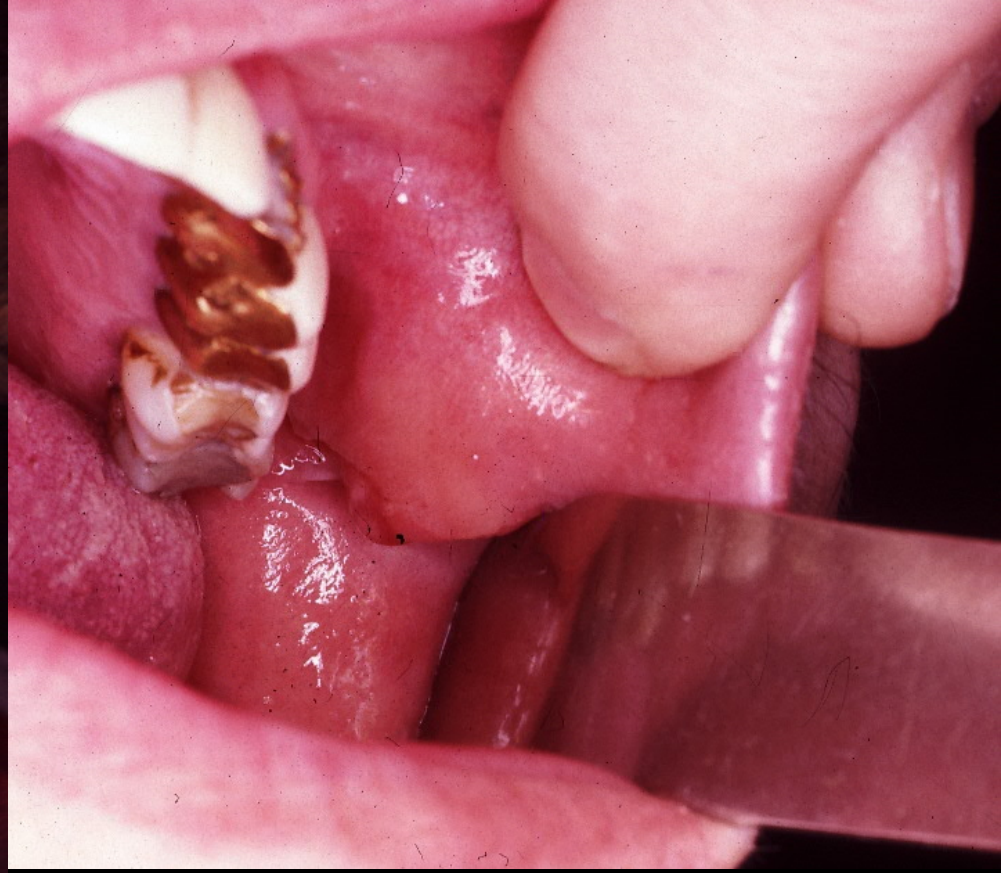
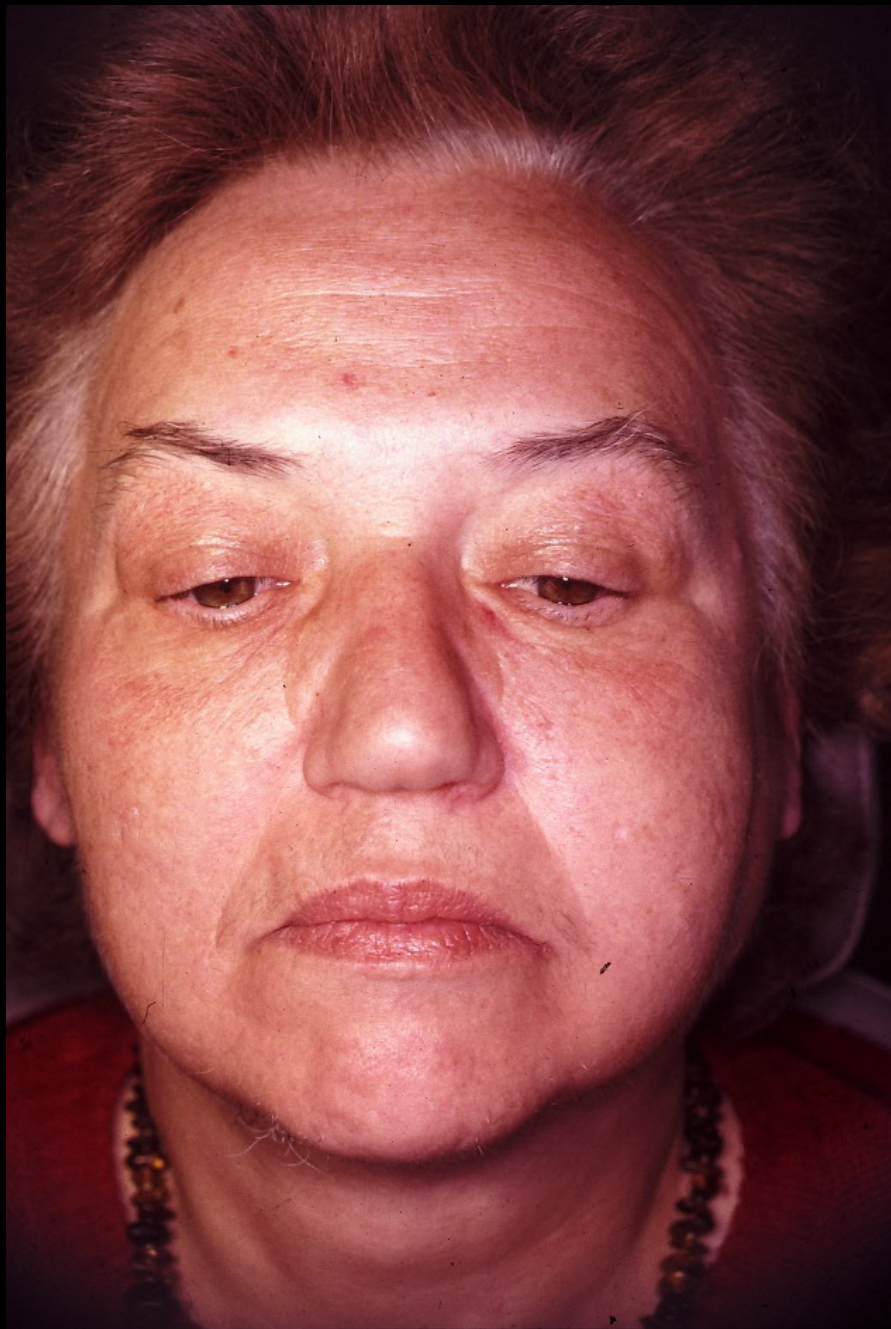




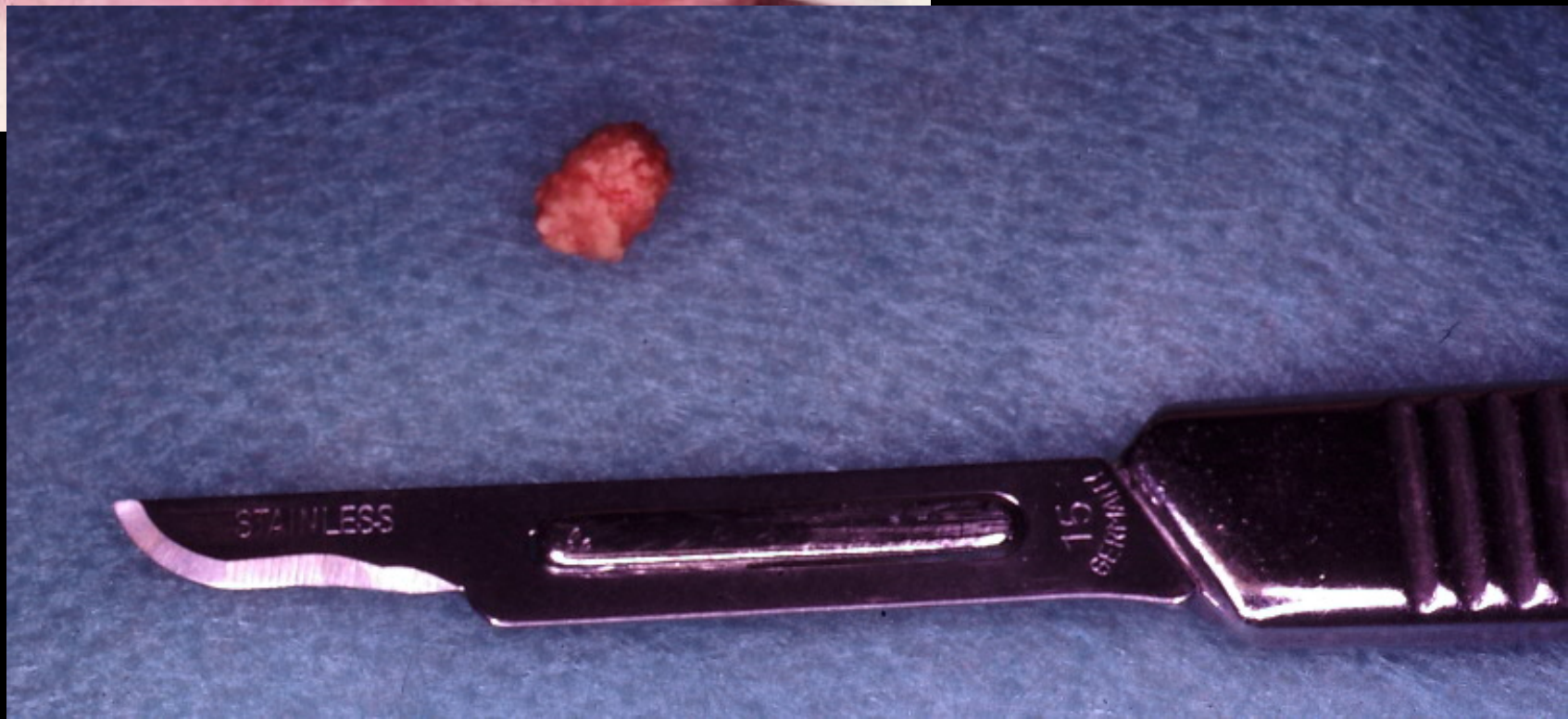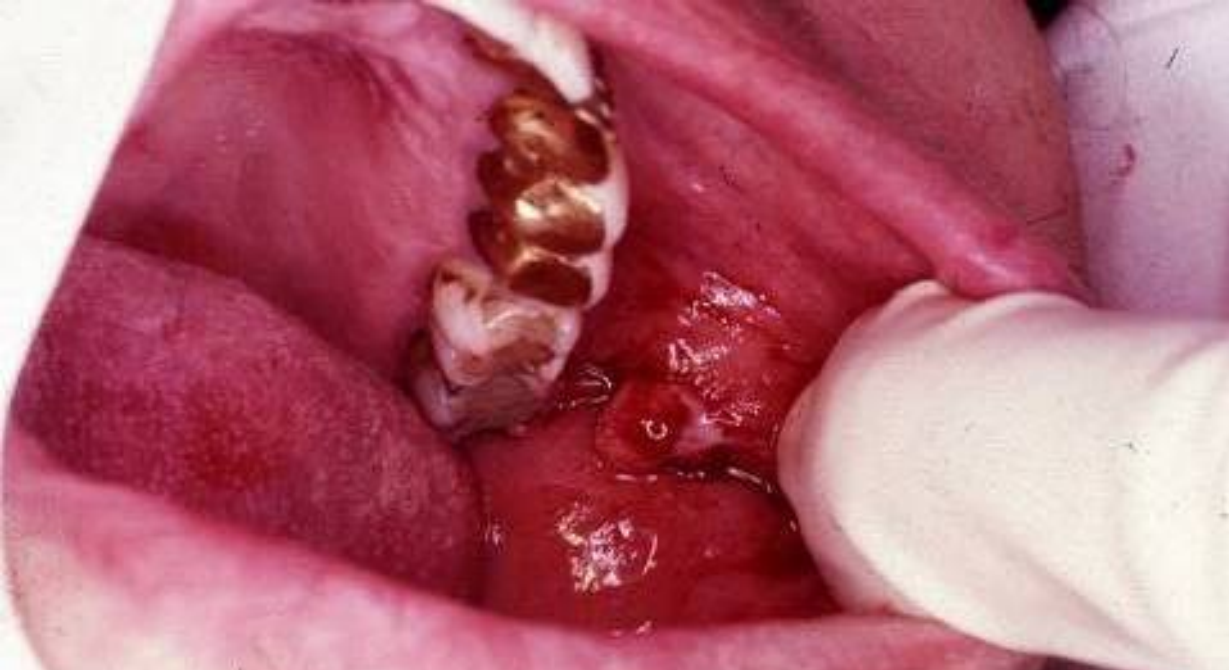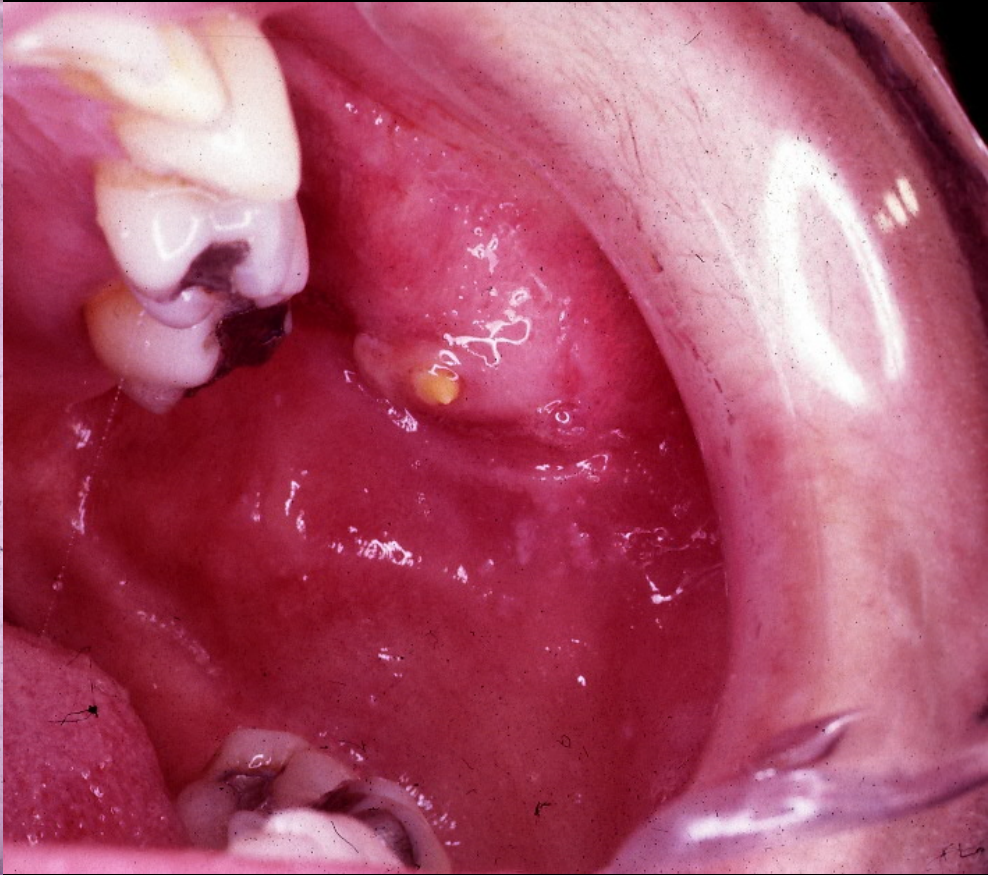




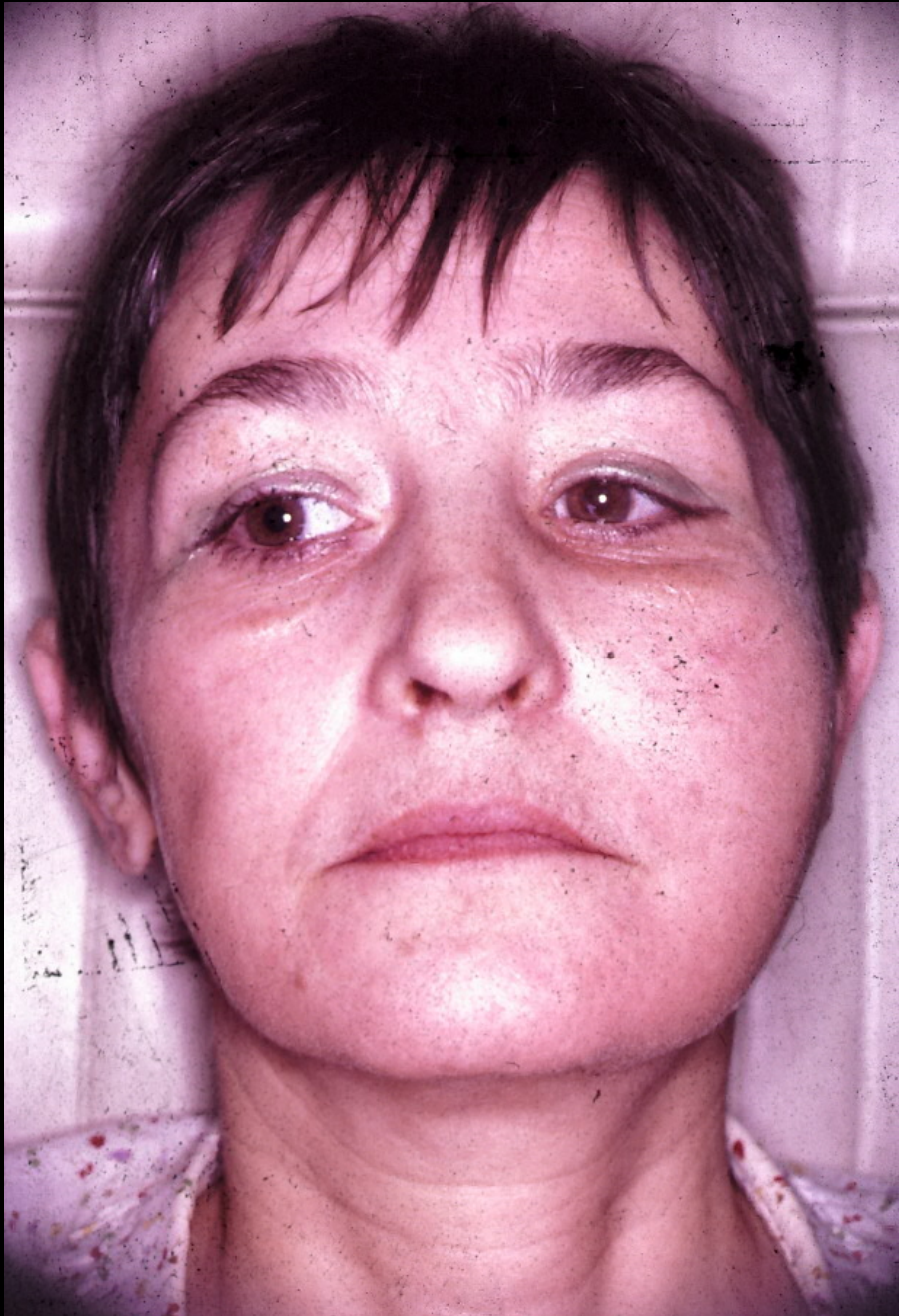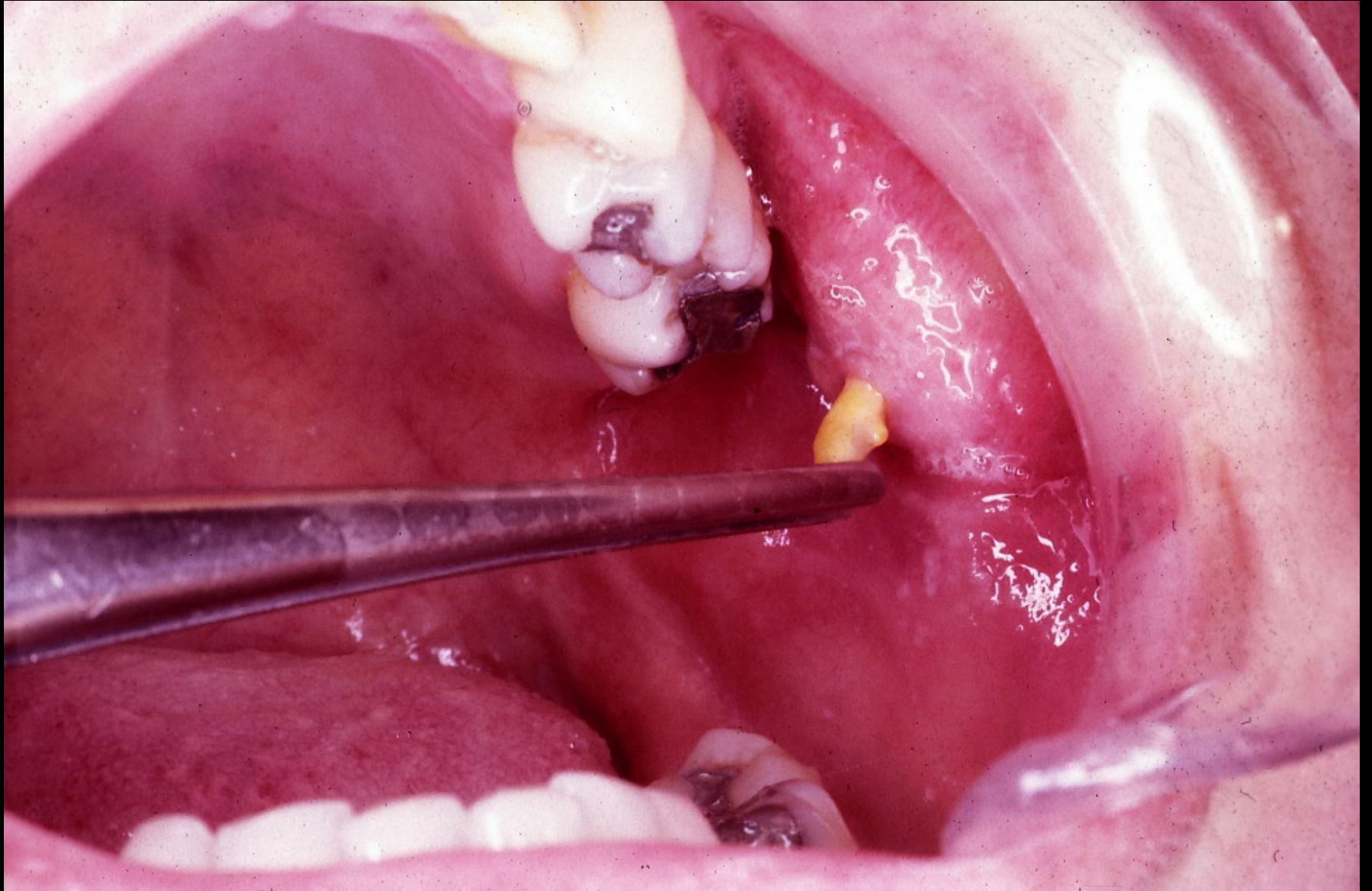








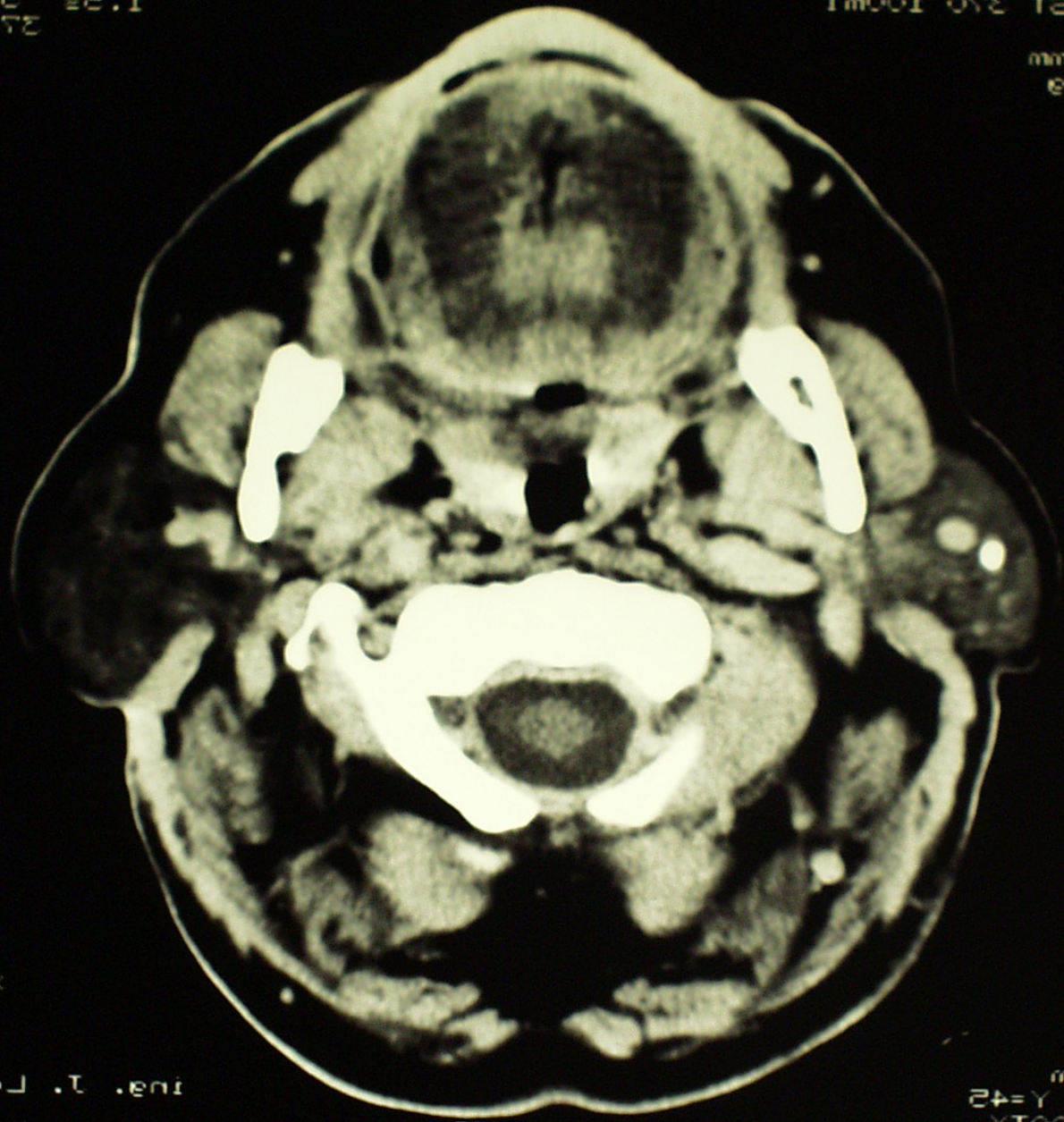




150Kv  
1.2s  
250


151 370 100m1

2mm  
1.2s

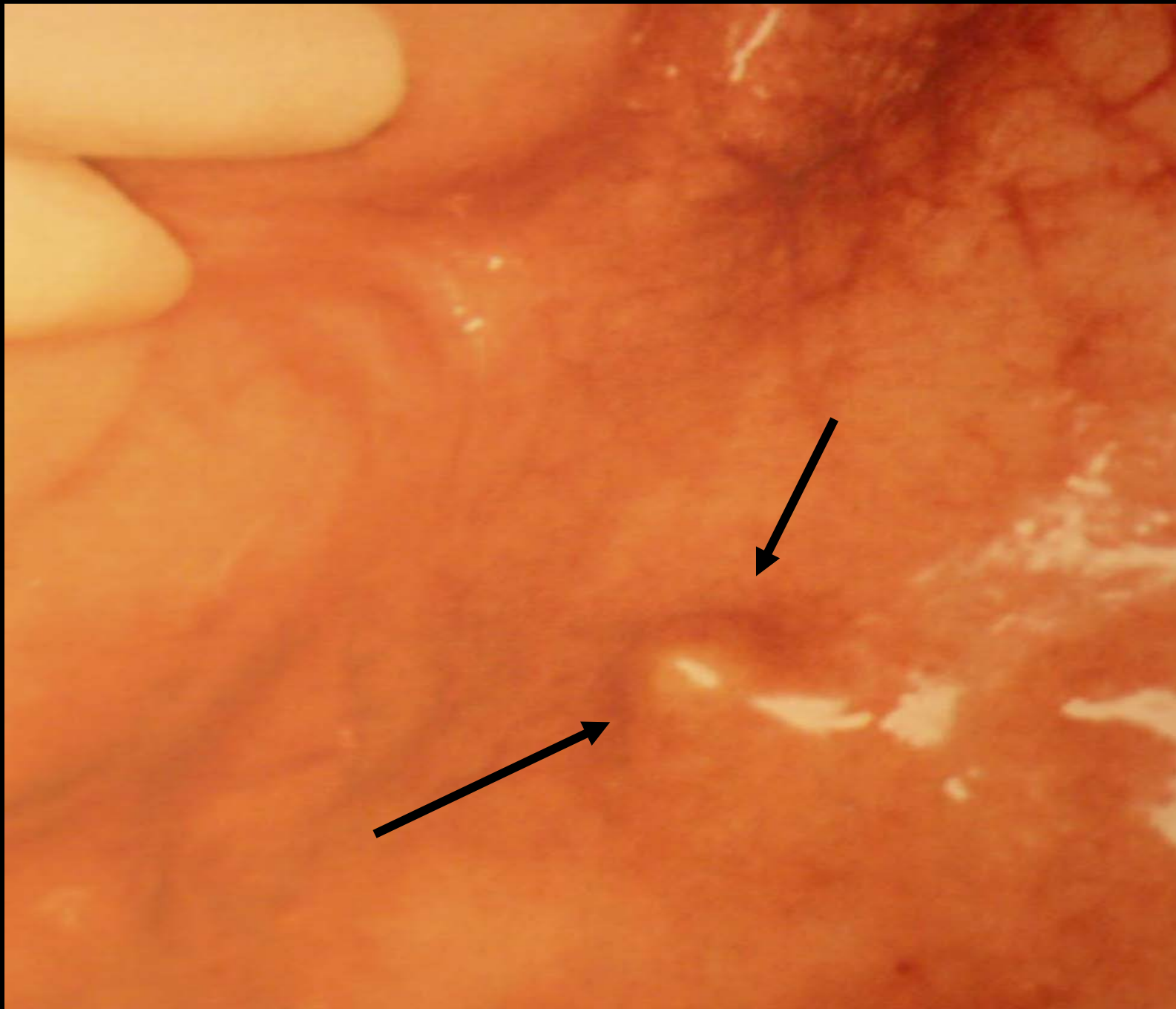



151 370 100m1  
1.2s  
250

151 370 100m1  
1.2s  
250



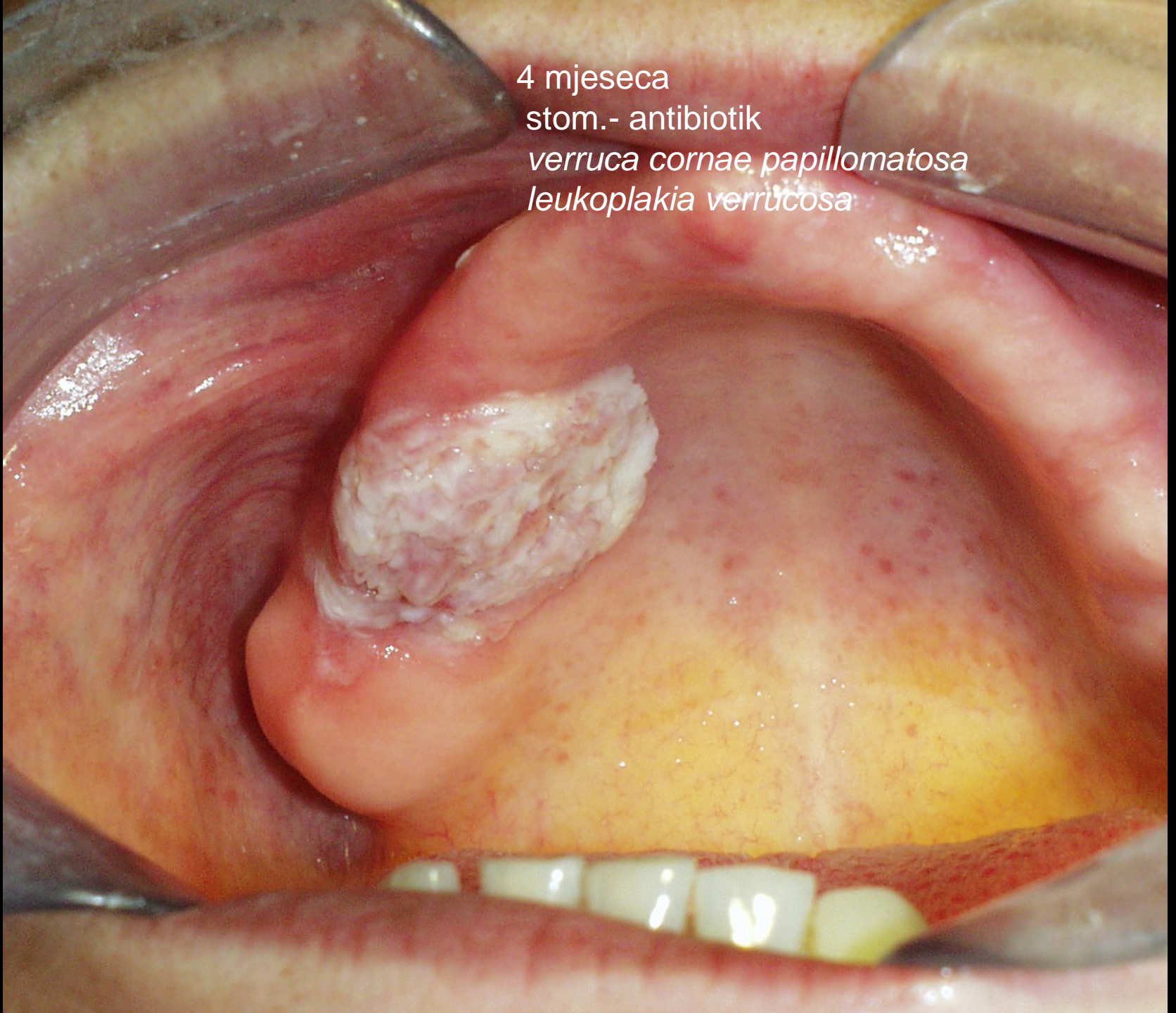




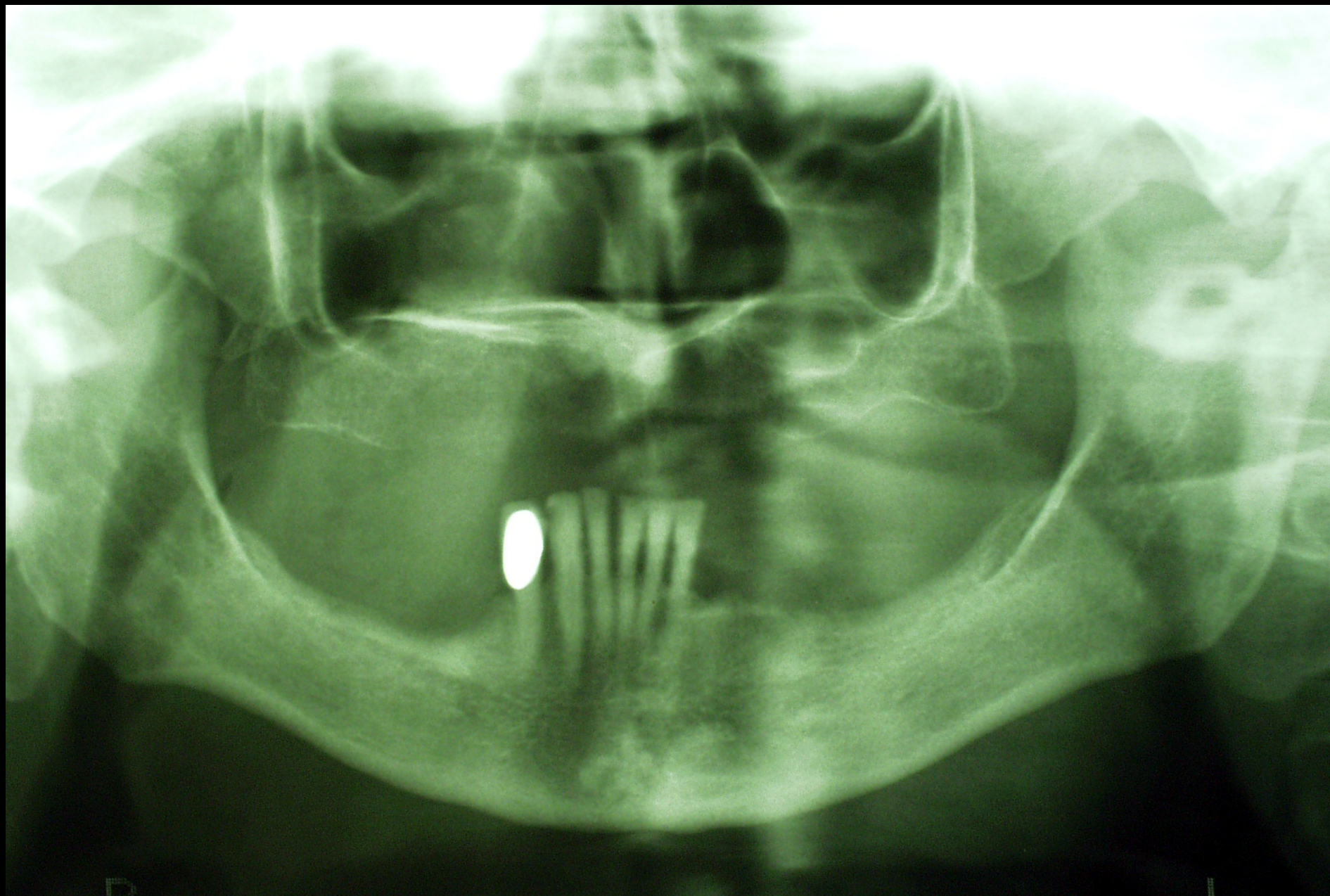




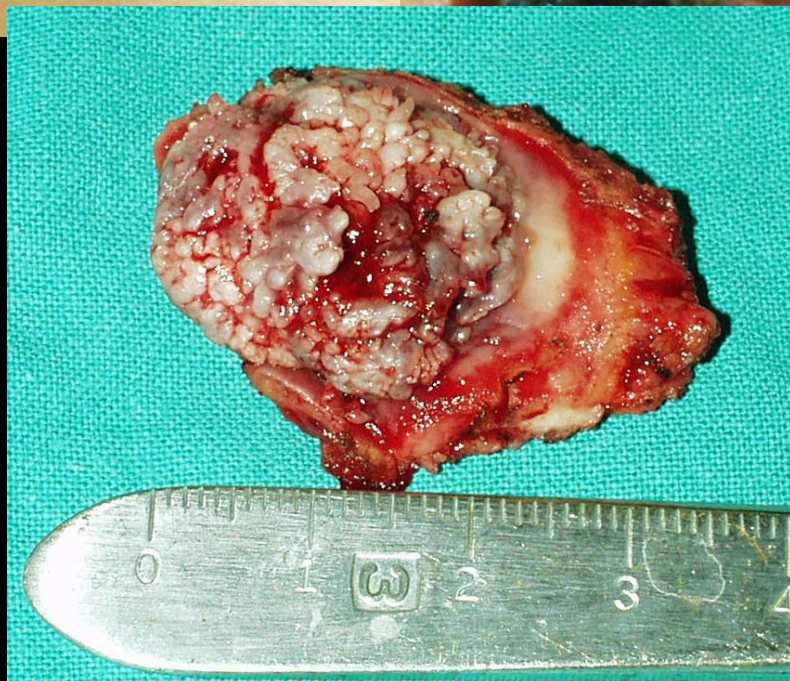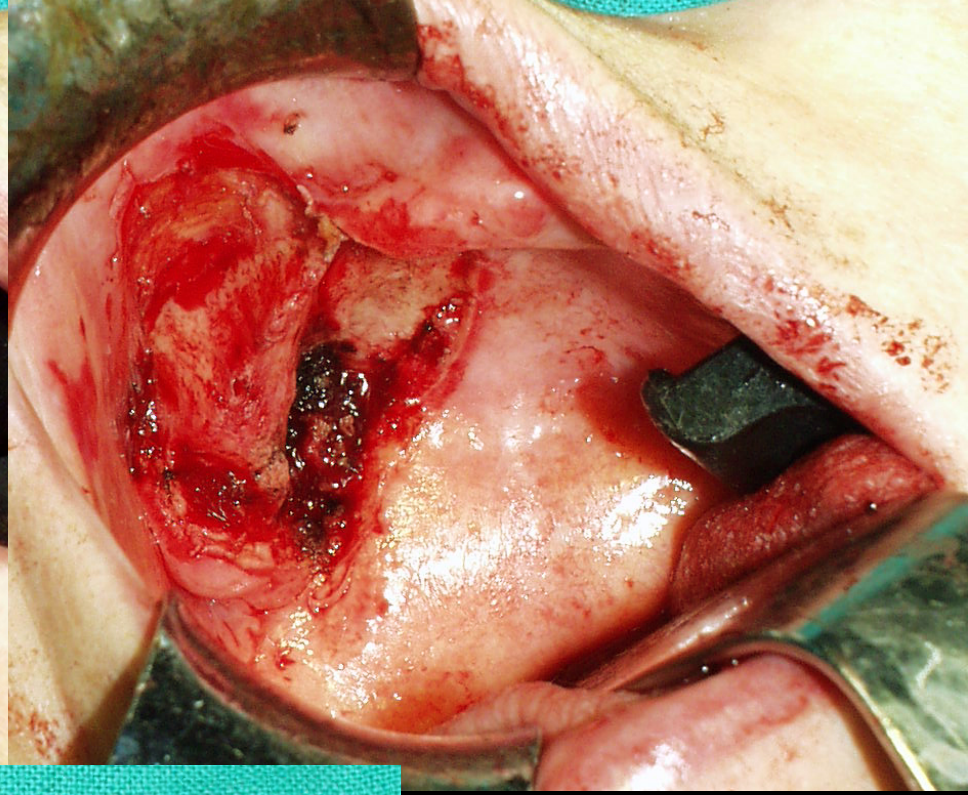
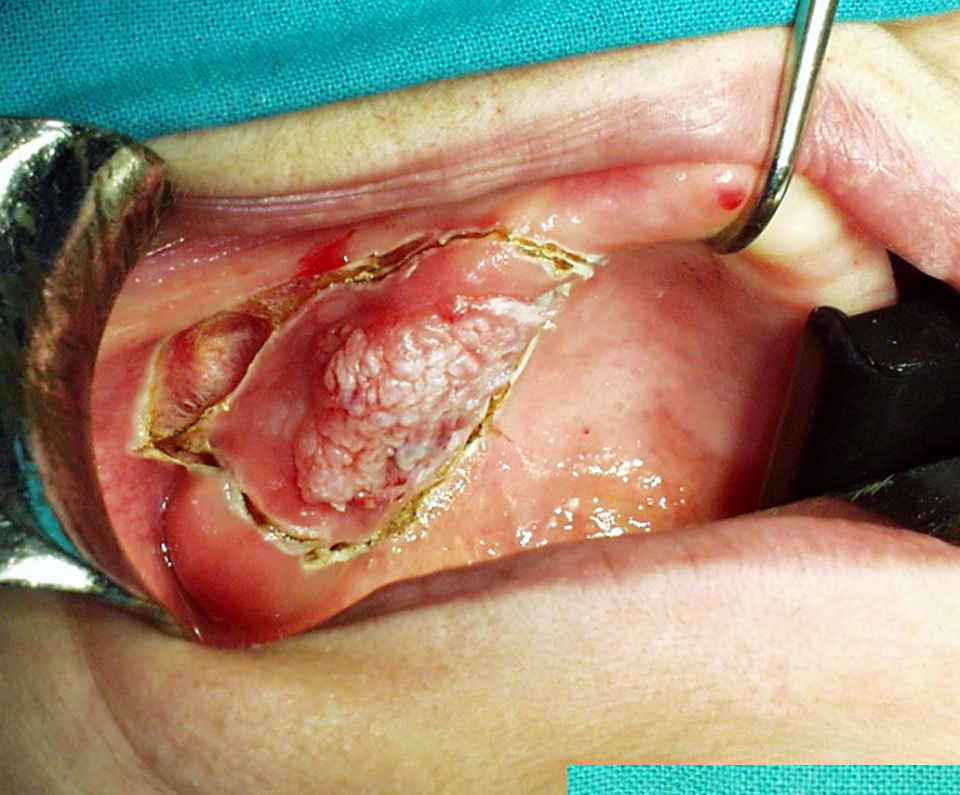
4 mjeseca  
stom.- antibiotik  
*verruca cornae papillomatosa*  
*leukoplakia verrucosa*



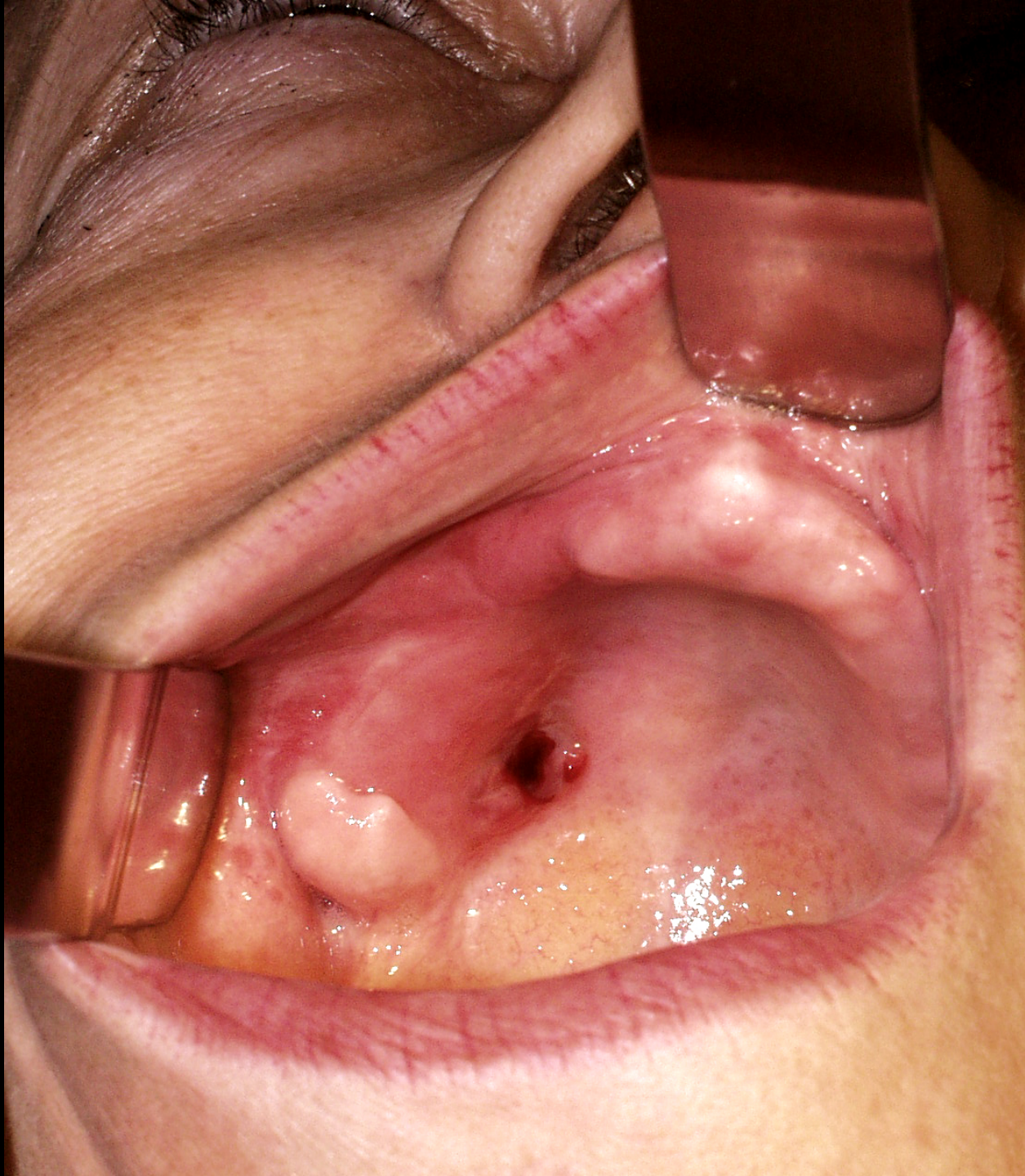




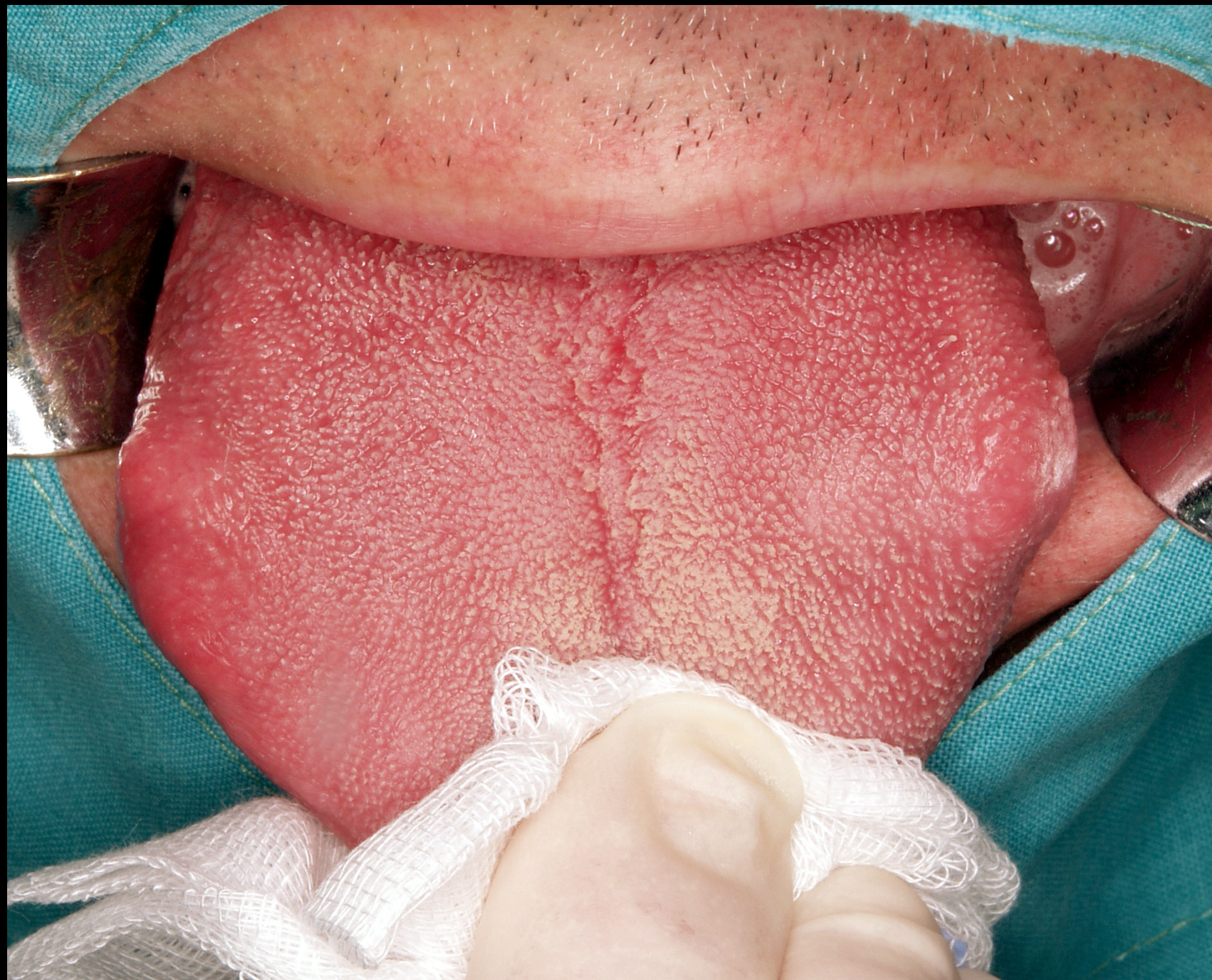



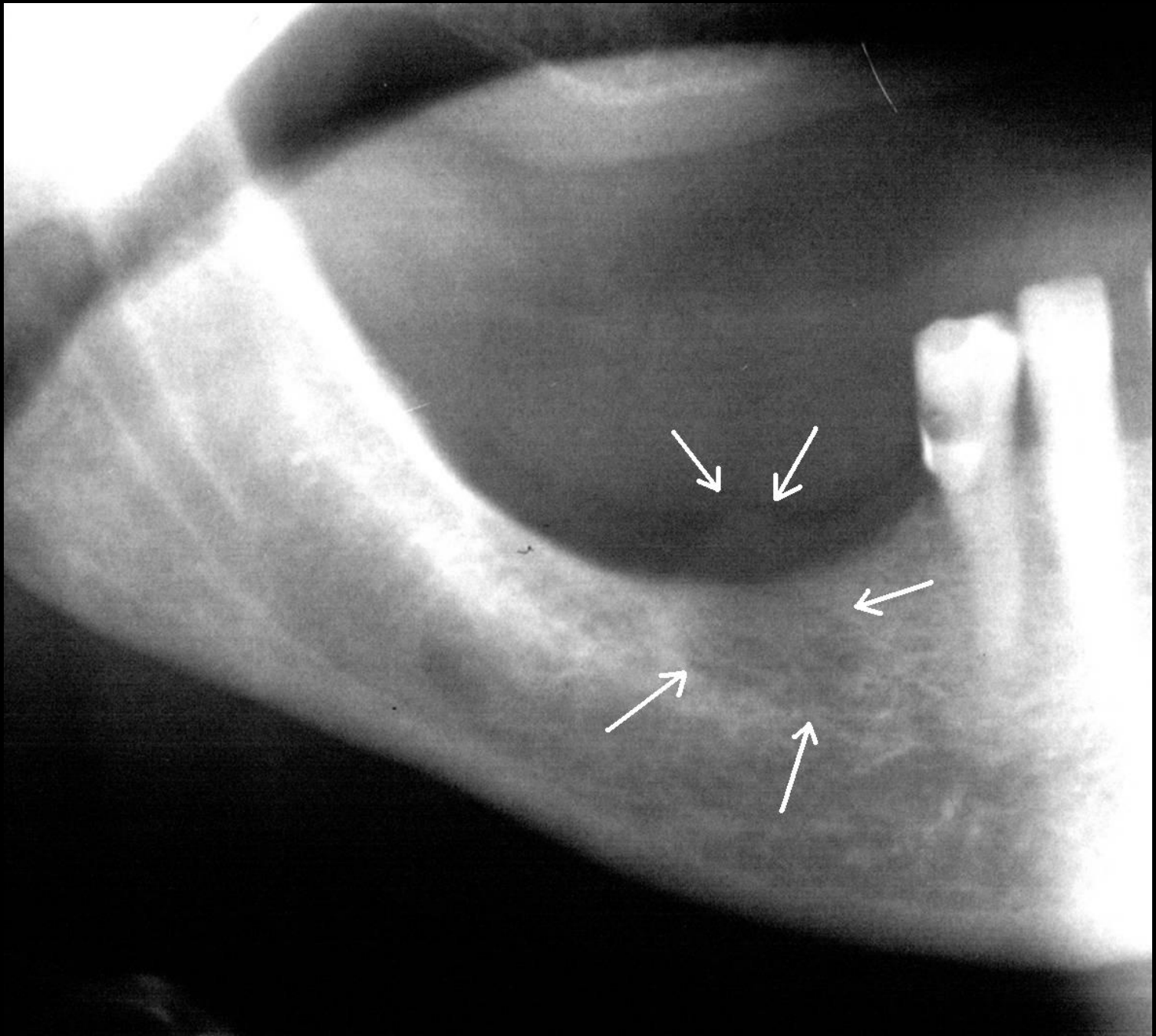




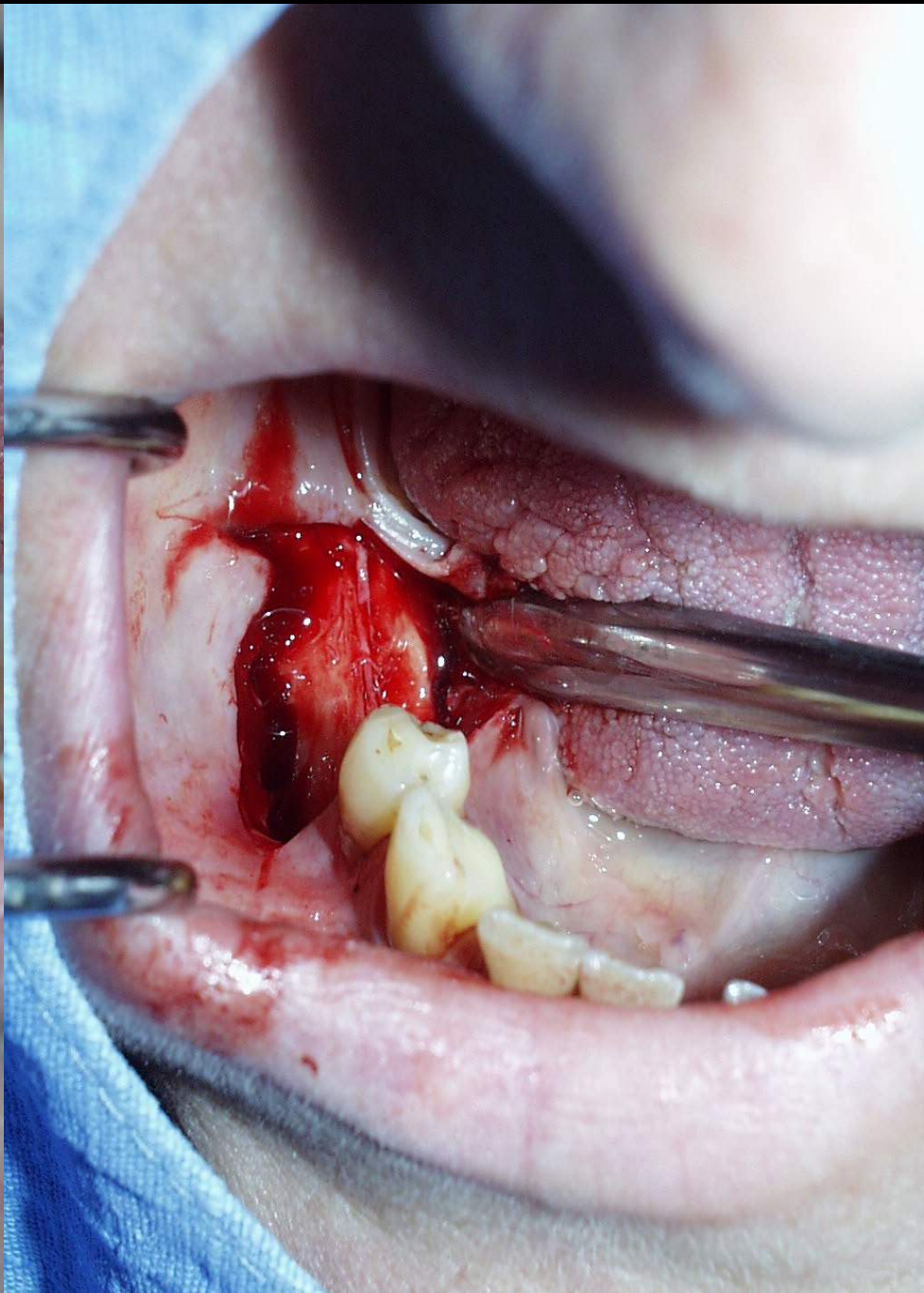
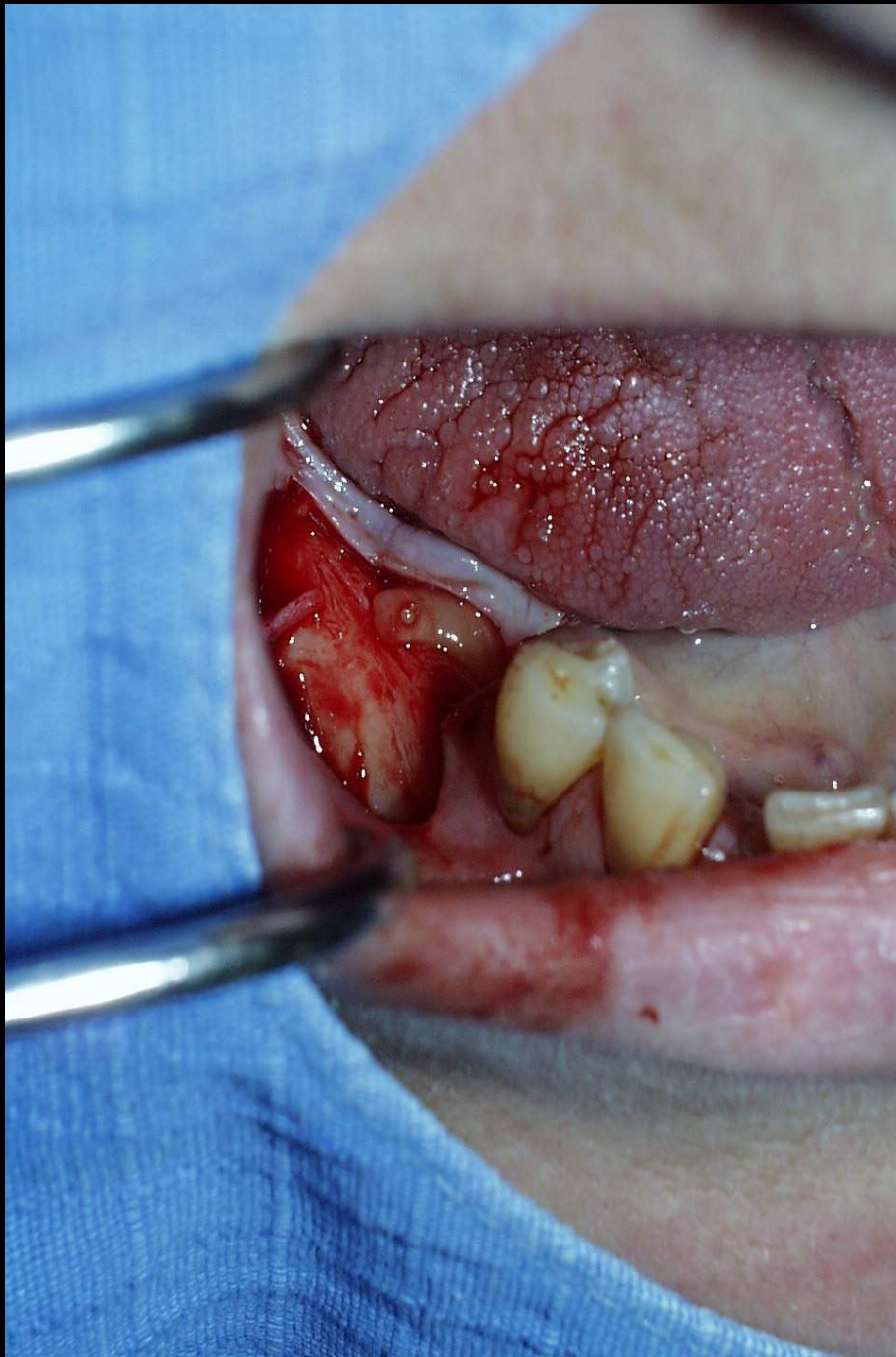





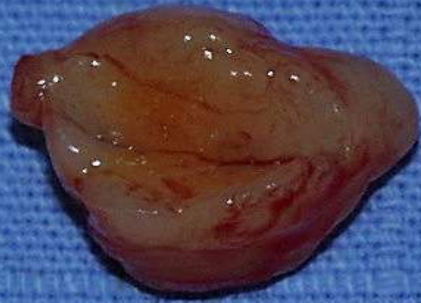




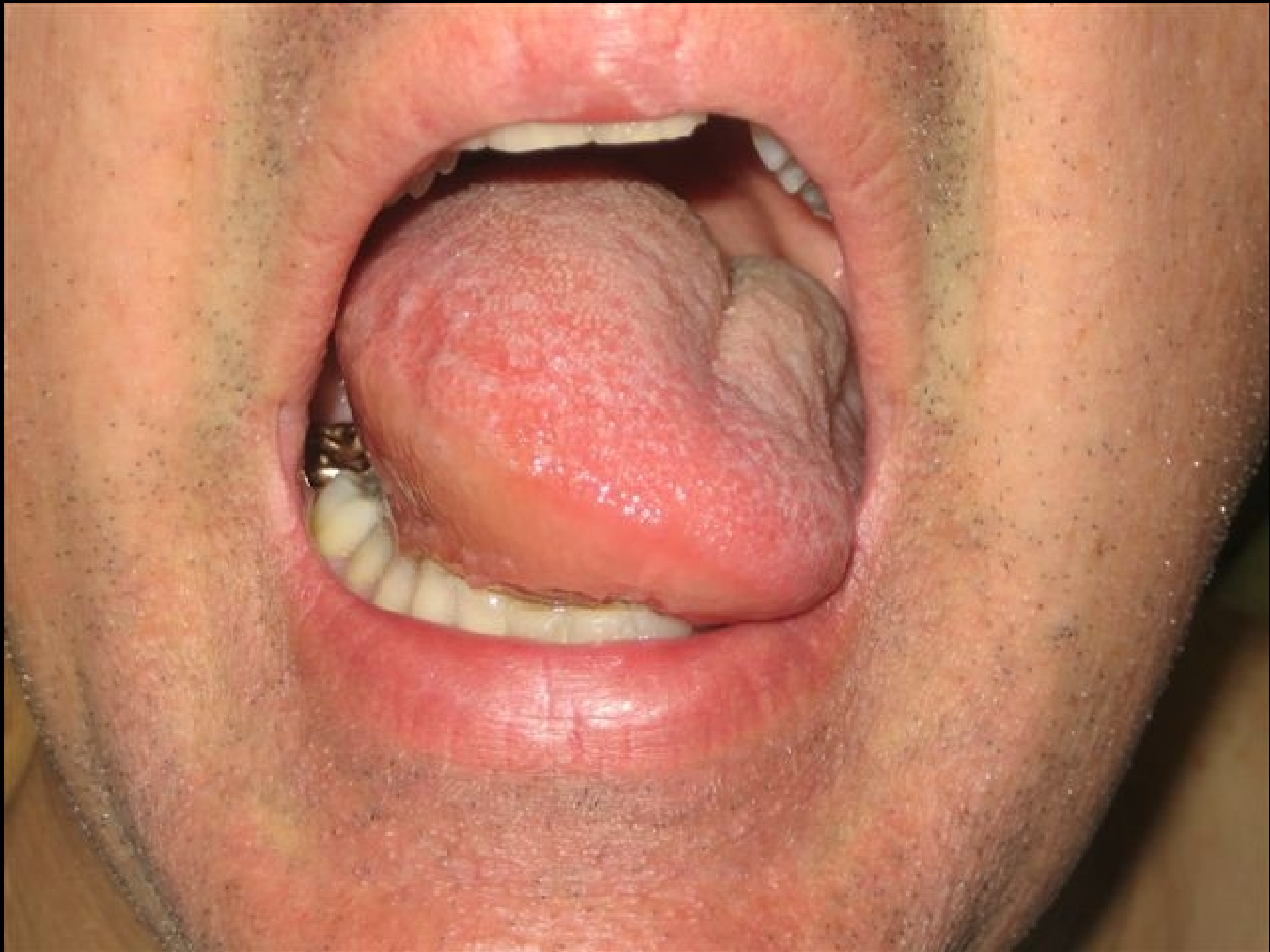


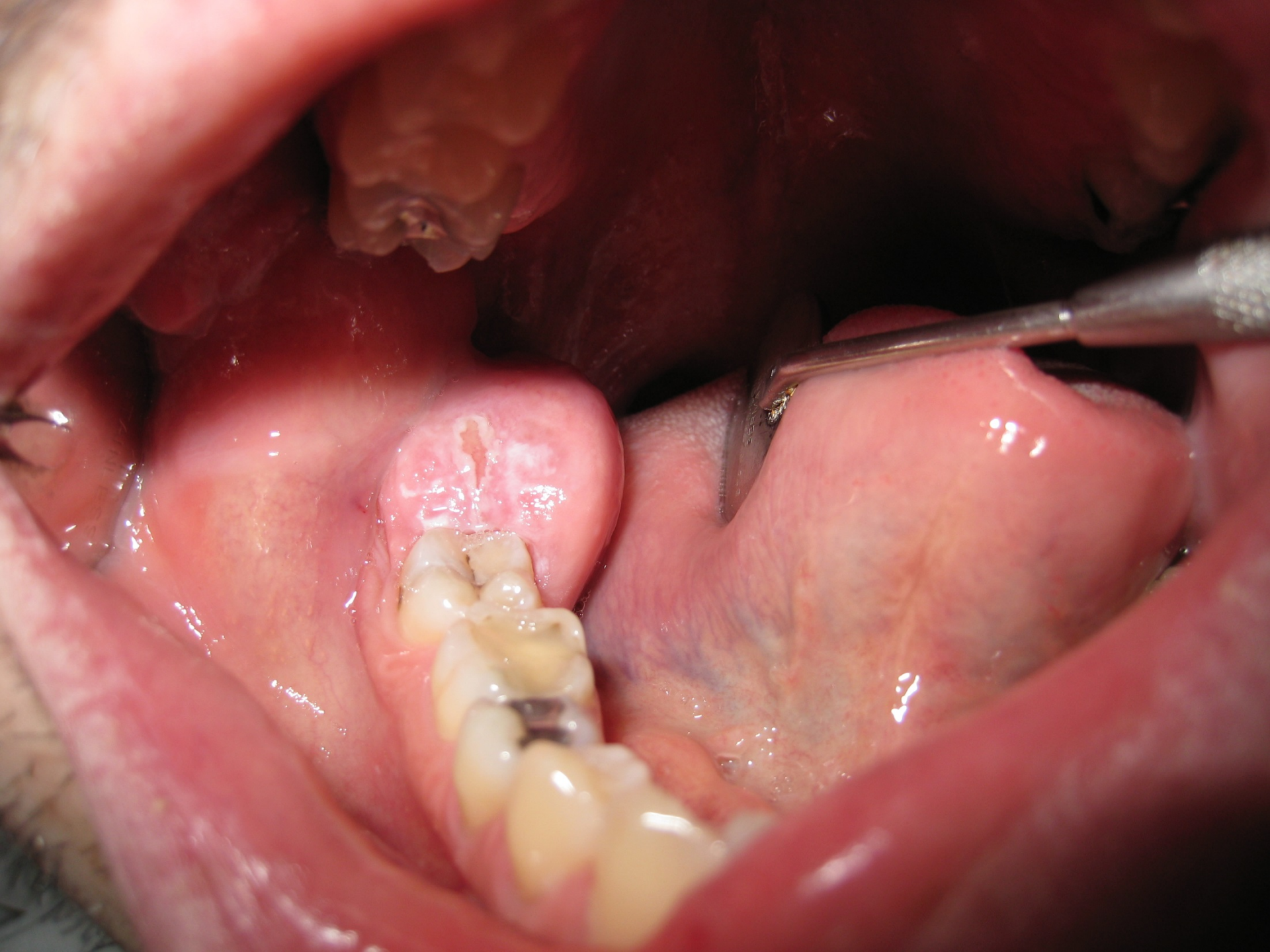
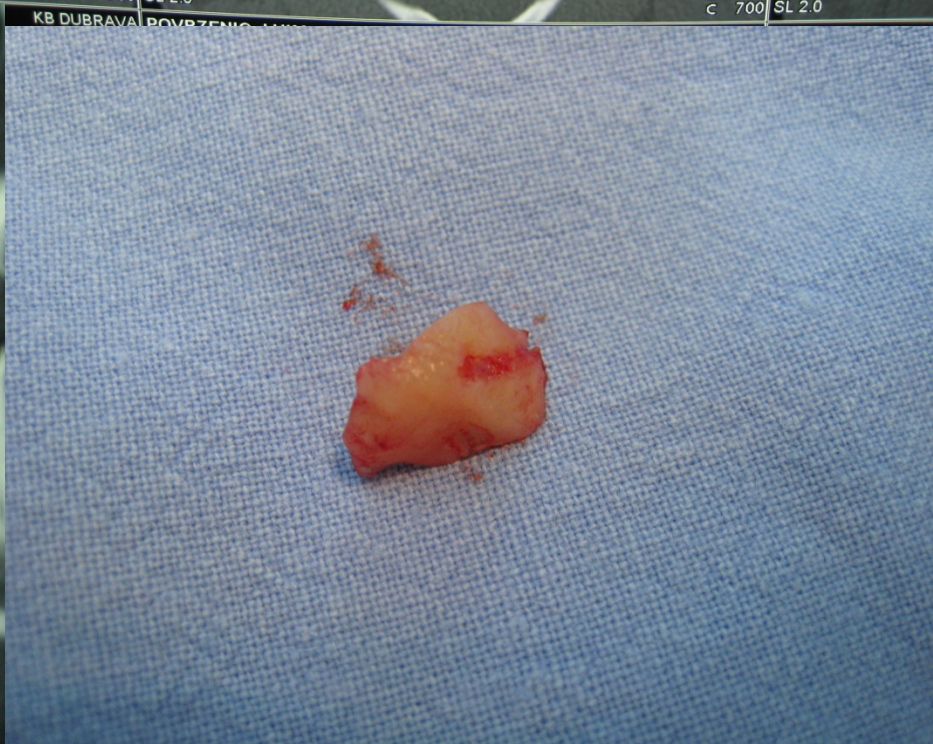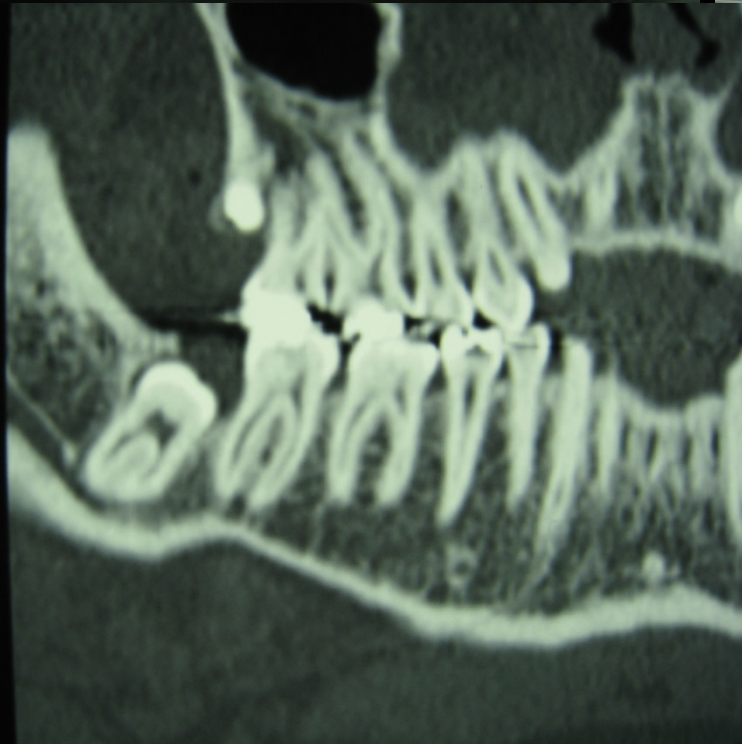
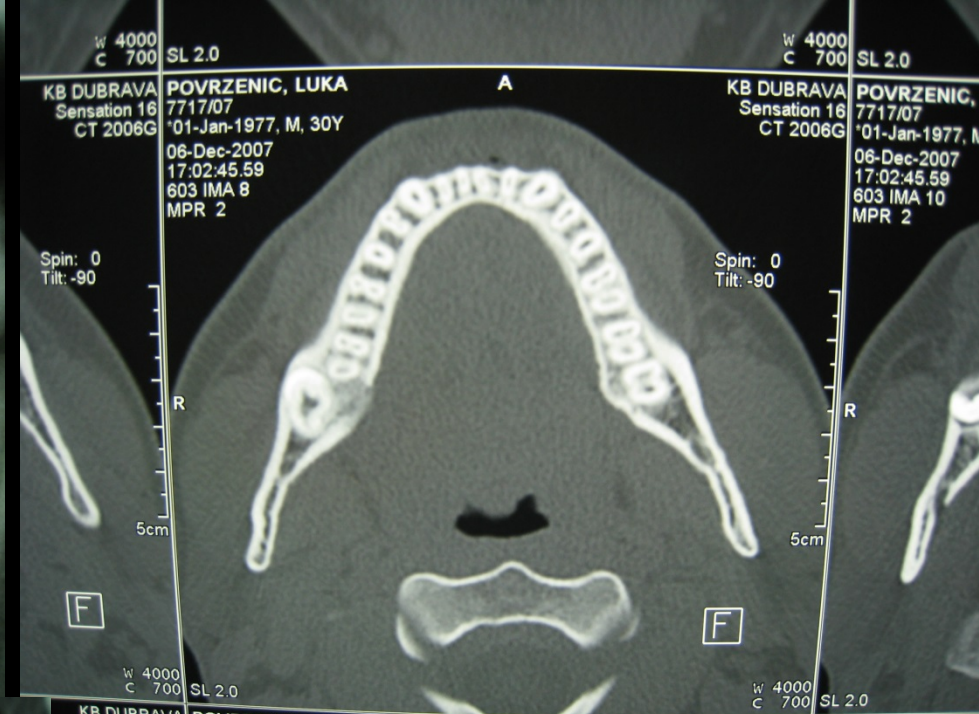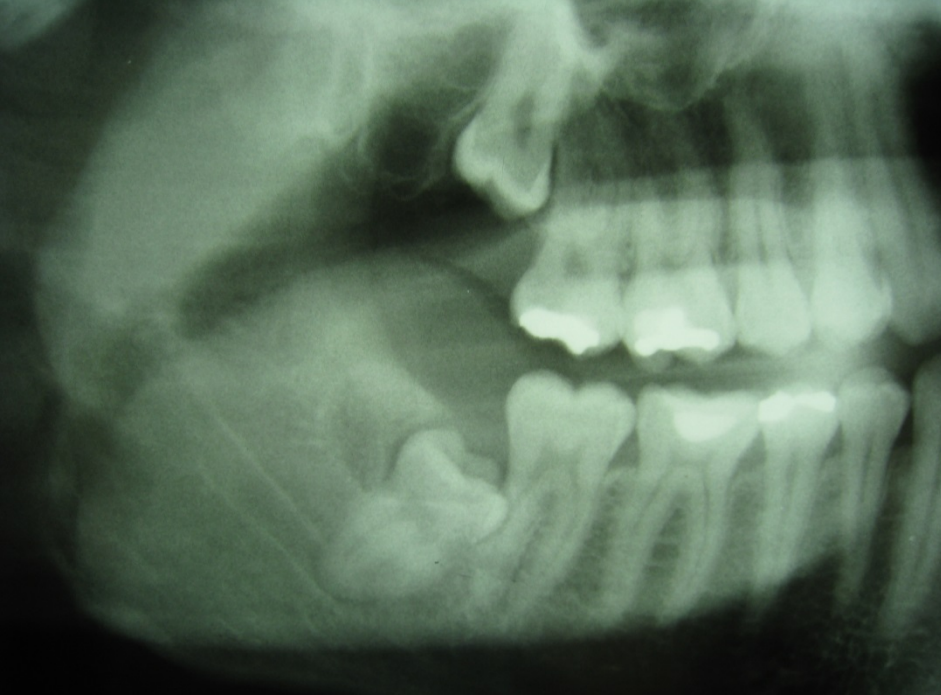








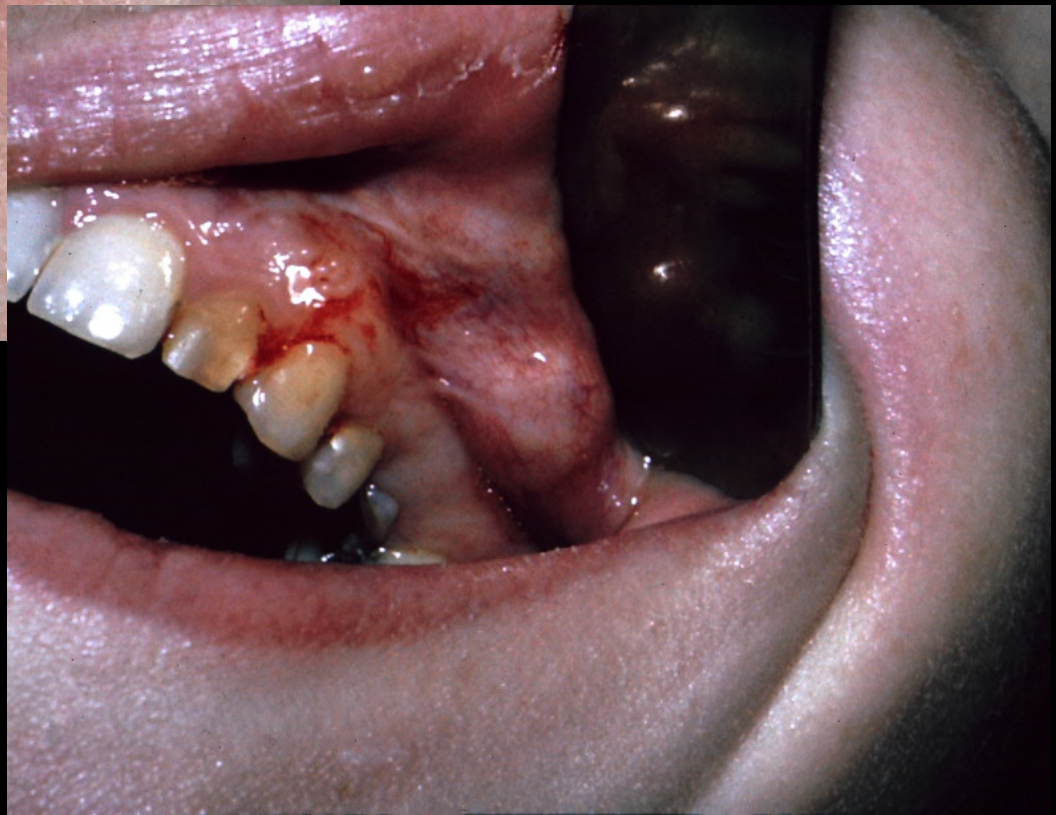
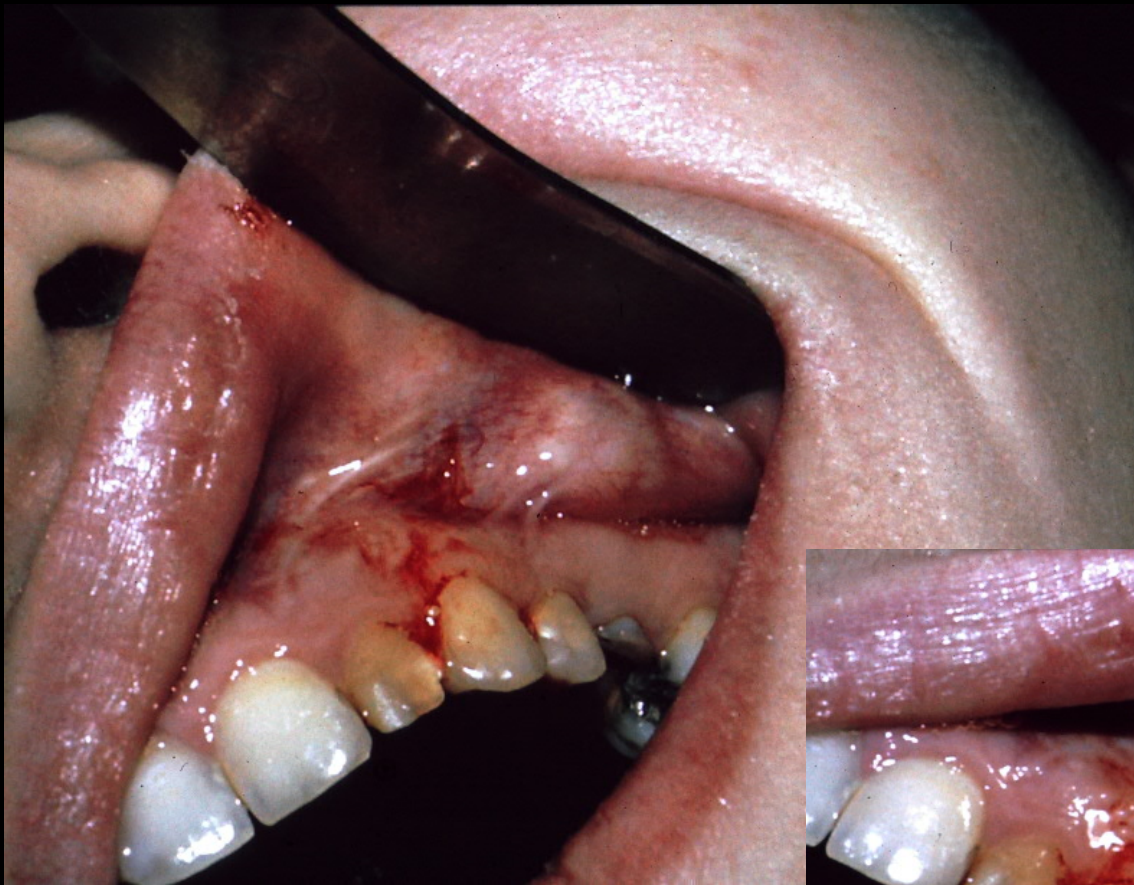


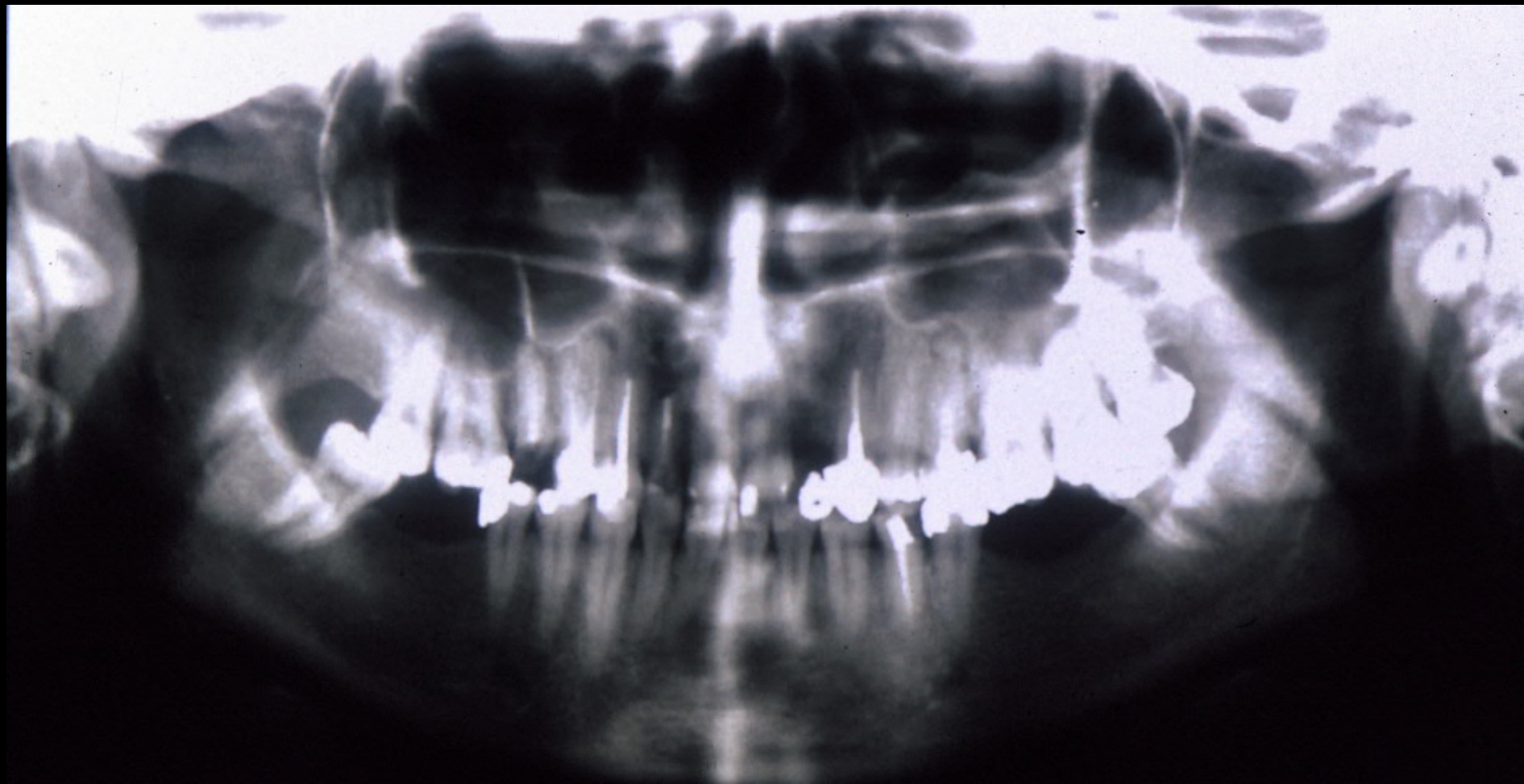








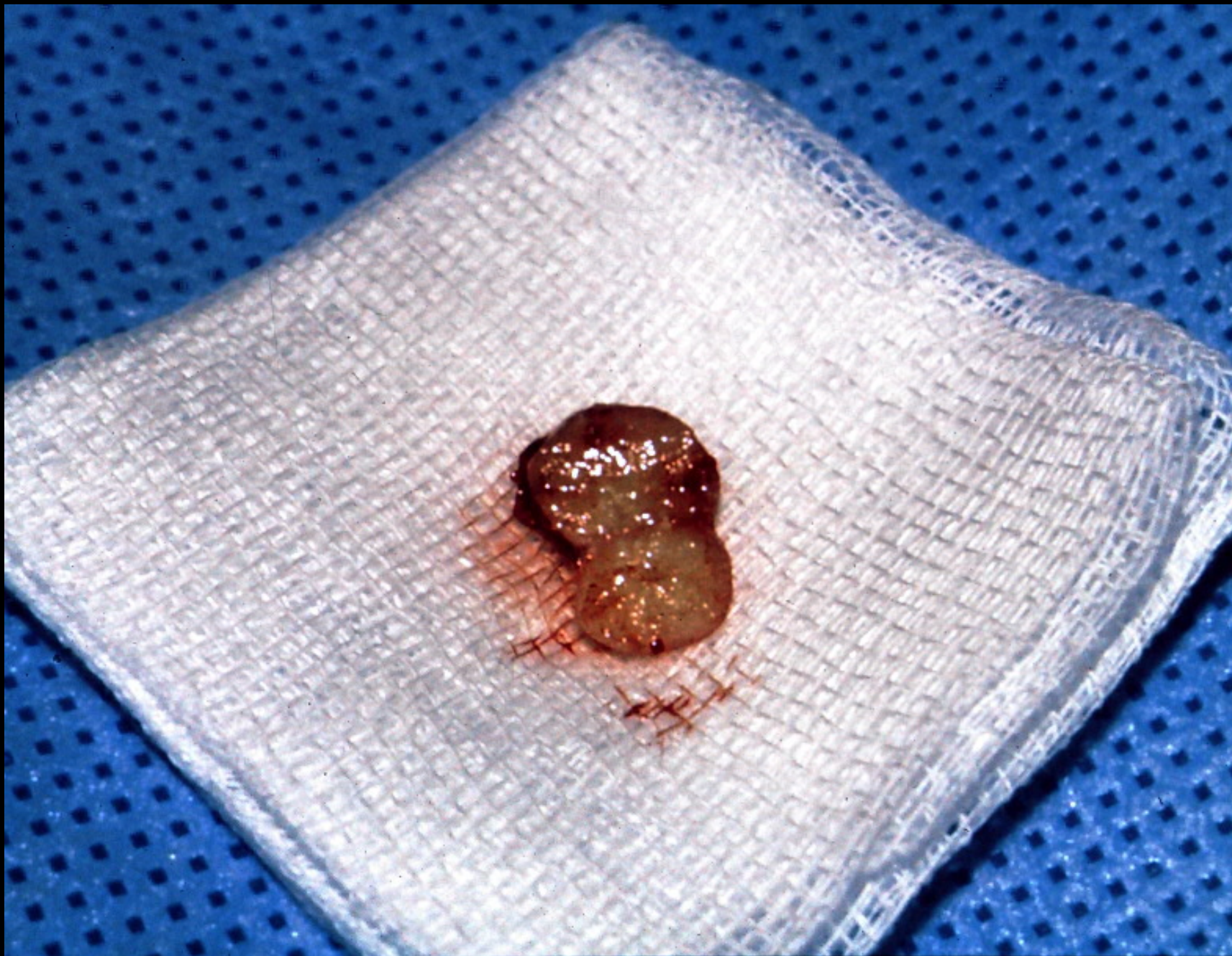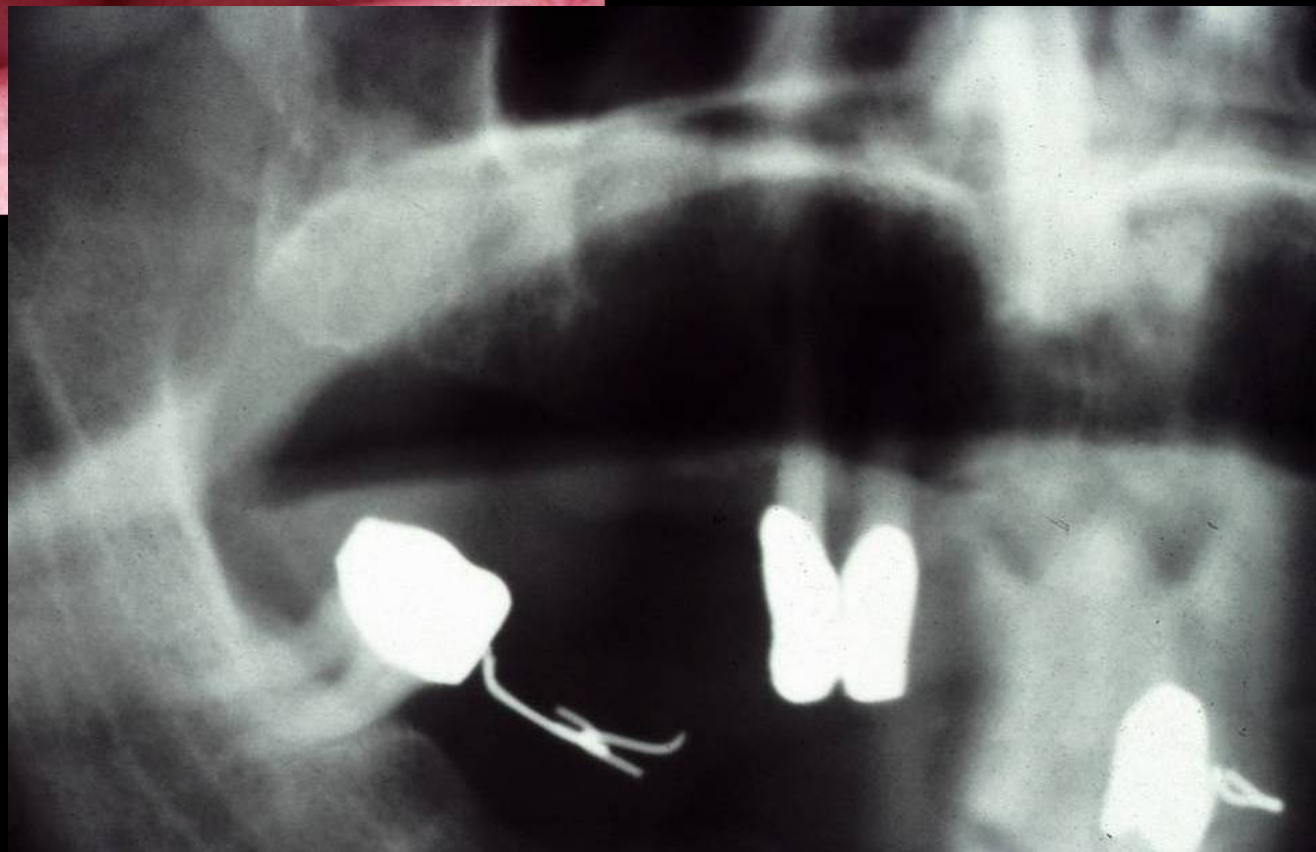
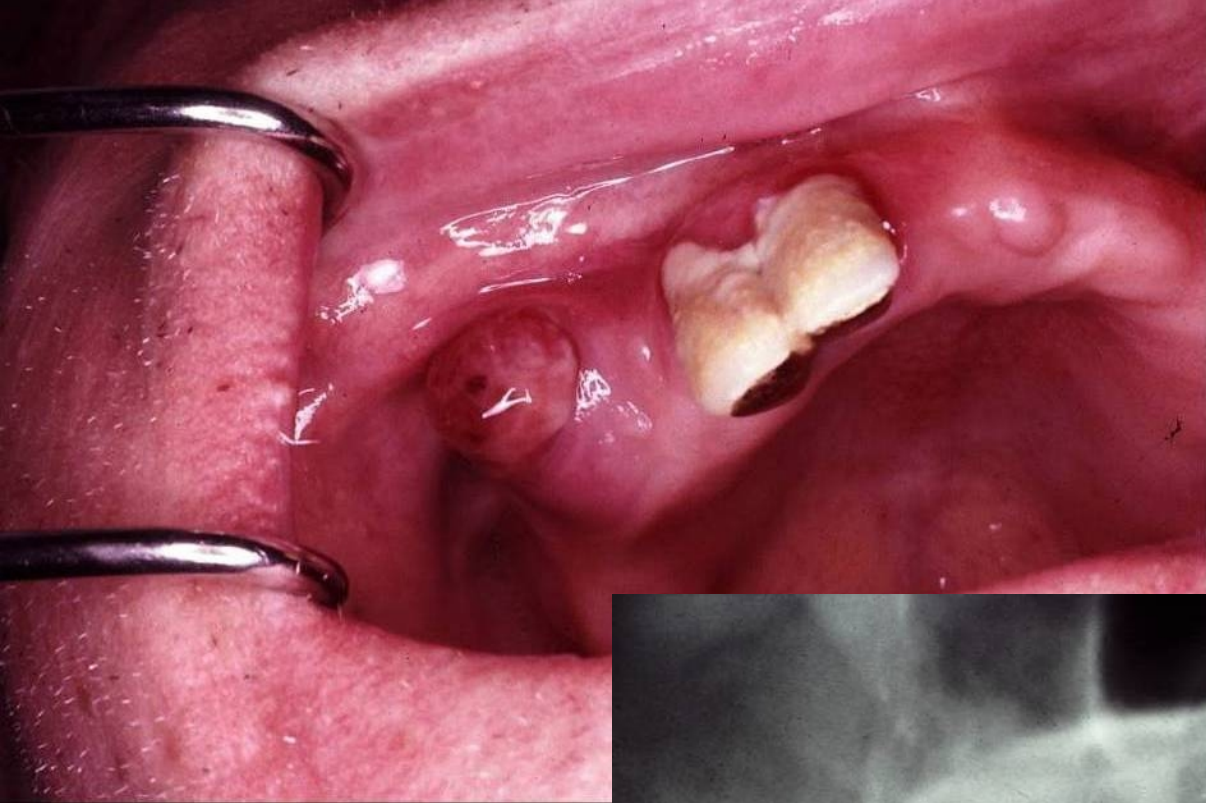










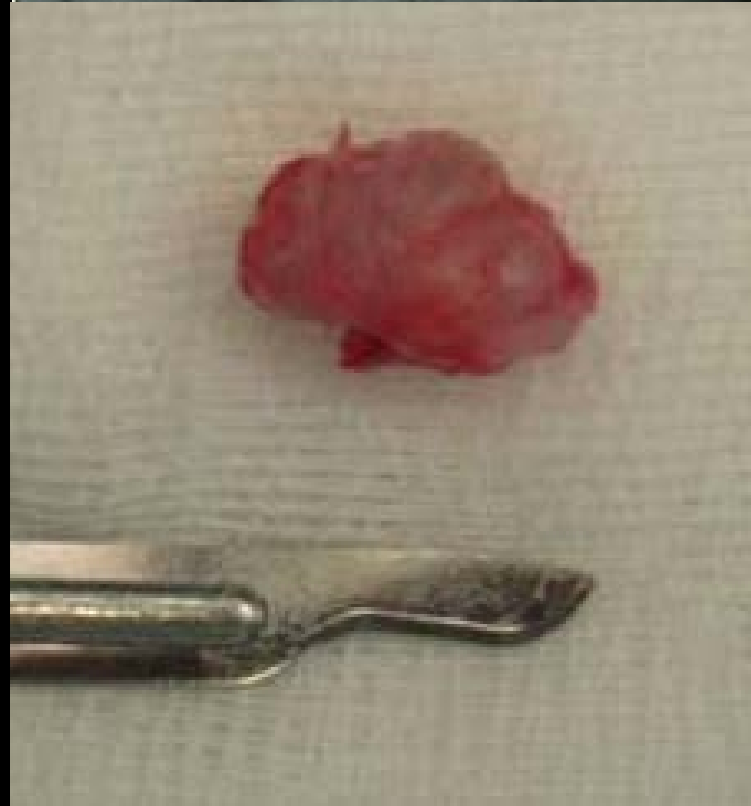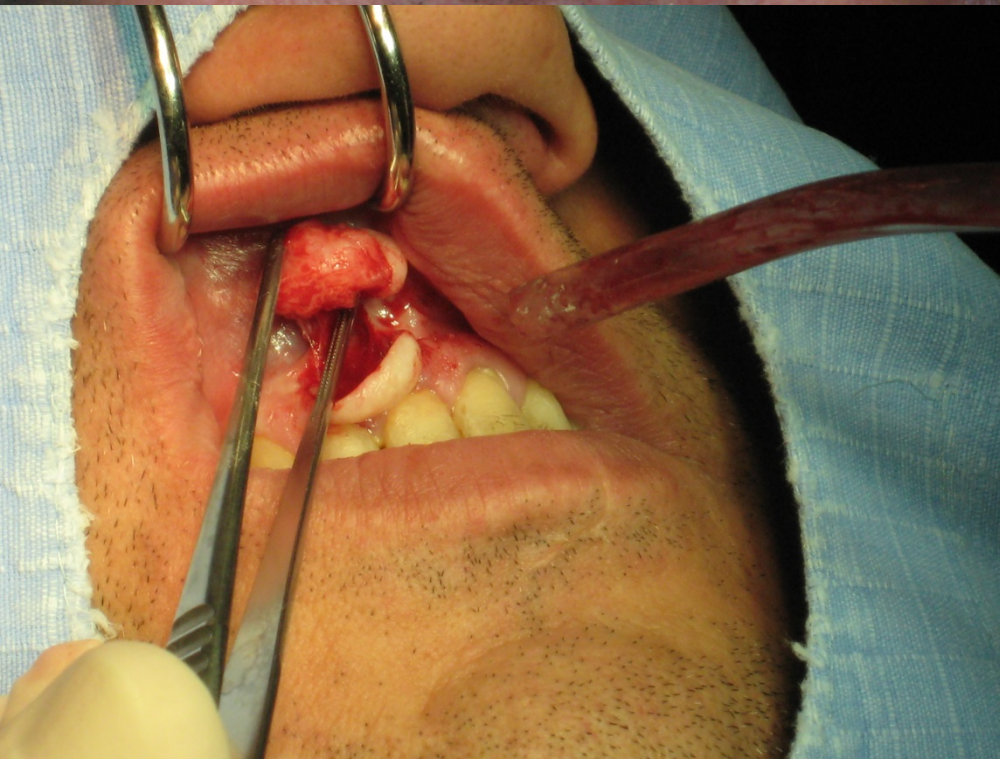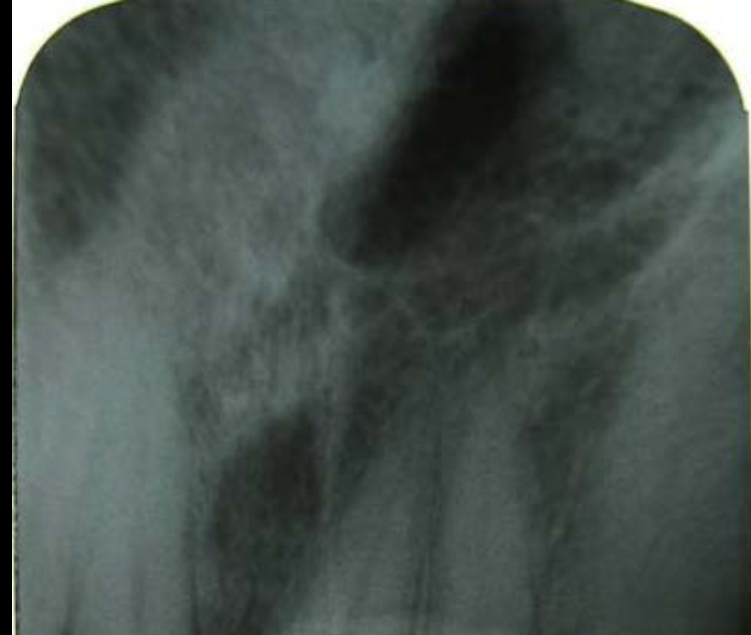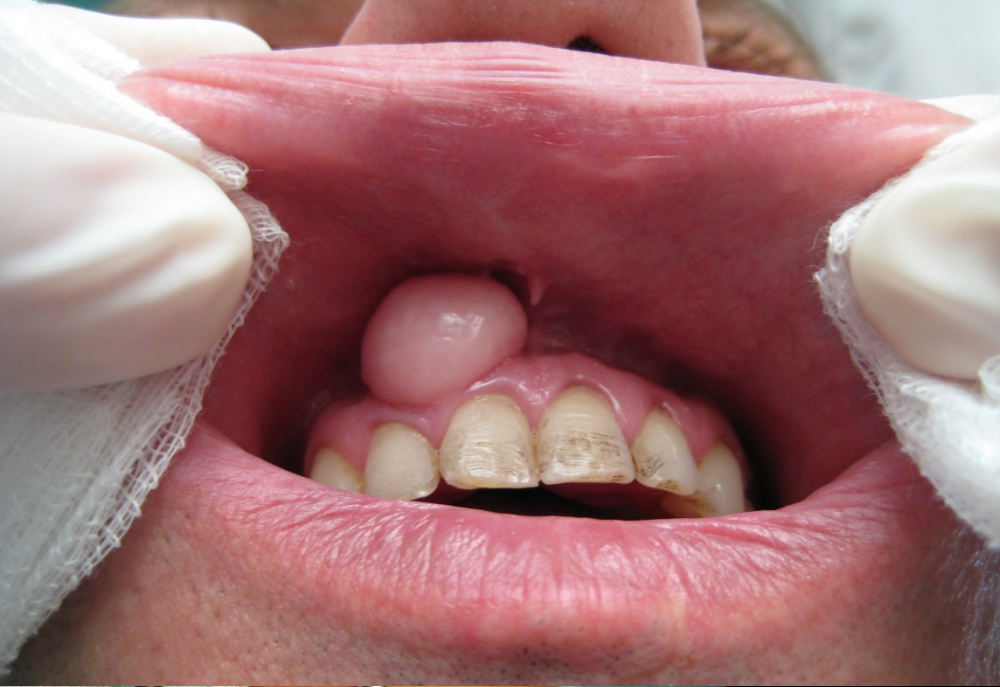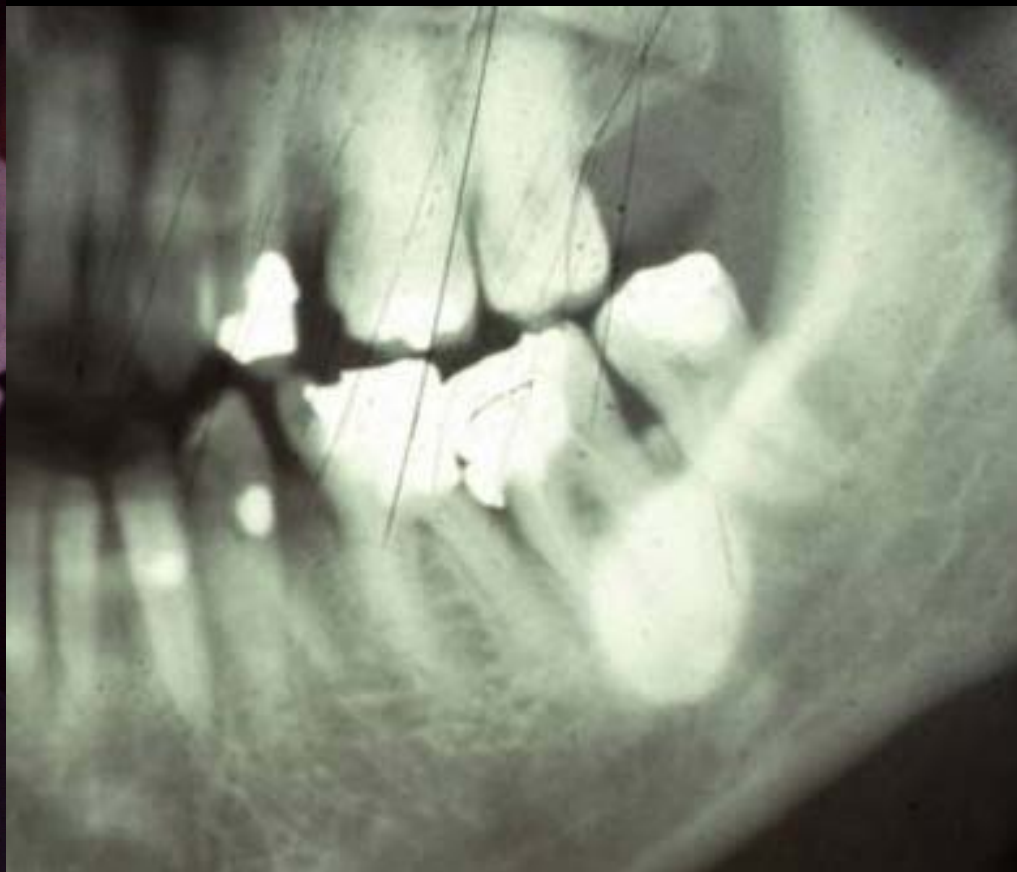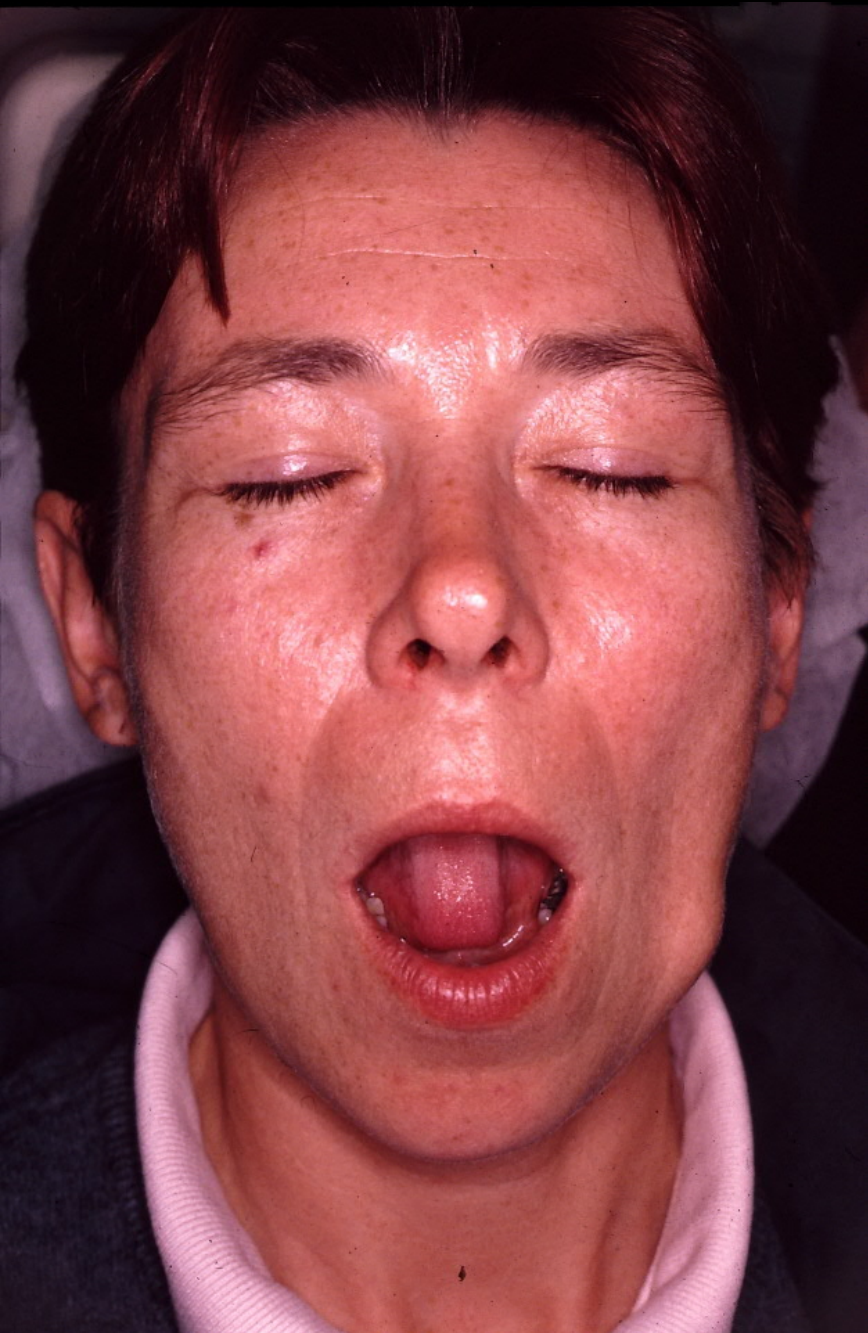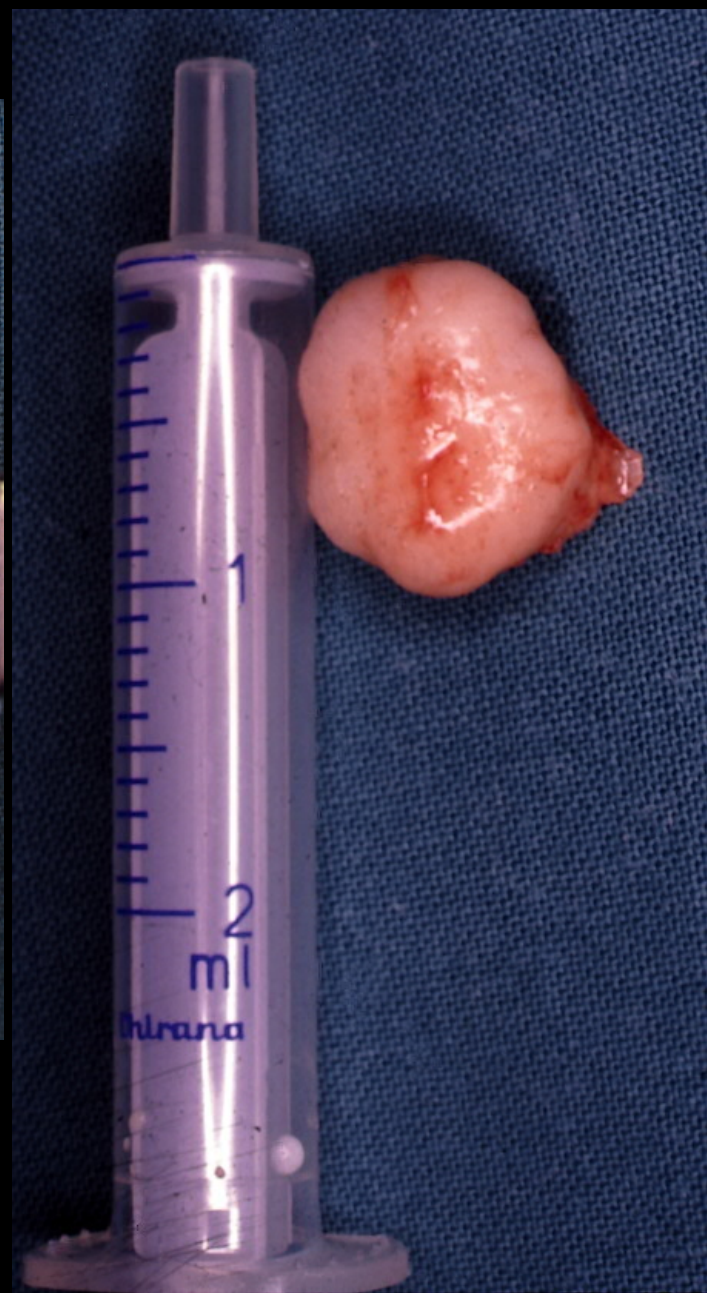
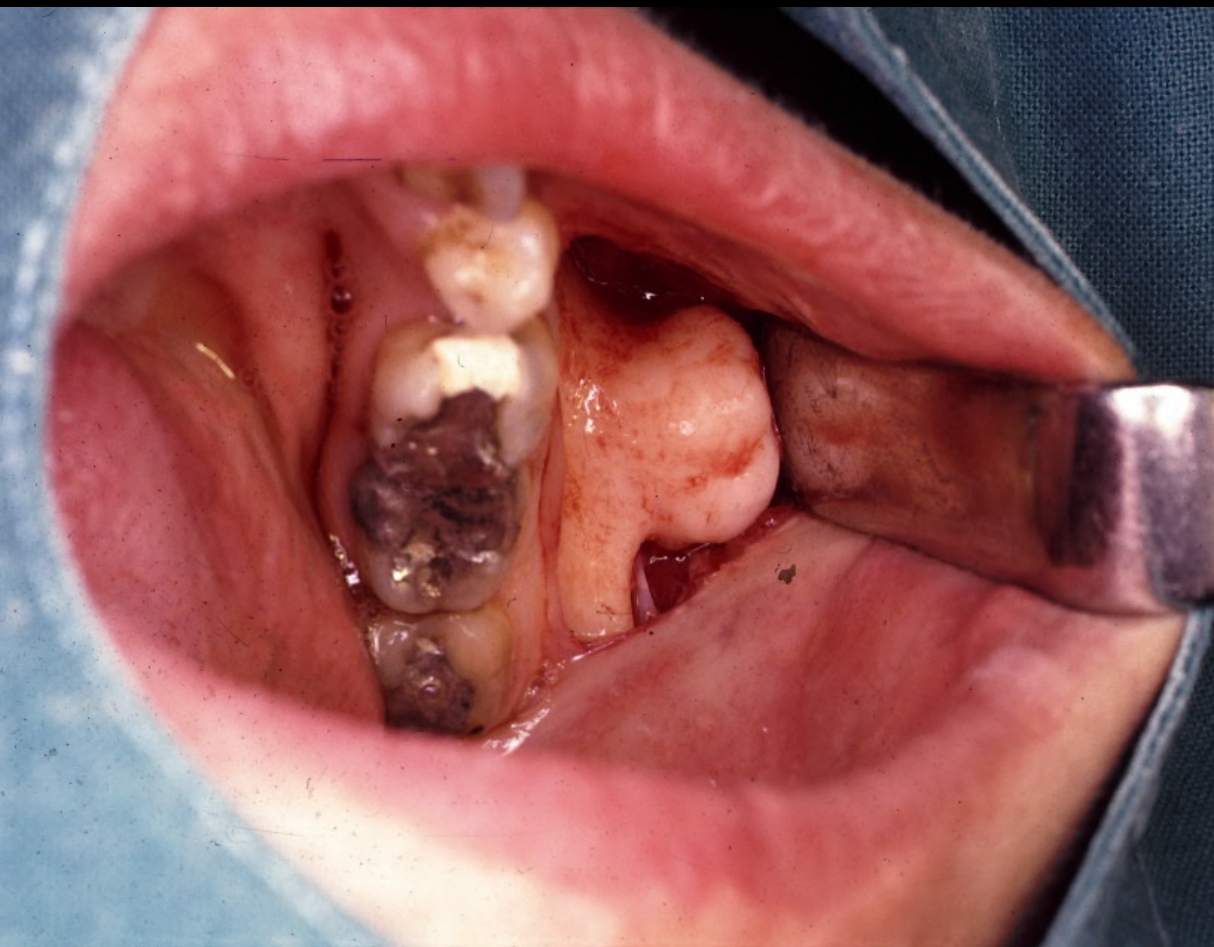




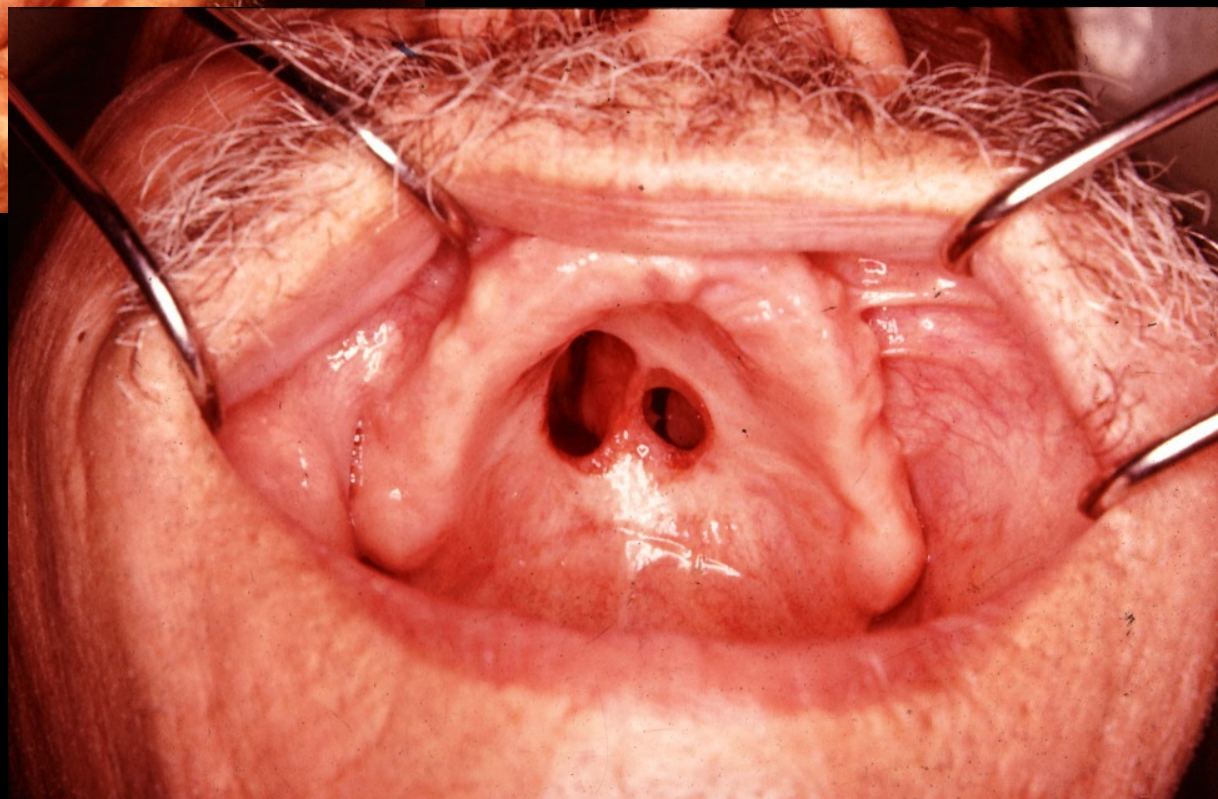
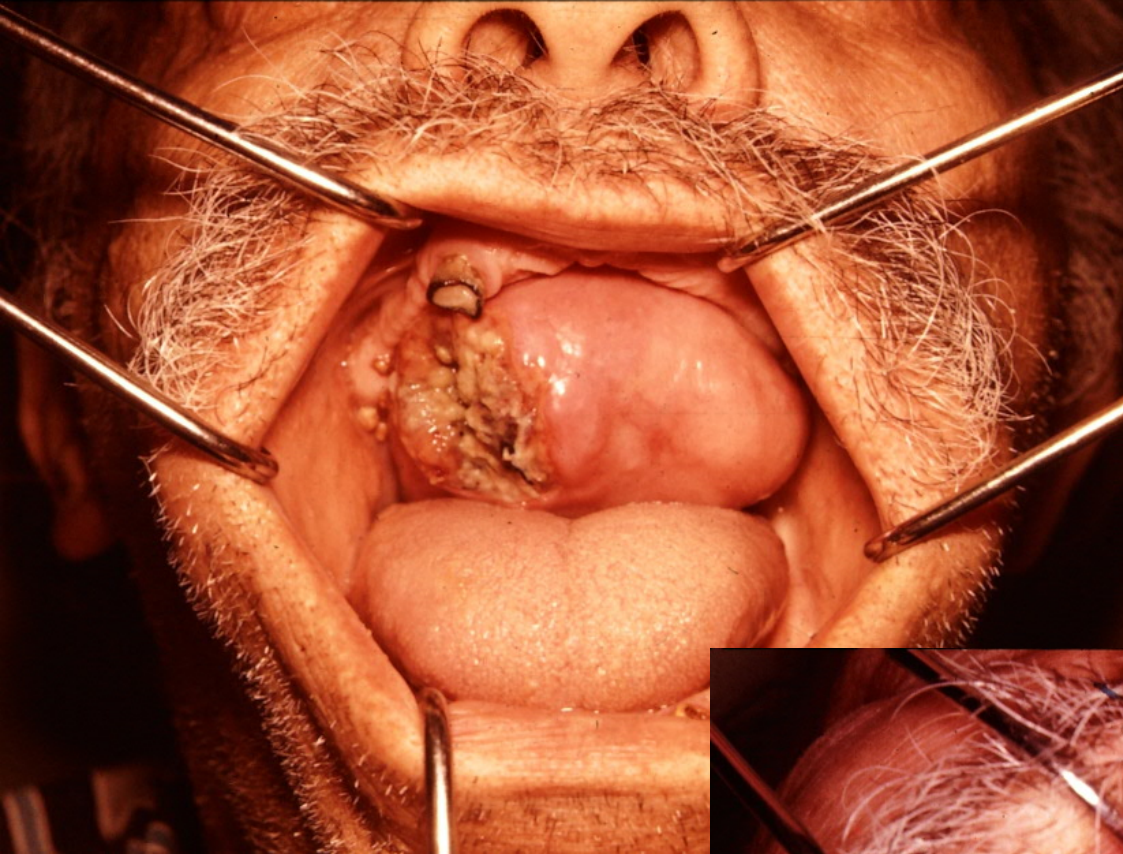
















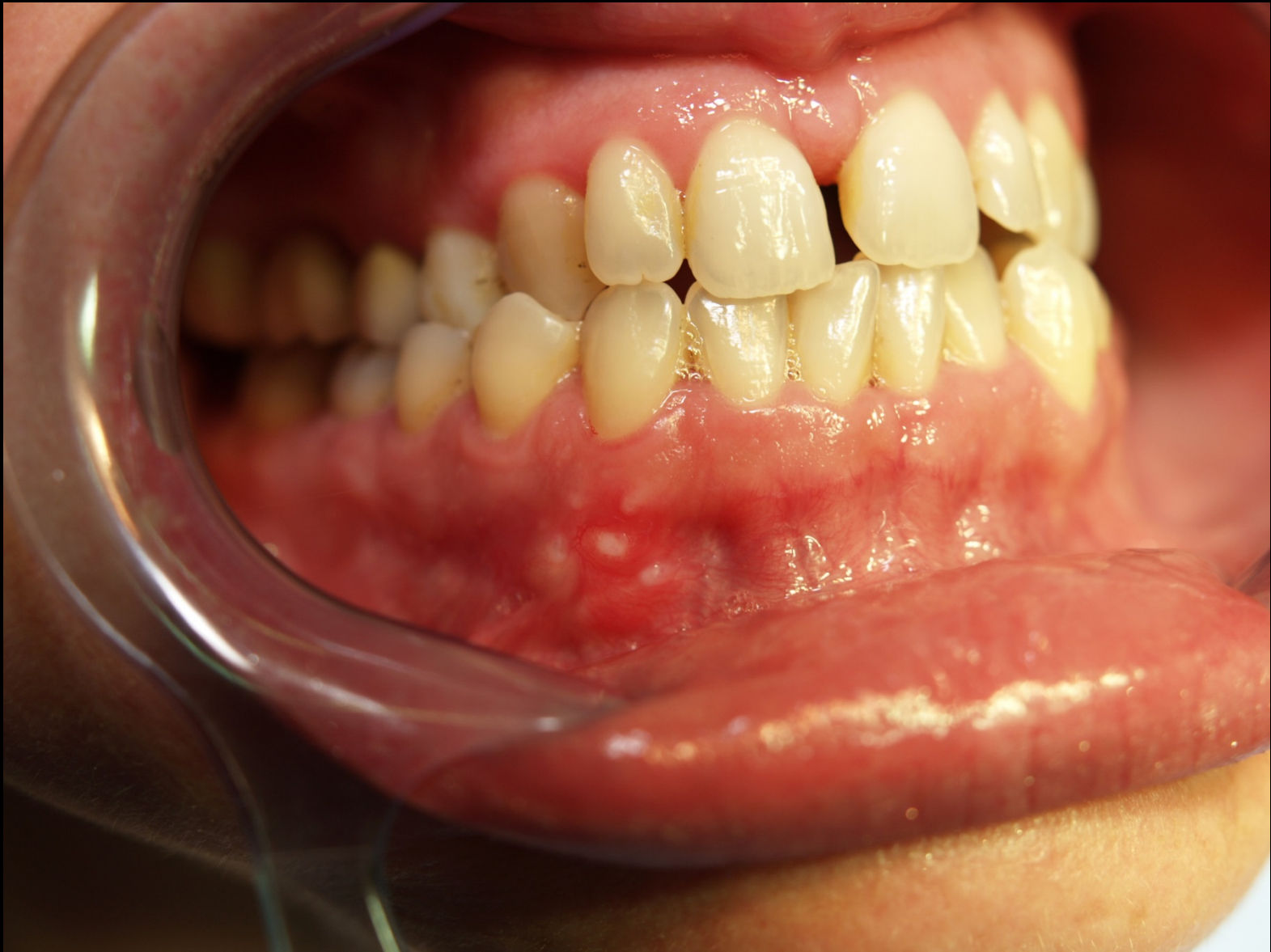MF 1.07

K.B. DUBRAVA  
VB10B

DONATOV\_VOLF, OLGA  
2547/06  
\*1/1/1962, F, 44Y

H

K.B. DUBRAVA  
VB10B

5/18/2006  
18:18:33.78  
505 IMA 4  
VRT 2

Spin: -90  
Tilt: 0

Spin: 90  
Tilt: 0

P



MF 1.07

K.B. DUBRAVA  
VB10B



Vrsta pregleda: MSCT MANDIBULE

Ing. med. radiologije:

Administrator: Maja N.

---

## **N A L A Z :**

Datum: 19.05.2006.

MSCT mandibule s multiplanarnim prikazom u HR protokolu i standardnom modu. Na seriji učinjenih presjeka kroz mandibulu vidi se stanjenje korpusa mandibule u prednjem dijelu s lijeve strane bez znakova patološke koštane pregradnje i osteodestruktivskih promjena.


Perimandibularno meko tkivo je bez bitnijih morfoloških promjena.

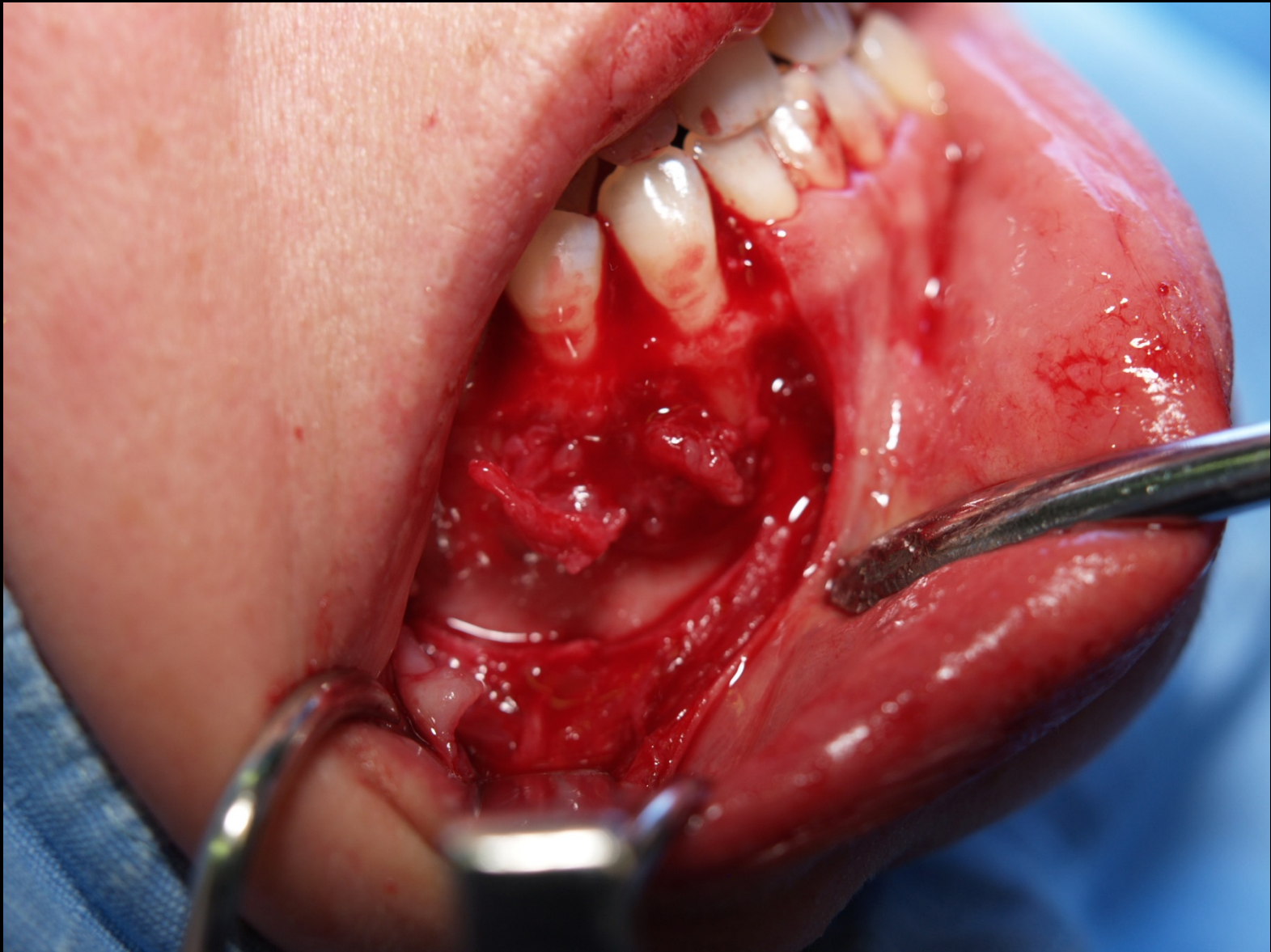Temporomandibularni zglobovi pokazuju neravninu artikulacionih ploha kondila obostrano, izraženiju na lijevoj strani, uz redukciju širine artikulacionih pukotina, što odgovara blažim artrotskim promjenama.

U regiji II obostrano vide se reaktivni limfonodi veličine 7 do 8mm. Submandibularne žlijezde su primjerene veličine i strukture.

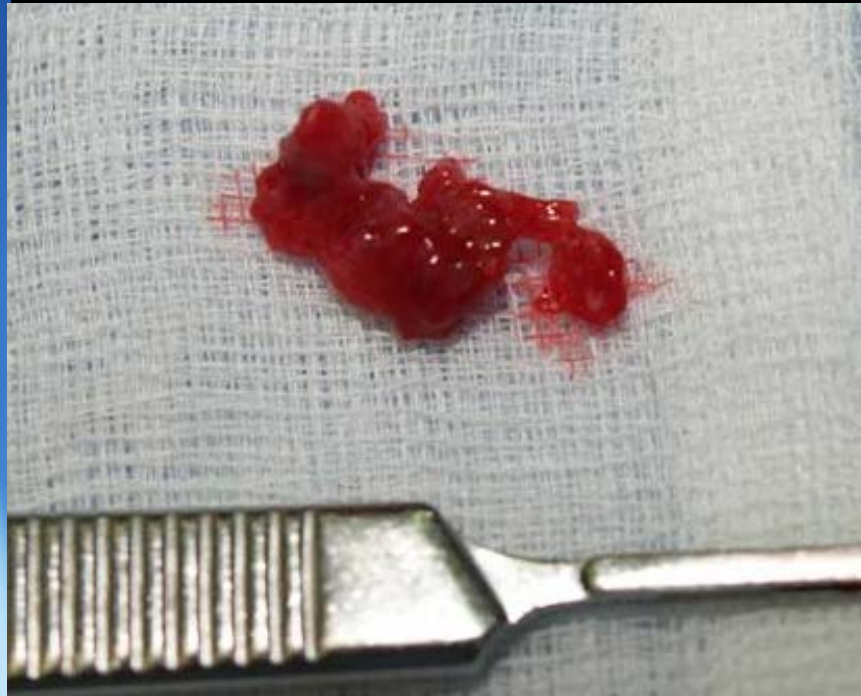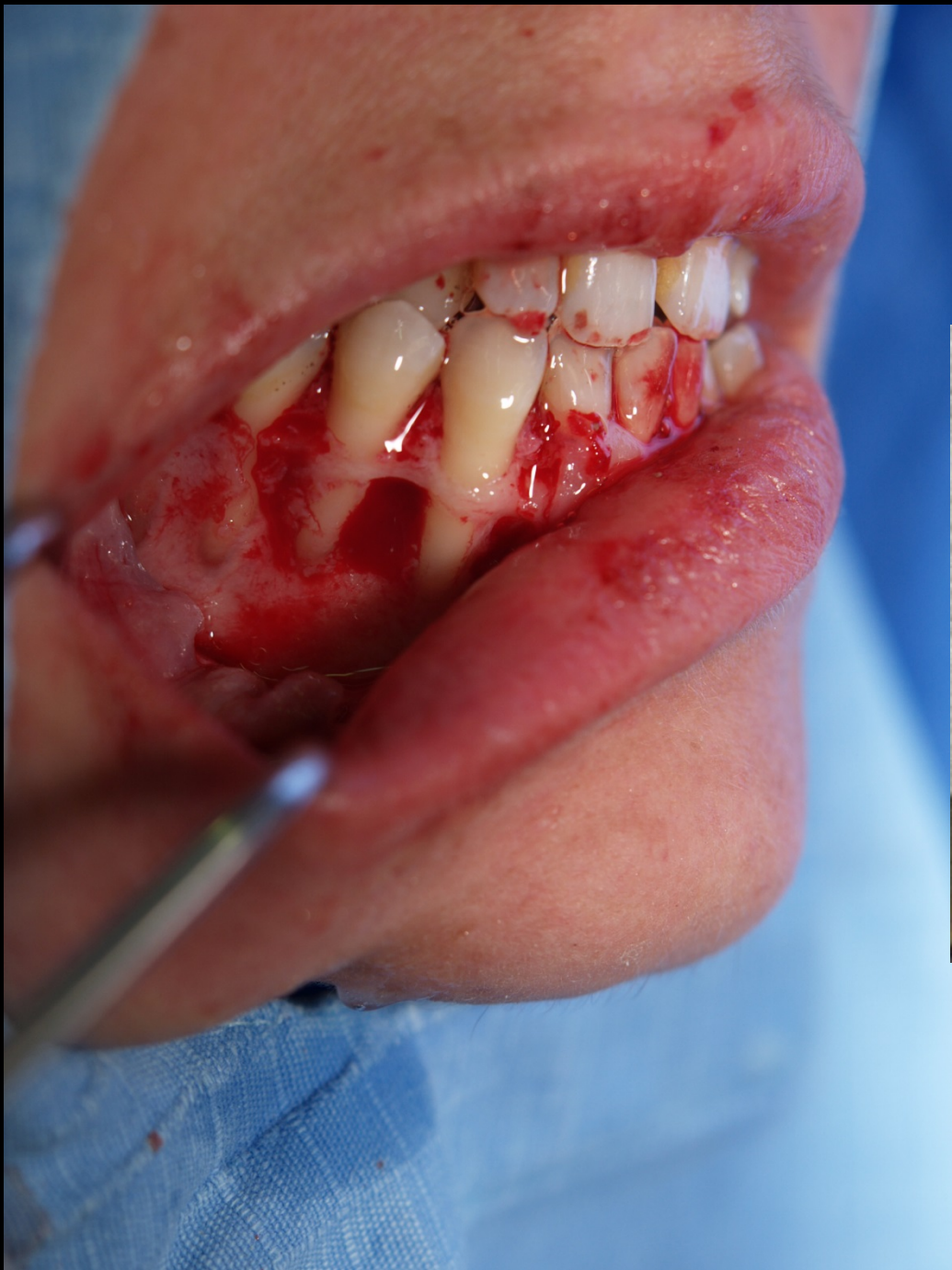Potpis liječnika: mr.sc.dr. Josip Hat 030279

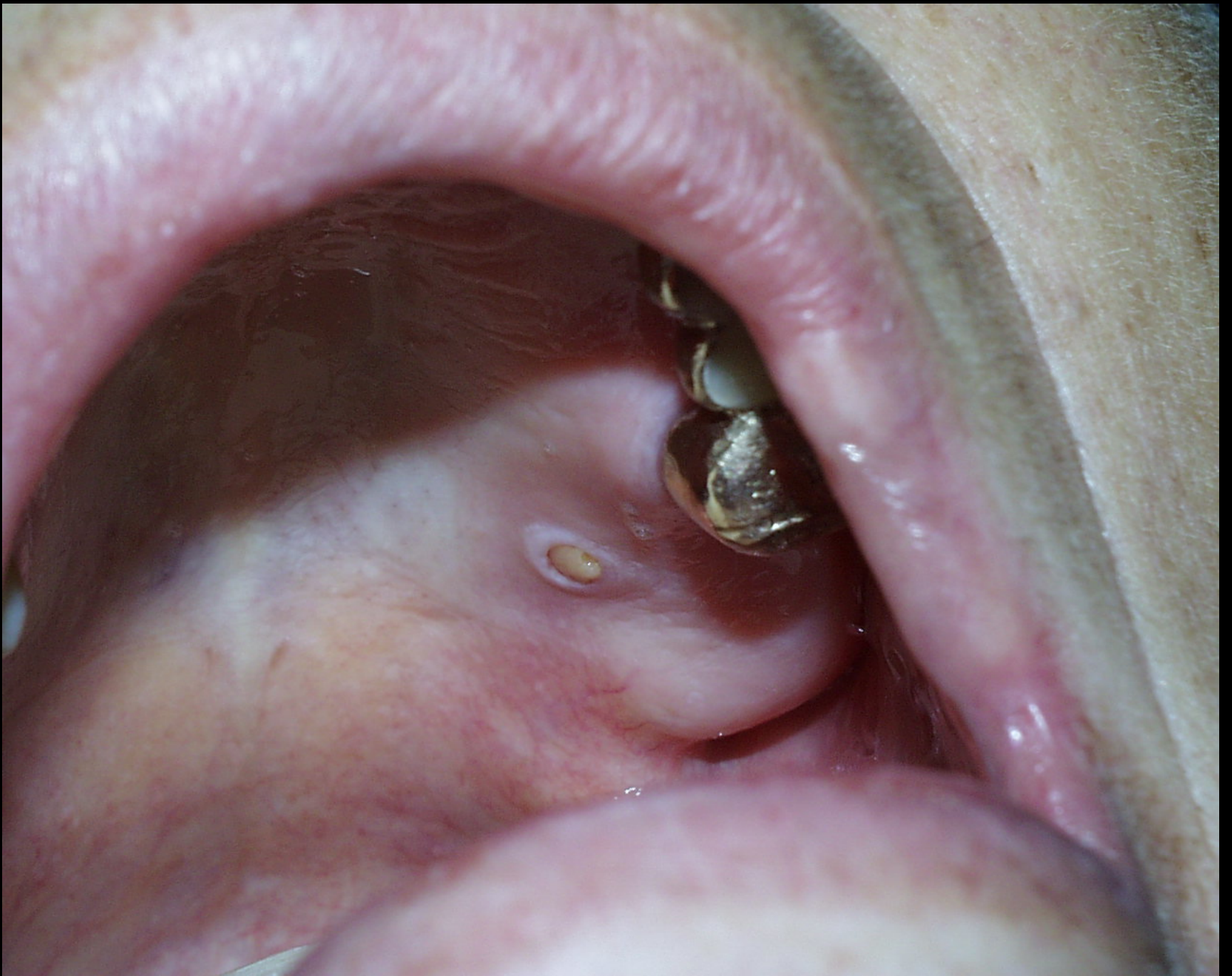---



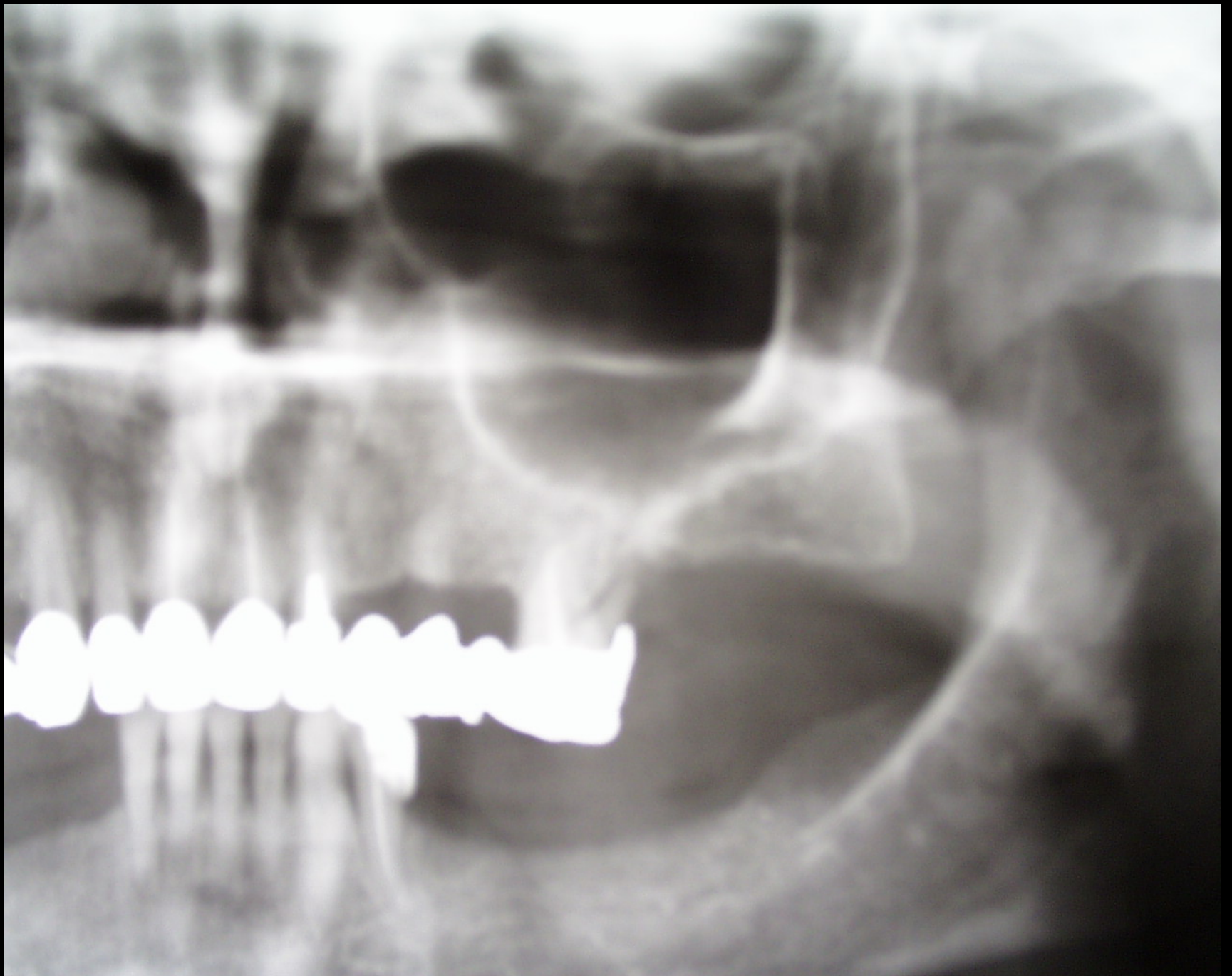


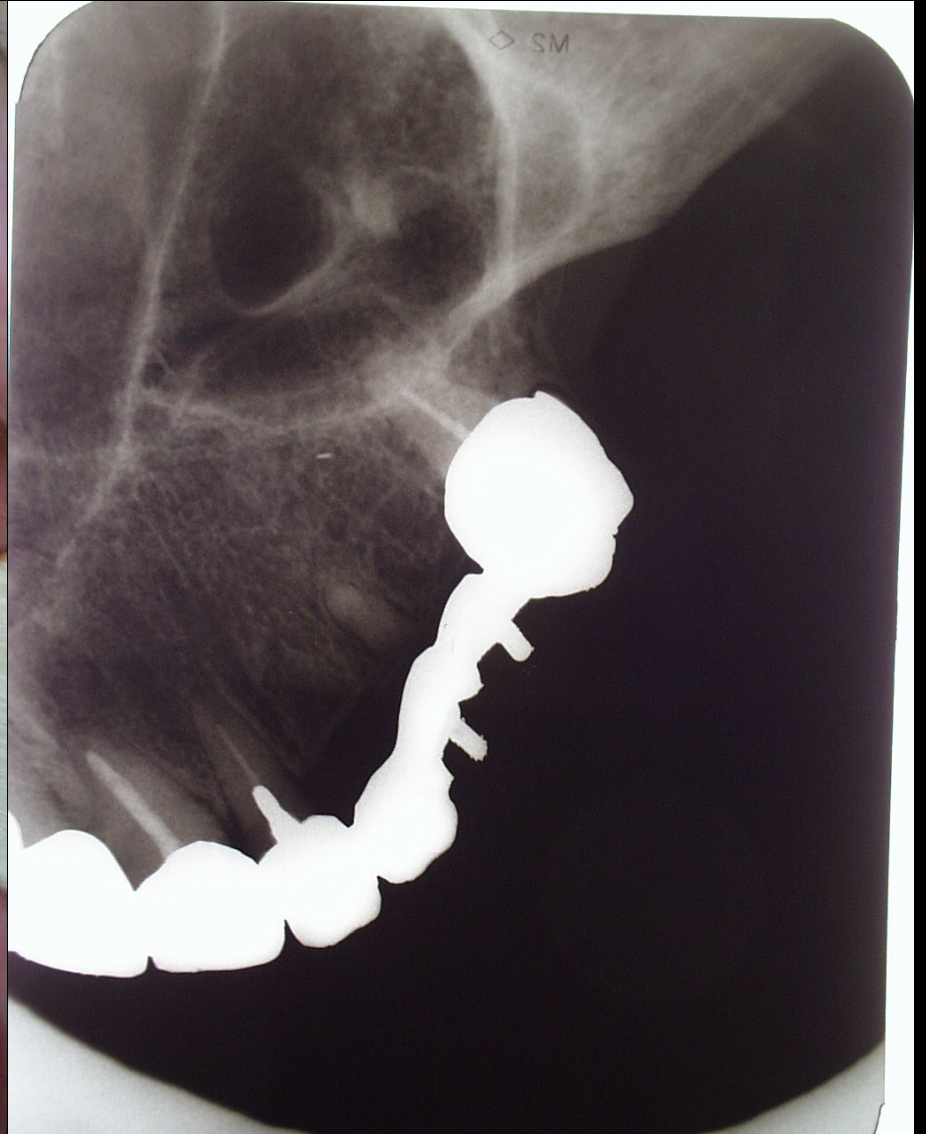
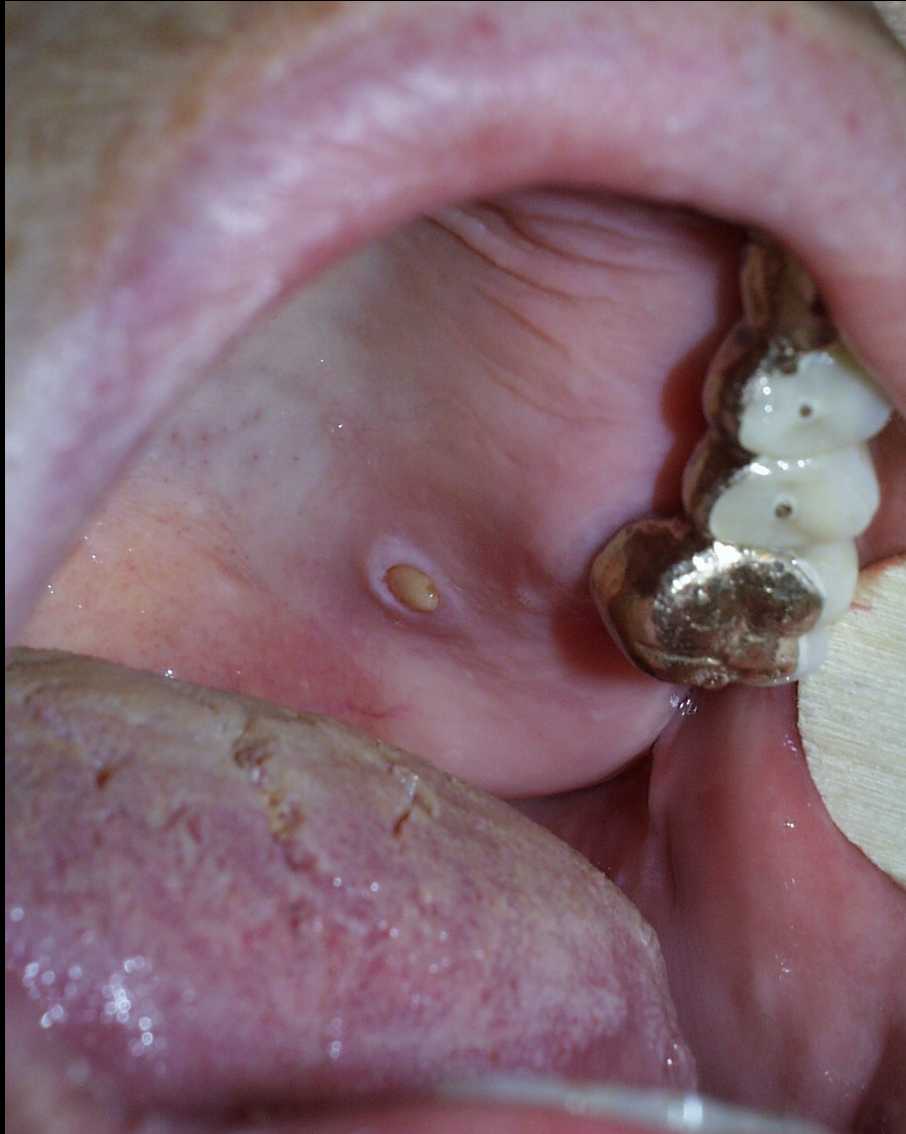




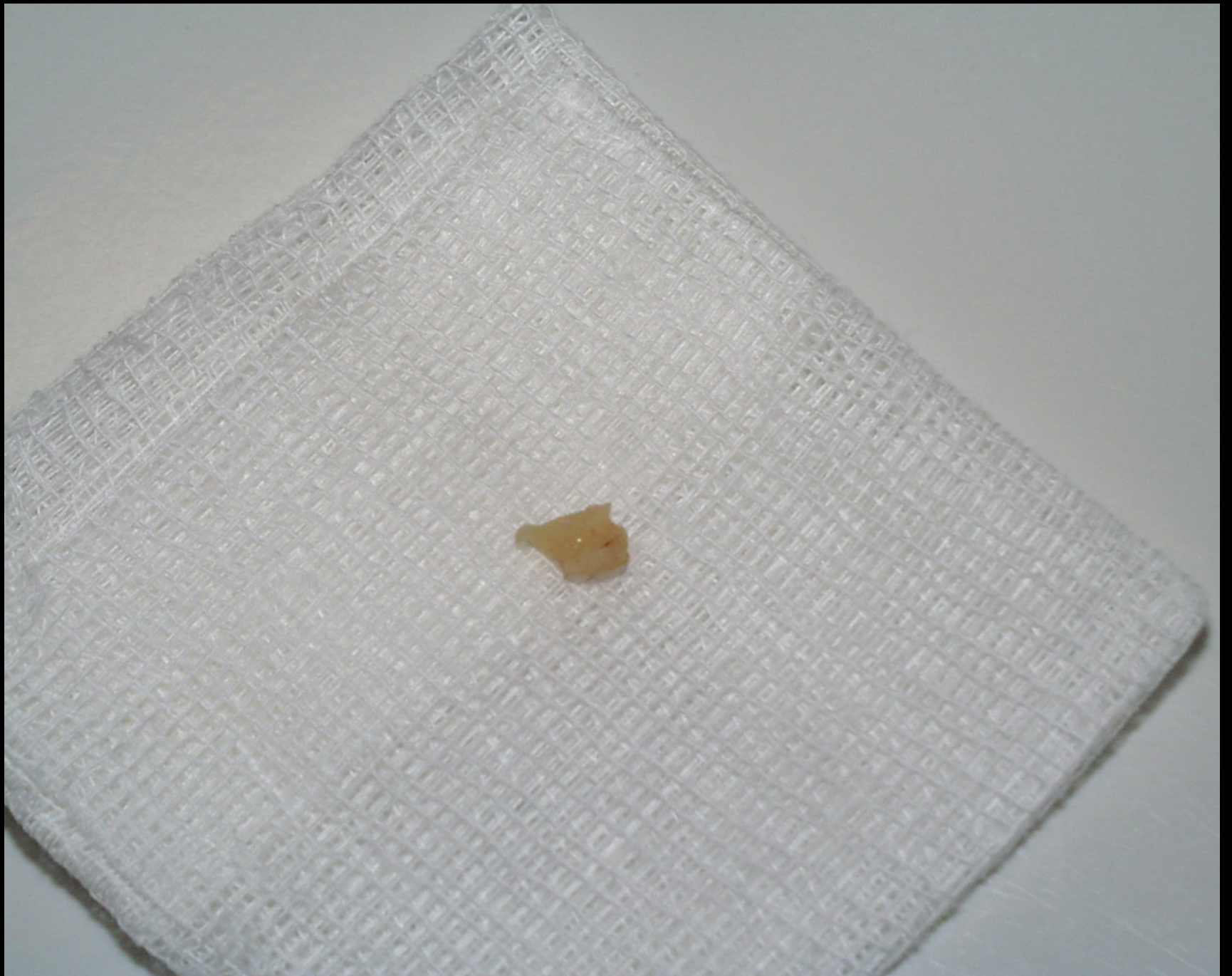




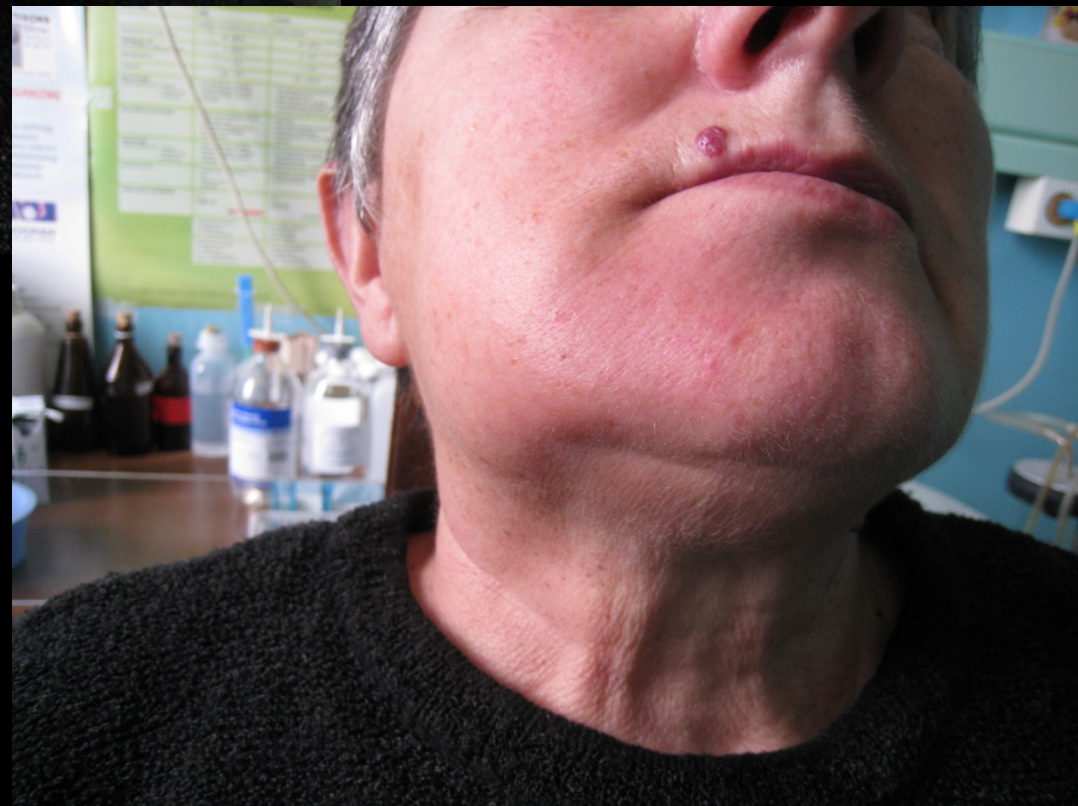
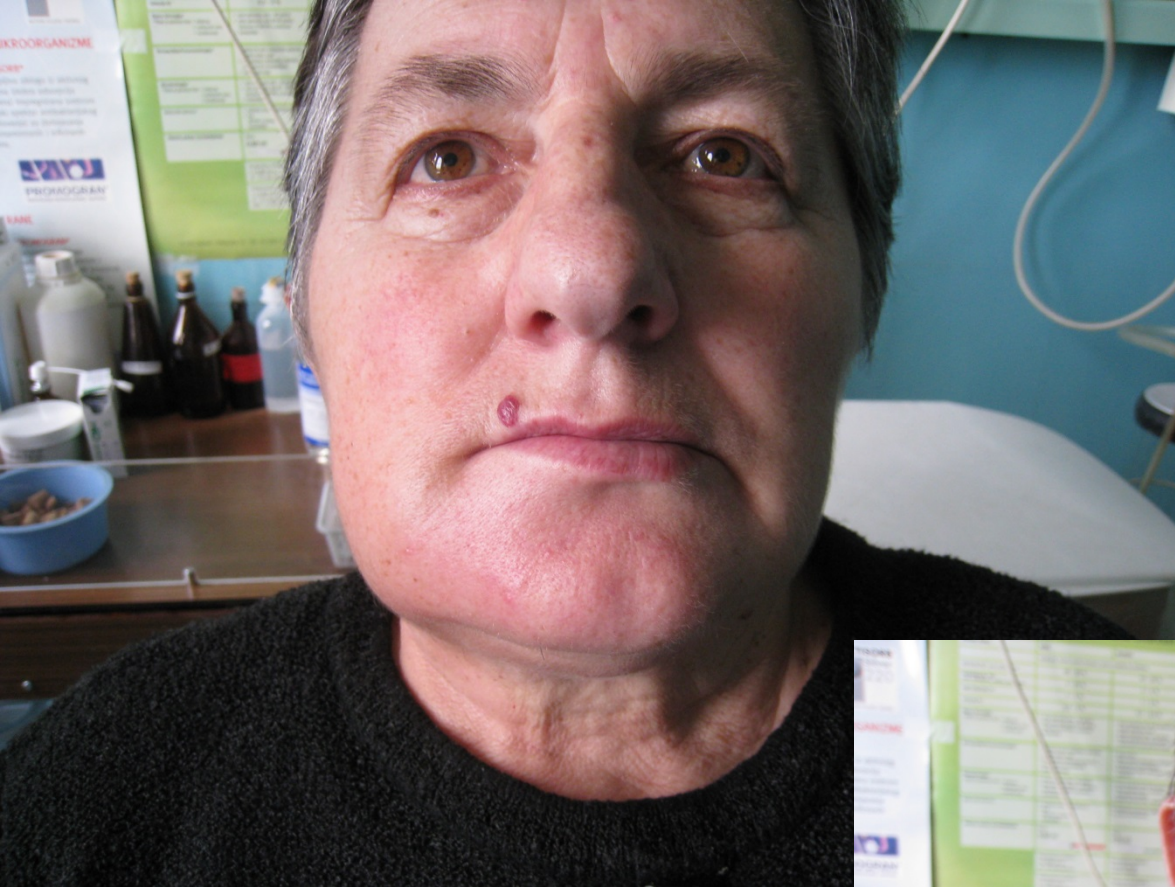









ANDELA AŠPERGER, 1942

(IME I PREZIME, ROĐEN)

(MATIČNI BROJ)

Dijagnoza:

12.2.2008.

Bila hosp. ovdje zbog akutnog edema desno perimandibularno koji je nastao nakon stom. intervencije.

Liječen prednji zub 2-, pri davanju anestezije istog treha nastala utrnutost desnoga mentalisa što bi se moglo objasniti mehaničkom i intra-neuralnom aplikacijom anestetika. Dva ~~sta~~ kasnije nastaje edme desno perimandibularno i edem donje usnice desno do medijalne ligije. Liječena amb. Sinopenom, kortikosteroidima, bez poboljšanja, profilaktički dobivala antibiotike, ovdje hosp. SEM L, DKS, CRP u dva navrata uredni.

Dogovor s dr. Trutin za citološku punkciju pod kontrolom UZV.

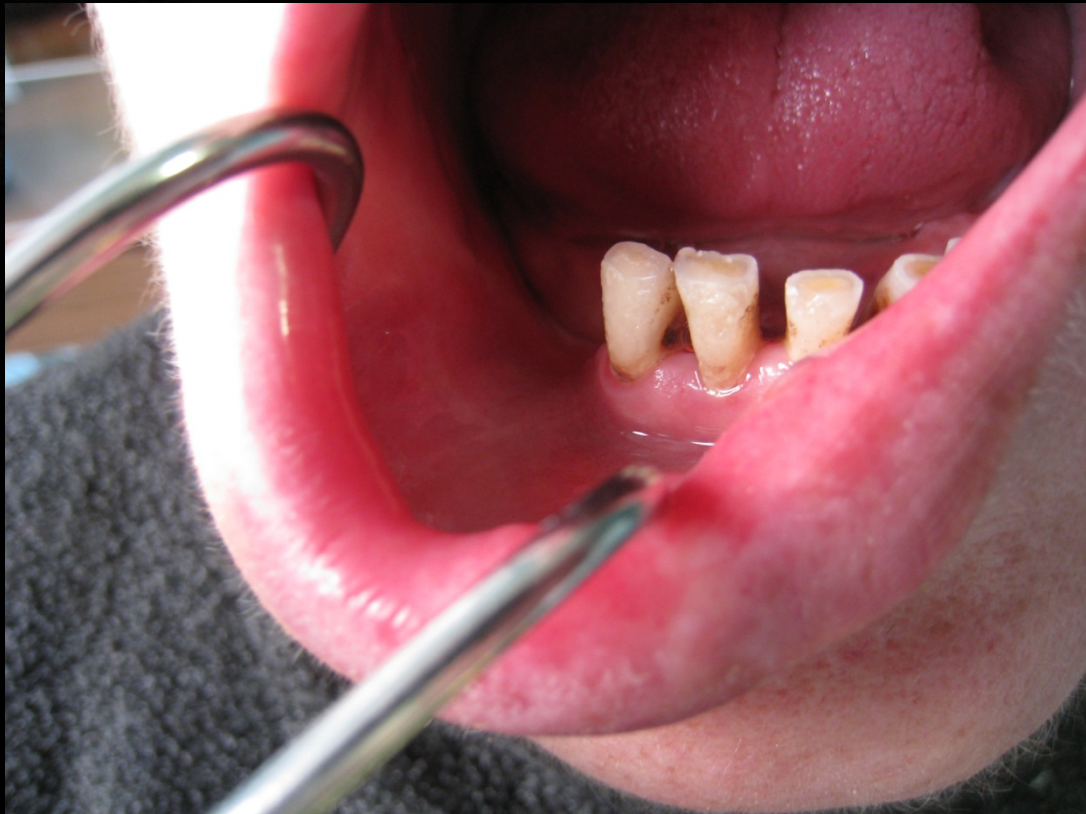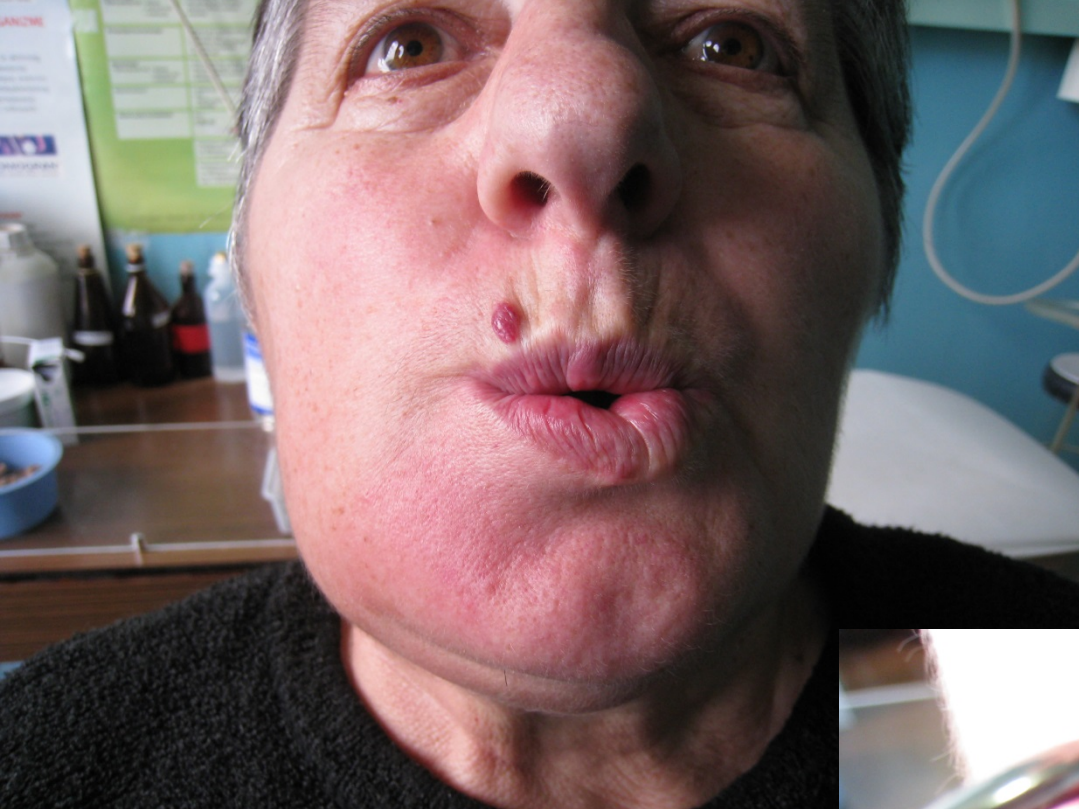Naručena za sutra 13.2.08. u 12 sati u Zavodu za citologiju, prizemno.

Molim: 1. Uputnicu za Nuklearnu medicinu za UZV i 2. uputnicu za Citologiju za cit. punkciju pod kontrolom UZV.

PROF. DR. ĐARKO MACAN  
ORALNI KRUG  
328782

*Macan*







KLINIČKA BOLNICA "DUBRAVA"  
ODJEL ZA NUKLEARNU MEDICINU

Avenija Gojka Šuška 6, 10040 Zagreb, Tel: (01) 29 02 889, Fax: (01) 29 02 719, Voditelj: Doc. dr. Franjo Škreb

Broj protokola: 793x/08  
Prezime i ime: **Ašperger Anđela**  
Upućen od: LOP

Datum: 13. veljače 2008.  
Dob (godine): 66  
JMBG

**Pretraga desne mandibule ultrazvukom**

Edem nad desnim krakom mandibule a na mjestu jače bolnosti u srednjoj trećini , uz krvnu žilu hipoehogeni čvor 0,4x0,3x0,4 cm ( punktirala dr Trutin)

KLINIČKA BOLNICA DUBRAVA

Zagreb, Avenija Gojka Šuška 6

Tel. 2902386

ODJEL ZA KLINIČKU CITOLOGIJU

I CITOMETRIJU

Voditelj: mr. sc. Karmen Trutin Ostović, dr. m

Broj: 1797 / 08      Šalje: Ambulanta  
Ime i prezime: **AŠPERGER ANĐELA**      God. rođenja: 1942  
Dat. uzimanja materijala 13.02.2008      Dat. izdavanja nalaza 18.02.2008  
Klinička dijagnoza  
Vrsta materijala tvorba (UZV)

**CITOLOŠKI NALAZ**

Pod kontrolom UZV punktirana je hipoehogena zona veličine 4x4mm uz mandibulu.  
U razmazima punktata nađene su masne stanice, nešto histiocitarnih stanica,  
elementi masne strome te nešto vakuoliziranih lipoblasta uz oskudno miksoidnog  
matriksa.

DKS: seg 0,48; eo 0,01; bazo 0,01; ly 0,39; reakt. ly 0,03; mono 0,08.

Zaključak: Mezenhimalni tumor (miksoidni liposarkom? lipom?).

Napomena: Preporuča se ekstirpacija tvorbe i PHD.

Mr. sc. Karmen Trutin Ostović, dr. med.

Mr. sc. Karmen Trutin Ostović, dr. med.  
spec. citolog / histični imunolog

KB DUBRAVA  
syngo CT 2006G

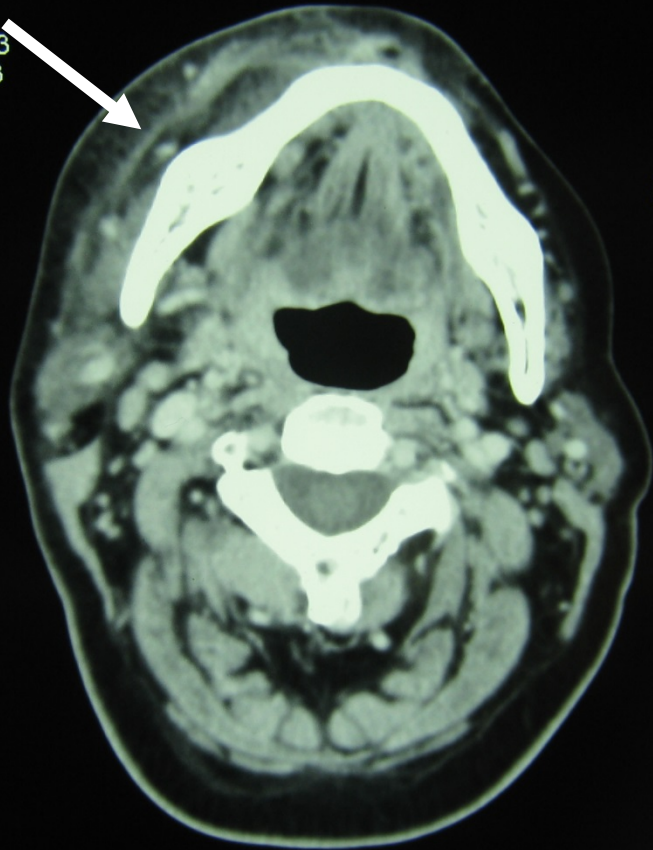ASPERGER, ANGJELA

AFR

C 19  
KB DUBRAVA  
syngo CT 2006G

741/08  
\*1/1/1942, F, 66Y

1/31/2008  
17:27:09.23  
502 IMA 13  
MPR 2



Spin: 35  
Tilt: -91

Spin: 35  
Tilt: -91

RPF

5cm

5cm

F

F

SP H490.8  
W 352 MF 1.06

SP H484.7  
W 352  
C 19

2.08.

U međuvremenu bolnost zuba 7+ i 3,2--1  
na horizontalnu i vertikalnu perkusiju.  
Th: ex 3,2-

Preporučam Augmentin 2x1 i Paracetamol 3x2 a 500  
protiv bolova.  
K/ u petak 22.2.08. oko 12 sati.

*[Handwritten signature]*  
DANILO MARČIĆ  
OPREMLJEN  
2008

Dr. Rožman  
078581



